



THE UNIVERSITY OF TEXAS
**MD Anderson
Cancer Center**

Making Cancer History®

Extranodal Lymphomas: B Cell Lymphomas

Jillian Gunther MD PhD
MD Anderson Cancer Center

 @jillgunther

Disclosure

- No conflicts of interest

Extranodal Lymphoma: B cell Lymphomas

- Describe the clinical behavior of indolent and aggressive histology extranodal B-cell lymphomas and differentiate these from their nodal counterparts.

Extranodal Lymphoma: B cell Lymphomas

- ~25–40% of non-Hodgkin lymphomas arise in extranodal sites
- Can have distinct biology and clinical behavior
- Often associated with site-specific triggers
- Management can differ from nodal disease
- Examples of extranodal sites:
 - GI tract
 - Skin
 - CNS
 - Testis
 - Breast
 - Thyroid

Extranodal Lymphoma: B cell Lymphomas

- ~25–40% of non-Hodgkin lymphomas arise in extranodal sites
- Can have distinct biology and clinical behavior
- Often associated with site-specific triggers
- Management can differ from nodal disease
- Examples of extranodal sites:
 - GI tract - stomach
 - Skin
 - CNS
 - Testis
 - Breast
 - Thyroid

Gastric B cell Lymphoma

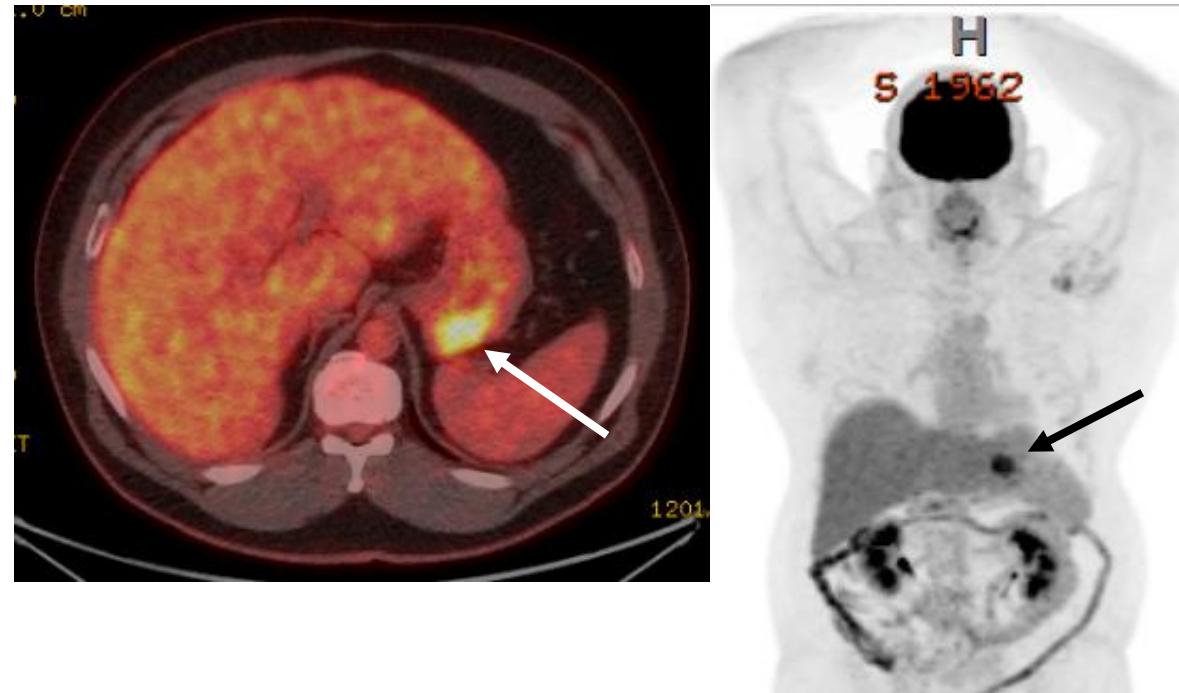Case 1: Gastric B cell Lymphoma

- 60 yo with long history of diarrhea (lymphocytic colitis) and other GI symptoms including reflux
- EGD 2 years prior showed gastritis with negative H. pylori
- EGD shows a large infiltrative non-circumferential non-bleeding mass in the cardia of the stomach
- Pathology: EXTRANODAL MARGINAL ZONE, MUCOSA-ASSOCIATED LYMPHOID TISSUE (MALT LYMPHOMA). H. Pylori negative

Case 1: Gastric B Cell Lymphoma – Low Grade

Workup:

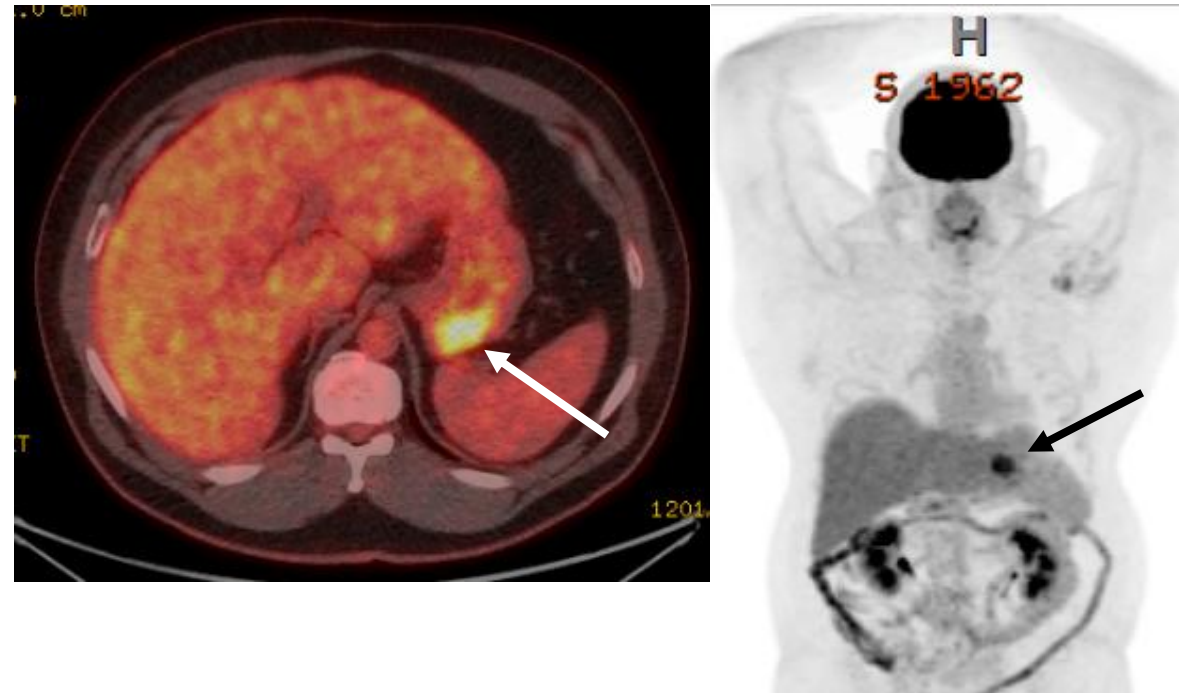
- Bone marrow biopsy negative
- Stool H. pylori test negative
- PETCT:
 - Focus of FDG activity within the cardia of the stomach consistent with MALT lymphoma
 - No evidence of FDG-avid lymphadenopathy. SUV 6.7



Case 1: Gastric B Cell Lymphoma – Low Grade

Workup:

- Bone marrow biopsy negative
- Stool H. pylori test negative
- PETCT:
 - Focus of FDG activity within the cardia of the stomach consistent with MALT lymphoma
 - No evidence of FDG-avid lymphadenopathy. SUV 6.7

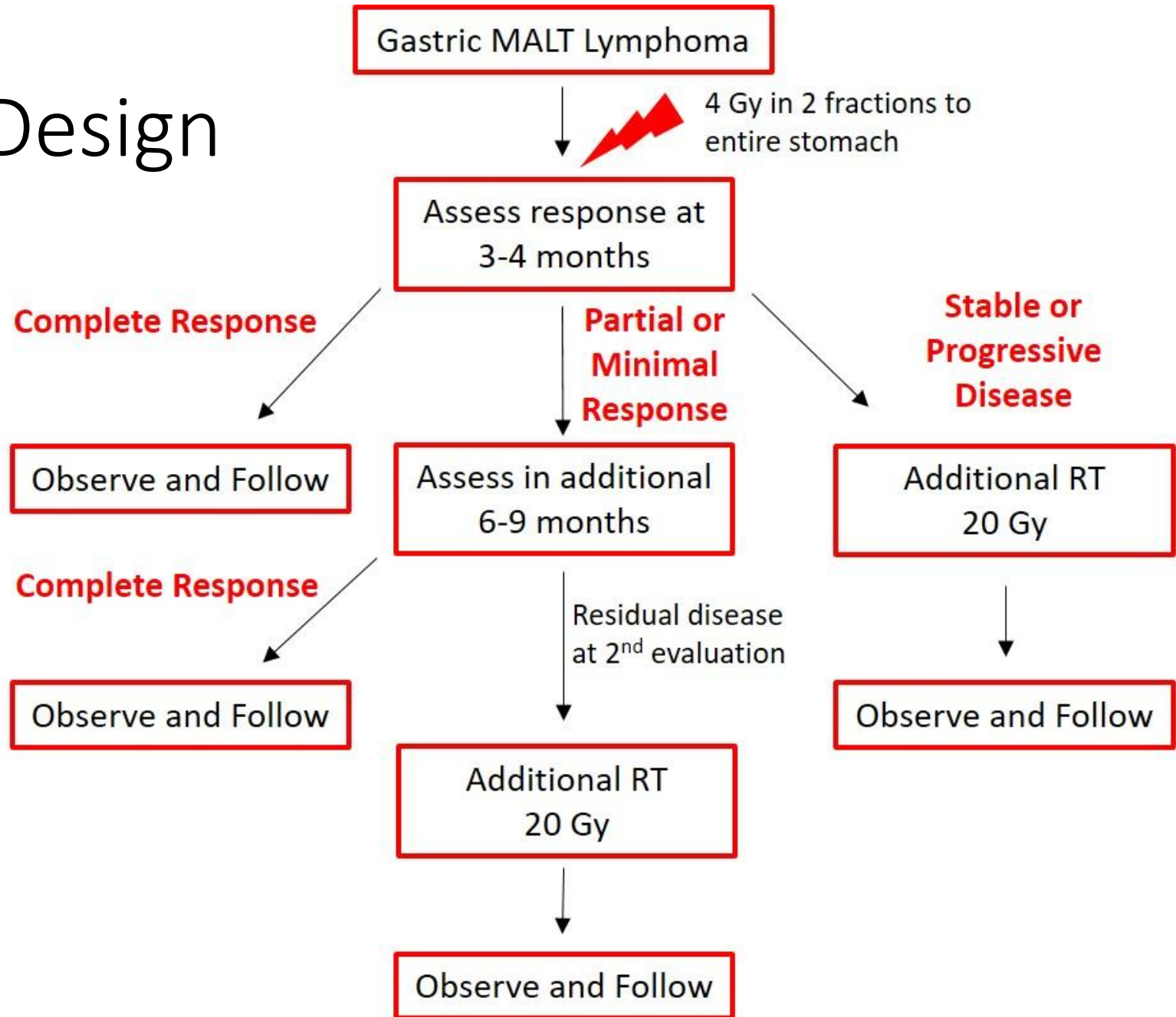


PETCT scan is often completely negative!

Ultra Low Dose 4 Gy Radiation for Definitive Therapy of Gastric MALT Lymphoma

(using a response-adapted approach)

Study Design

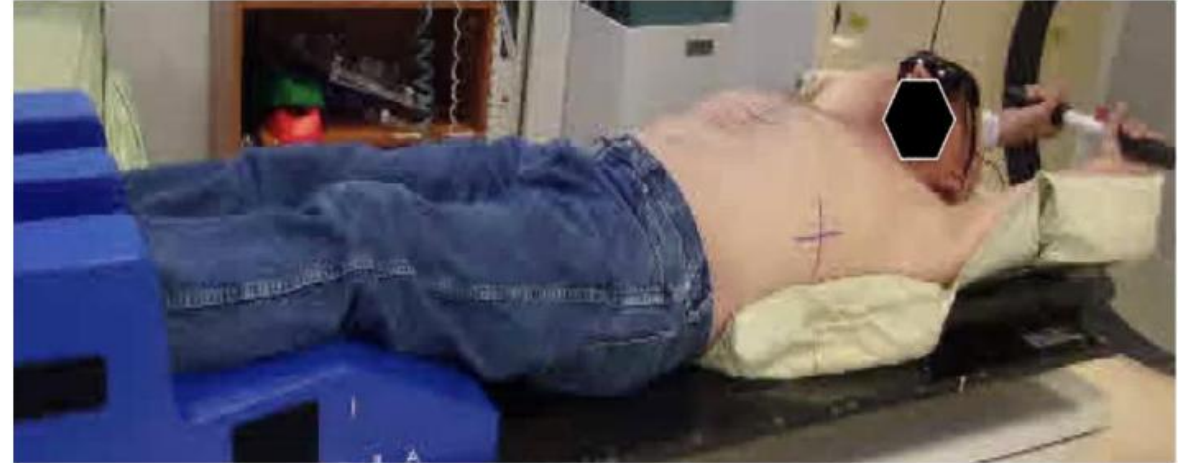

Adapted from
Chelsea Pinnix's
orbital protocol



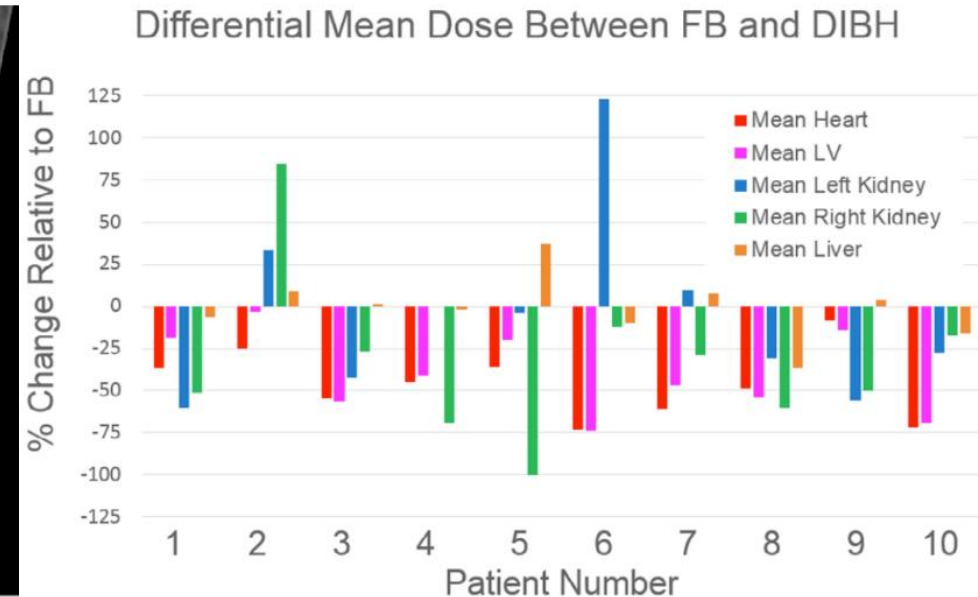
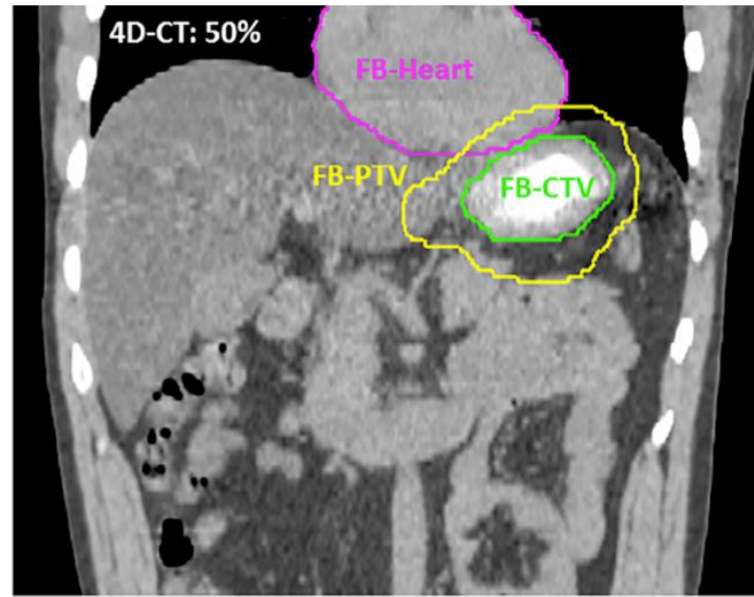
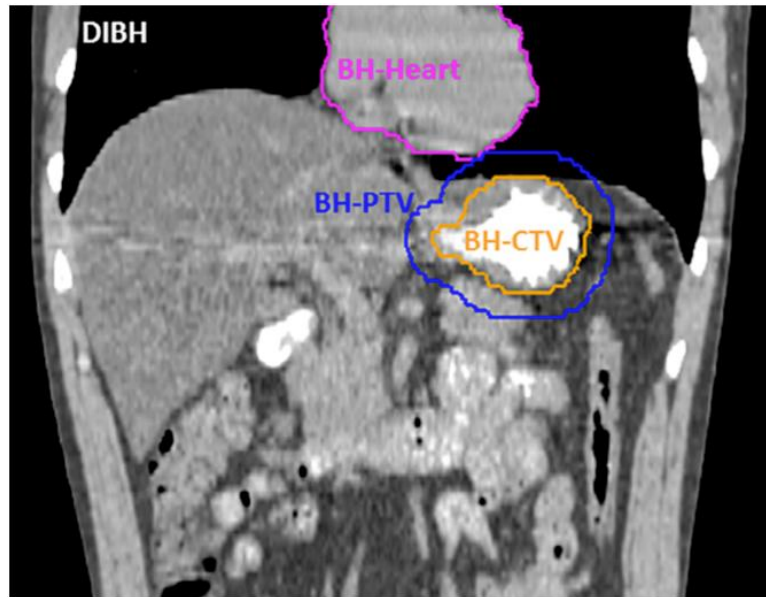
Treatment

- Simulation
 - Arms over head
 - NPO for 6 hrs, prefer overnight
 - Deep Inspiration Breath Hold
- Planning
 - For 4 Gy, 3D conformal RT is used
 - For 20+ Gy, IMRT/VMAT is preferred



DIBH when treating gastric lymphoma

- Compared OAR dosimetry for DIBH vs FB in 10 pts w/ gastric MALT



- DIBH improves cardiac and renal dosimetry without compromising target dose

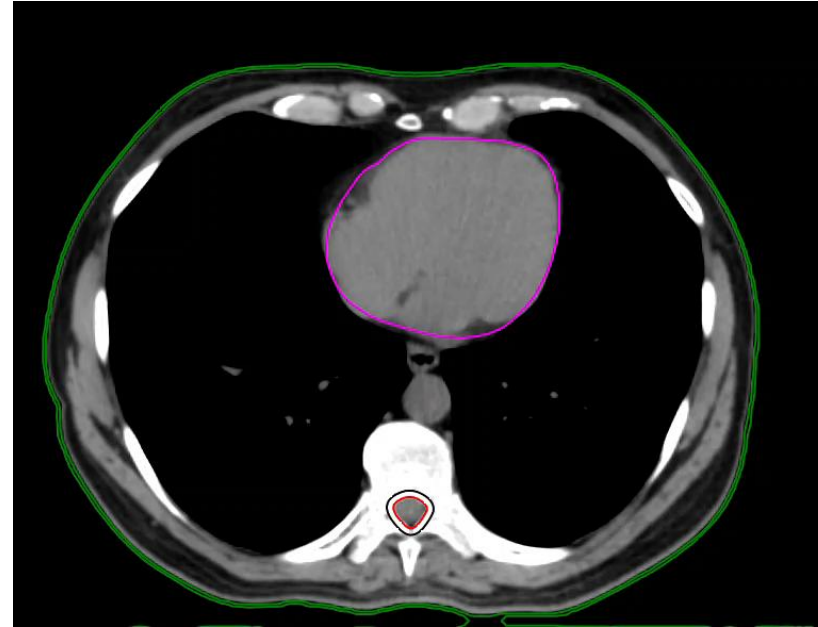
Treatment Planning

Simulation

- Deep inspiration breath hold
- NPO 6 hrs, prefer overnight

- 3D conformal RT

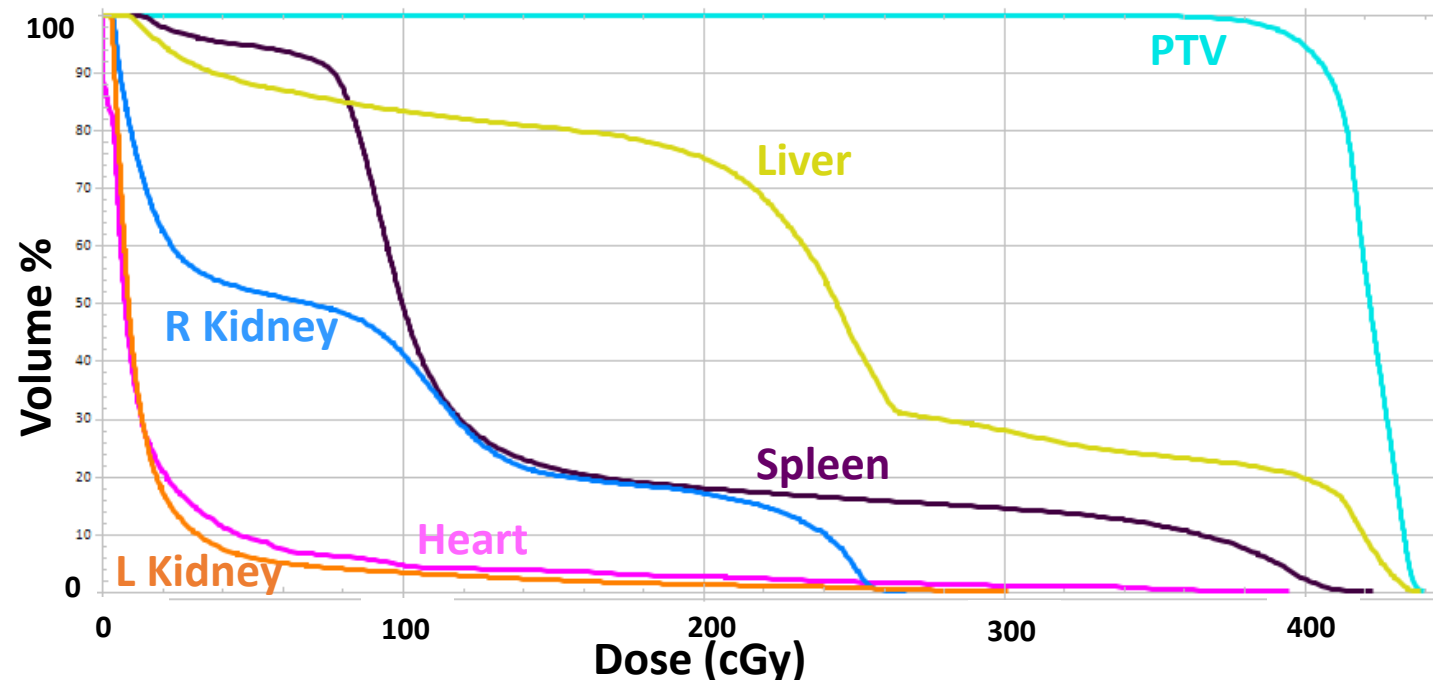
3D conformal RT plan



Mean Organ Dose

ROI	Dose [cGy] Average
Heart	23
Kidney_L	18
Kidney_R	87
Liver	245
PTV_stomach	421
Spleen	142

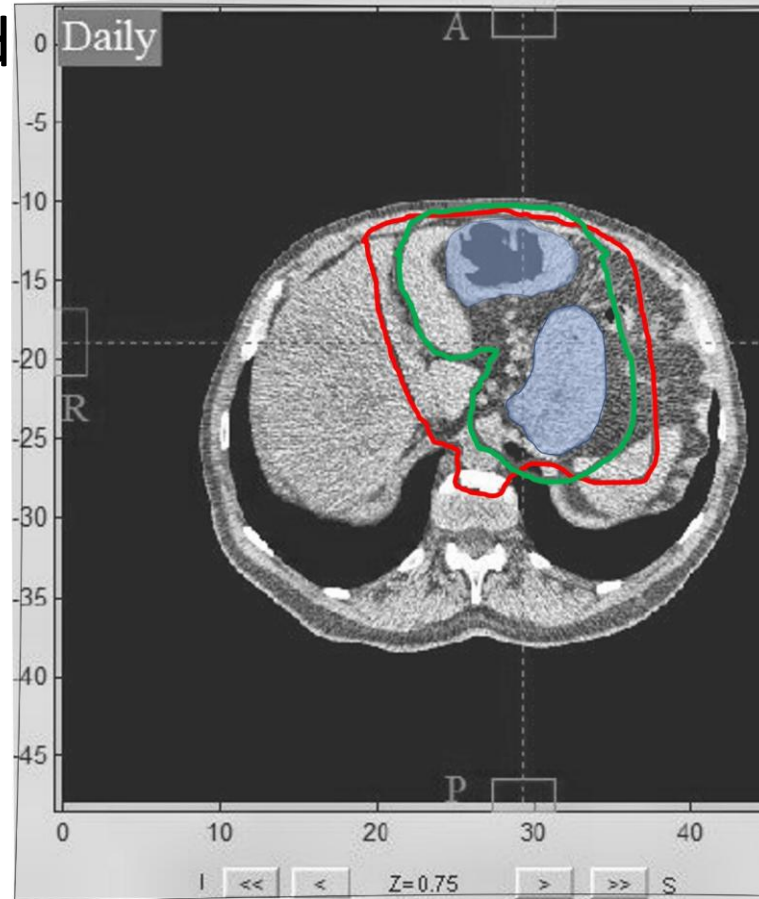
Dose Volume Histogram



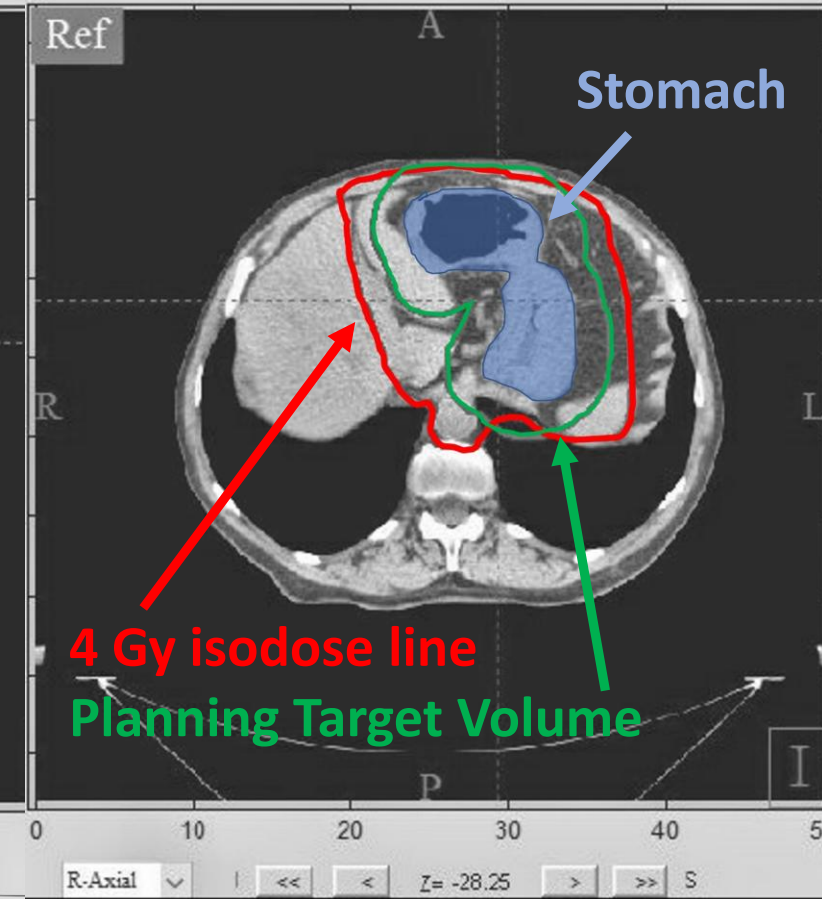
Treatment Delivery

- Deep inspiration breath hold
- NPO 6 hrs, prefer overnight
- 3D conformal RT
- Pre-medicated with zofran
- CT-based image guidance
- Reviewed prior to 1st fraction and for any questions on 2nd fraction

Daily CT Reviewed Before Treatment



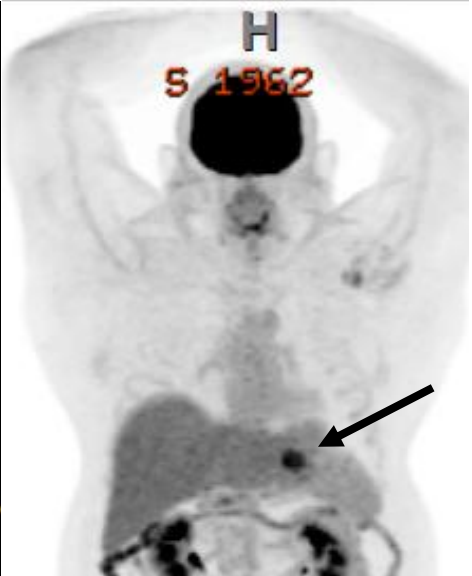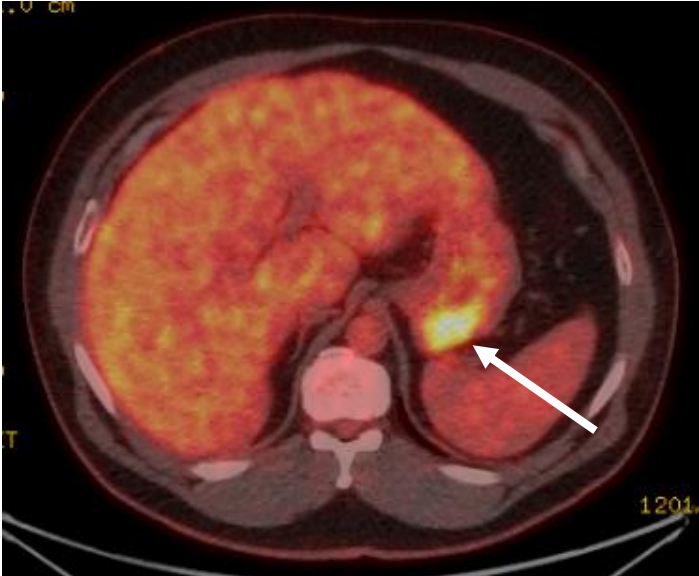Simulation CT with RT Plan



Post-treatment Evaluation

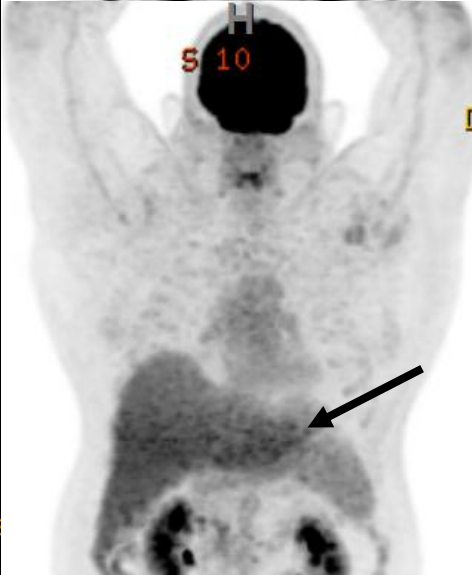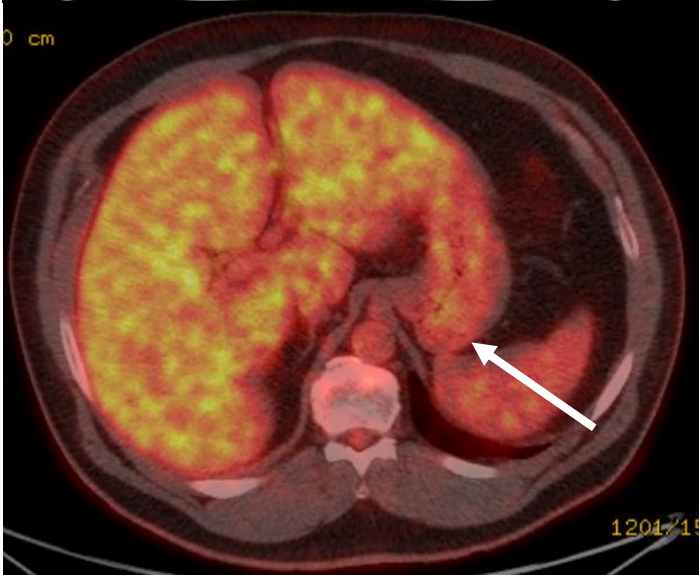
- 3-4 months post treatment, patients repeat
 - Clinical exam with labs
 - Imaging
 - Endoscopy with biopsies
 - 12-16 biopsies covering all areas of stomach recommended

PETCT-based Response Assessment



Pre-treatment

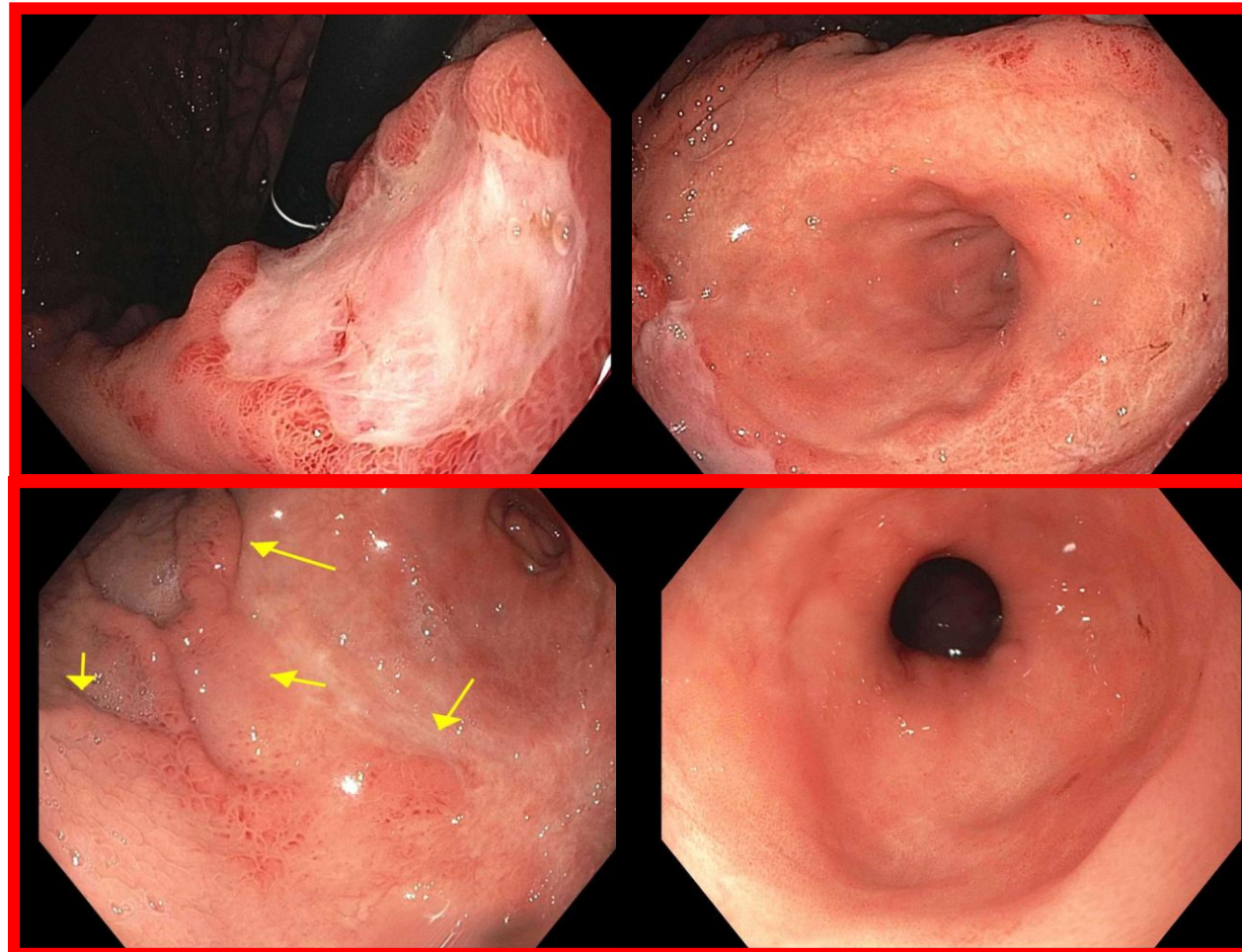
Axial and MIP PETCT images confirm an FDG-avid gastric mass



Post-treatment with 4 Gy RT

Complete metabolic response to treatment

Endoscopy-based Response Assessment



Pre-treatment

4 ulcers in the gastric body and antrum, largest 2-4cm

Post-treatment CR with 4 Gy RT

Thick gastric folds with healing scars in the gastric body.

Need thorough assessment of entire stomach on repeat endoscopy!

After 4 Gy, pathology negative for lymphoma

Diagnosis

- A. STOMACH, 10-12 MM SUB-EPITHELIAL LESION GREATER CURVATURE, BIOPSY:
Oxyntic mucosa with mild chronic inactive gastritis.
No *Helicobacter pylori* (H&E stain) or tumor, including lymphoma, identified.
No submucosa is present in the submitted biopsy.
- B. STOMACH, 8 MM PRE-PYLORIC POLYP IN ANTRUM, BIOPSY:
Antral mucosa with chronic inactive gastritis and hyperplastic polyp.
No *Helicobacter pylori* (H&E stain) or lymphoma identified.
- C. STOMACH, 5 MM ANTRUM POLYP, BIOPSY:
Antral mucosa with focal erosion and inactive chronic nephritis.
No *Helicobacter pylori* (H&E stain) or lymphoma identified.
- D. STOMACH, CARDIA RANDOM BIOPSY:
Oxyntic mucosa with changes of proton pump inhibitor effect.
No *Helicobacter pylori* (H&E stain) or lymphoma identified.
- E. STOMACH, SCAR GASTRIC FUNDUS, BIOPSY:
Oxyntic mucosa with mucosal scar, chronic gastritis, lymphoid infiltrate, and changes suggestive of proton pump inhibitor effect. See comment.
No *Helicobacter pylori* (H&E stain) or lymphoma identified.
- F. STOMACH, RANDOM GASTRIC BODY, BIOPSY:
Oxyntic mucosa with chronic gastritis and changes suggestive of proton pump inhibitor effect.
No *Helicobacter pylori* (H&E stain) or lymphoma identified.
- G. GASTROESOPHAGEAL JUNCTION, IRREGULAR Z LINE @ 41 CM BIOPSY:
Cardio-oxyntic mucosa with mild chronic inflammation.
Adjoining squamous epithelium with rare eosinophils and changes of reflux esophagitis.
No *Helicobacter pylori* (H&E stain) or intestinal metaplasia identified.

Comment

The biopsy from scar gastric fundus (part E) has a lymphoid infiltrate. The lymphoid infiltrate is composed predominately of T cells (positive for CD3 by immunohistochemistry) and a few intermixed B cells (positive for PAX5). There is no light chain restriction by immunohistochemistry for kappa and lambda light chains. No lymphoma is identified.

After 4 Gy, pathology negative for lymphoma

Diagnosis

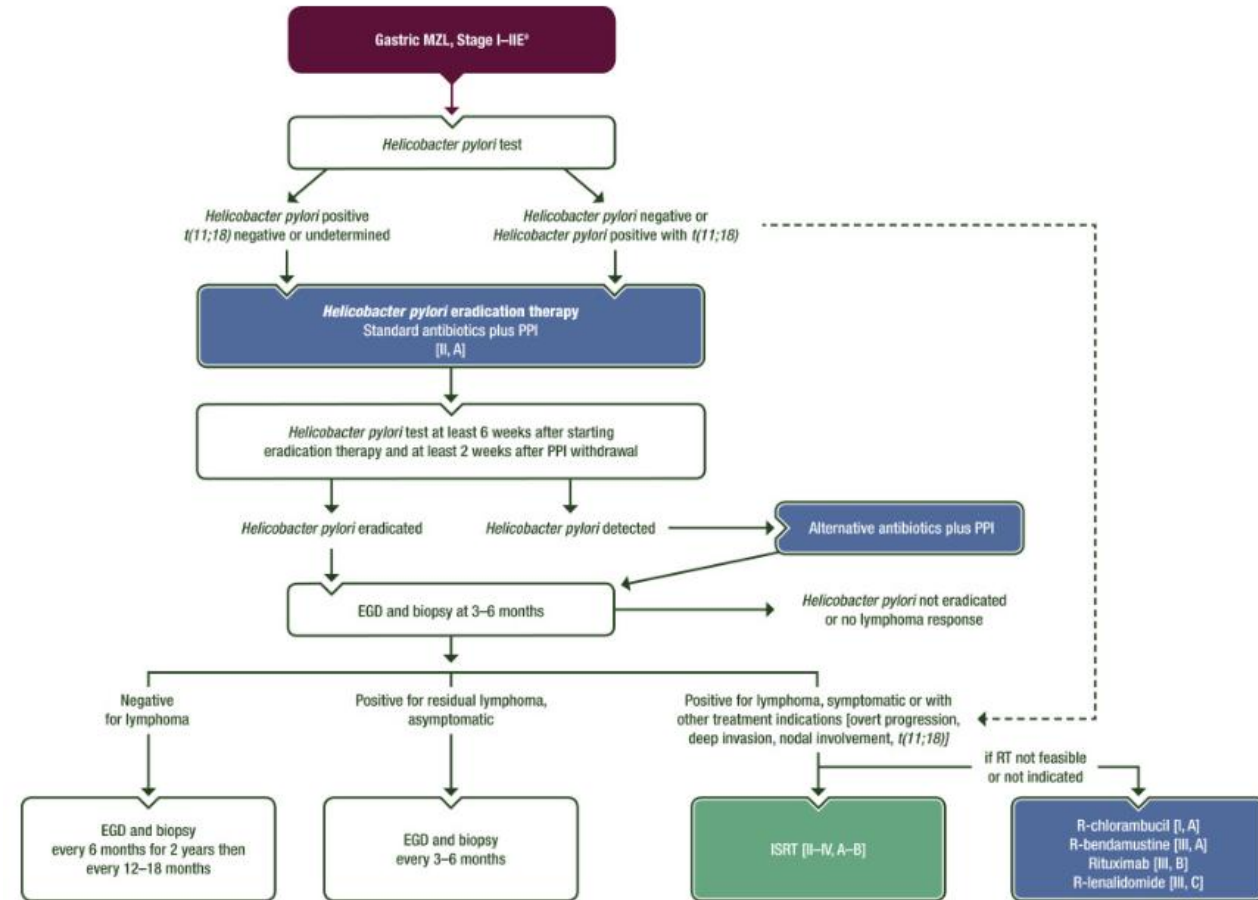
- A. STOMACH, 10-12 MM SUB-EPITHELIAL LESION GREATER CURVATURE, BIOPSY:
Oxyntic mucosa with mild chronic inactive gastritis.
No *Helicobacter pylori* (H&E stain) or tumor, including lymphoma, identified.
No submucosa is present in the submitted biopsy.
- B. STOMACH, 8 MM PRE-PYLORIC POLYP IN ANTRUM, BIOPSY:
Antral mucosa with chronic inactive gastritis and hyperplastic polyp.
No *Helicobacter pylori* (H&E stain) or lymphoma identified.
- C. STOMACH, 5 MM ANTRUM POLYP, BIOPSY:
Antral mucosa with focal erosion and inactive chronic nephritis.
No *Helicobacter pylori* (H&E stain) or lymphoma identified.
- D. STOMACH, CARDIA RANDOM BIOPSY:
Oxyntic mucosa with changes of proton pump inhibitor effect.
No *Helicobacter pylori* (H&E stain) or lymphoma identified.
- E. STOMACH, SCAR GASTRIC FUNDUS, BIOPSY:
Oxyntic mucosa with mucosal scar, chronic gastritis, lymphoid infiltrate, and changes suggestive of proton pump inhibitor effect. See comment.
No *Helicobacter pylori* (H&E stain) or lymphoma identified.
- F. STOMACH, RANDOM GASTRIC BODY, BIOPSY:
Oxyntic mucosa with chronic gastritis and changes suggestive of proton pump inhibitor effect.
No *Helicobacter pylori* (H&E stain) or lymphoma identified.
- G. GASTROESOPHAGEAL JUNCTION, IRREGULAR Z LINE @ 41 CM BIOPSY:
Cardio-oxyntic mucosa with mild chronic inflammation.
Adjoining squamous epithelium with rare eosinophils and changes of reflux esophagitis.
No *Helicobacter pylori* (H&E stain) or intestinal metaplasia identified.

Comment

The biopsy from scar gastric fundus (part E) has a lymphoid infiltrate. The lymphoid infiltrate is composed predominately of T cells (positive for CD3 by immunohistochemistry) and a few intermixed B cells (positive for PAX5). There is no light chain restriction by immunohistochemistry for kappa and lambda light chains. No lymphoma is identified.

Follow up

- If persistent disease at first f/u, repeat endoscopy in 6-9 months
- If CR, repeat endoscopies and imaging per provider
 - Loosely follow the ESMO guidelines for surveillance after H pylori eradication therapy
 - Modified for elderly patients with comorbidities

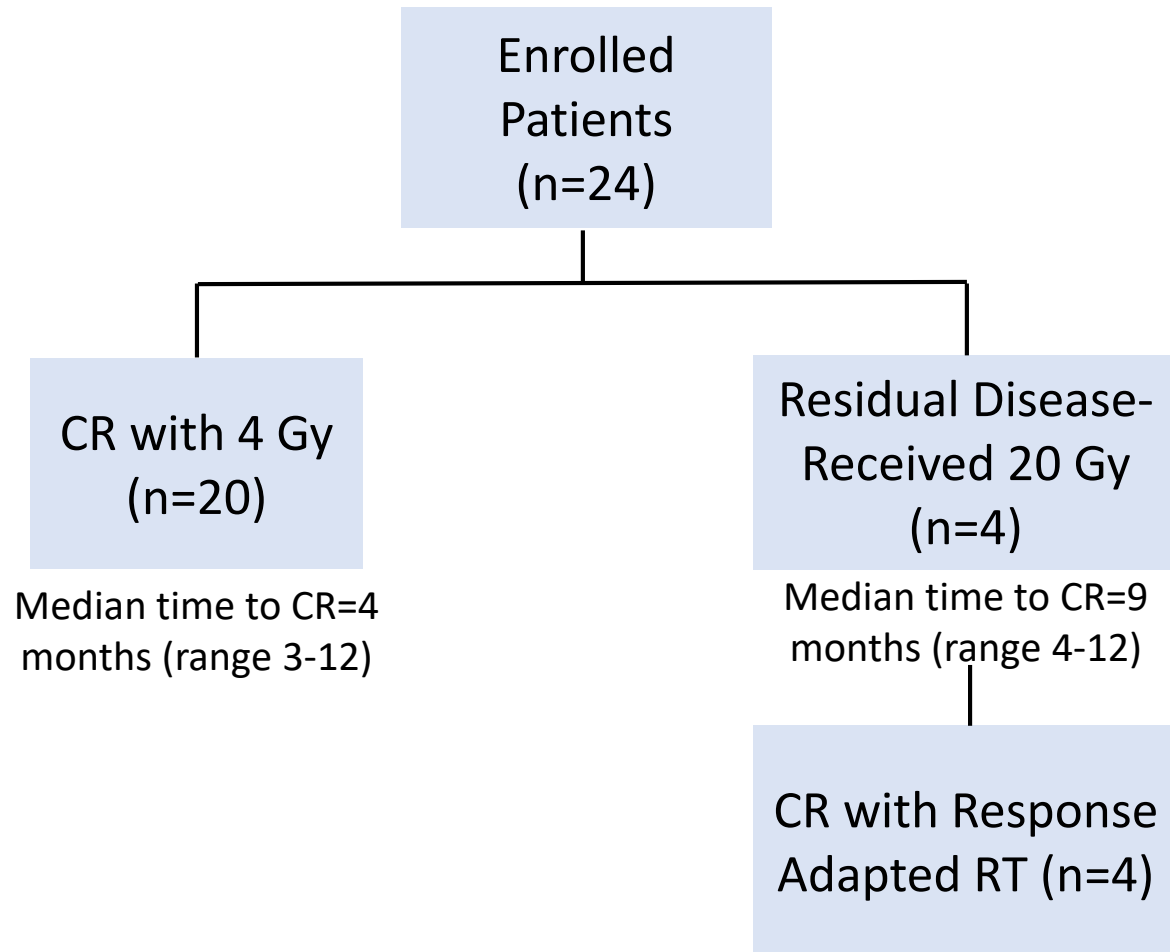


Results

Median follow up of 36 months

Primary Endpoint

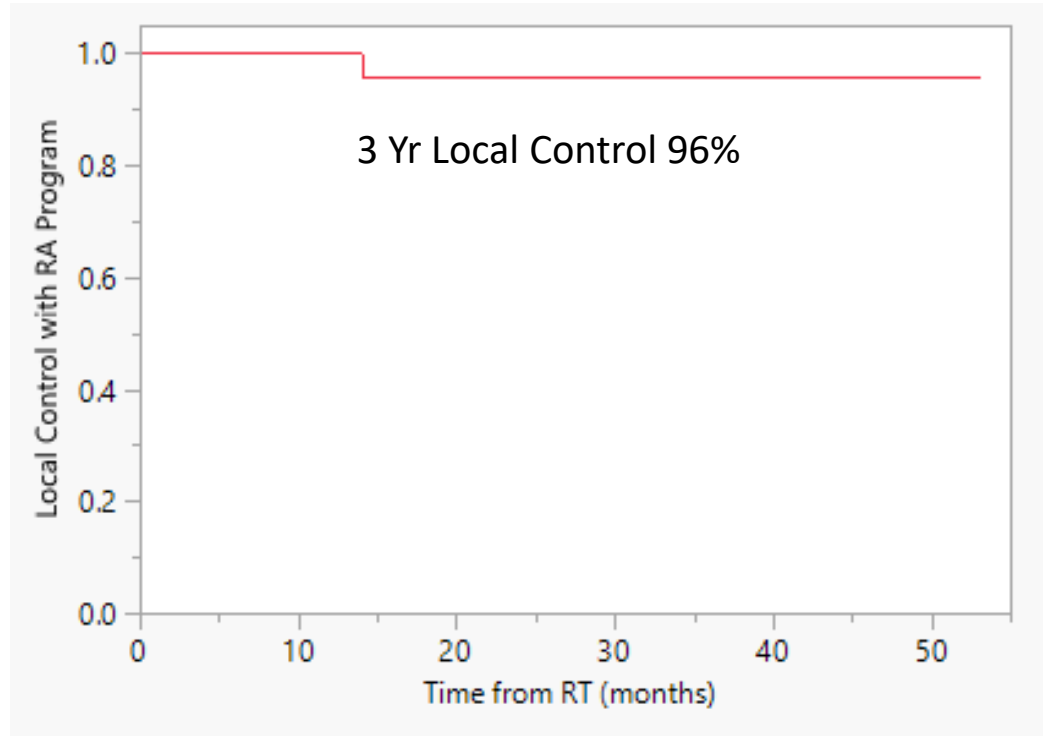
- 83% of patients (n=20) experienced a CR to 4 Gy at one year
- 4 patients received additional 20 Gy
 - 2 for stable disease at 3-4 months
 - 2 for persistent disease at 10-12 months
 - All experienced CR with additional 20 Gy



All patients experienced CR after the response-adapted program.

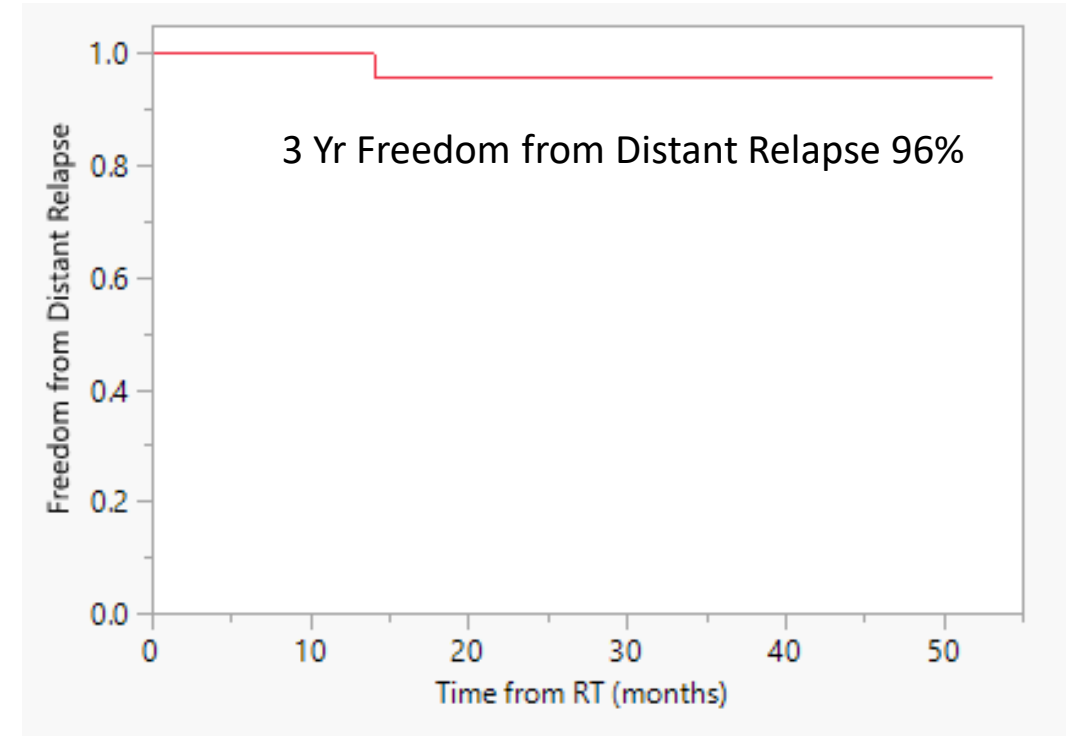
Outcomes

Local Control with Response Adapted Program



- 1 local failure at 14 months after an initial CR with 4 Gy RT
- Salvaged with 20 Gy and experienced CR

Freedom from Distant Relapse



- 1 distant relapse in a patient with Stage IV disease (CR to 4 Gy previously documented)
 - Transformation to DLBCL, now in CR s/p systemic therapy

All patients are now in CR after a total dose of 24 Gy.



PRINCIPLES OF RADIATION THERAPY^a

General Dose Guidelines:

- **Definitive RT (1.5–2.0 Gy daily fractions)**

- ▶ **FL: 24–30 Gy^{19,20}**

- ▶ **Marginal zone lymphoma (MZL)^b:**

- ◊ **Conventional: 24 Gy (local control >95%)^{21,22}**

- ◊ **Dose-adapted: 4 Gy initially (local control 60%–80%); 20–24 Gy sequentially for poor response or relapsed disease. Preferred for orbital MZL to reduce risk of xerophthalmia; supported by prospective studies.^{23,24,c} Strongly consider for parotid MZL to reduce risk of long-term xerostomia. Can be considered for other sites, depending upon patient preference, site-dependent risks of RT, patient age, and compliance with follow-up. Closer monitoring required given higher risk of local failure.**

Response-Adapted 4 Gy is an option!!

Lung

Advances in Radiation Oncology (2024) 9, 101648

advances
in radiation oncology

www.advancesradonc.org

Research Letter

Ultra–Low-Dose Radiation for Extranodal Marginal Zone Lymphoma of the Lung

Susan Y. Wu, MD,^{a,1} Penny Q. Fang, MD, MBA,^{a,1} Ahmed Fetooh, MBBS,^b
Gohar S. Manzar, MD, PhD,^a Kelsey L. Corrigan, MD, MPH,^a
Benjamin R. Schrank, MD, PhD,^a Lewis Nasr, MD, MS,^c Dai Chihara, MD, PhD,^b
Luis E. Malpica Castillo, MD,^b Ranjit Nair, MD,^b Raphael E. Steiner, MD,^b
Preetesh Jain, MBBS, MD, DM, PhD,^b Sattva S. Neelapu, MD,^b Paolo Strati, MD,^b
Loretta J. Nastoupil, MD,^b Bouthaina S. Dabaja, MD,^a
Chelsea C. Pinnix, MD, PhD,^a and Jillian R. Gunther, MD, PhD^{a,*}

^aDepartment of Radiation Oncology, University of Texas MD Anderson Cancer Center, Houston, Texas; ^bDepartment of Lymphoma & Myeloma, University of Texas MD Anderson Cancer Center, Houston, Texas; and ^cDepartment of Leukemia, University of Texas MD Anderson Cancer Center, Houston, Texas

- 20 patients treated with 4 Gy
- Median follow up 17 months
- 100% local control
- No patients with early stage disease had distant progression
- No significant toxicities noted

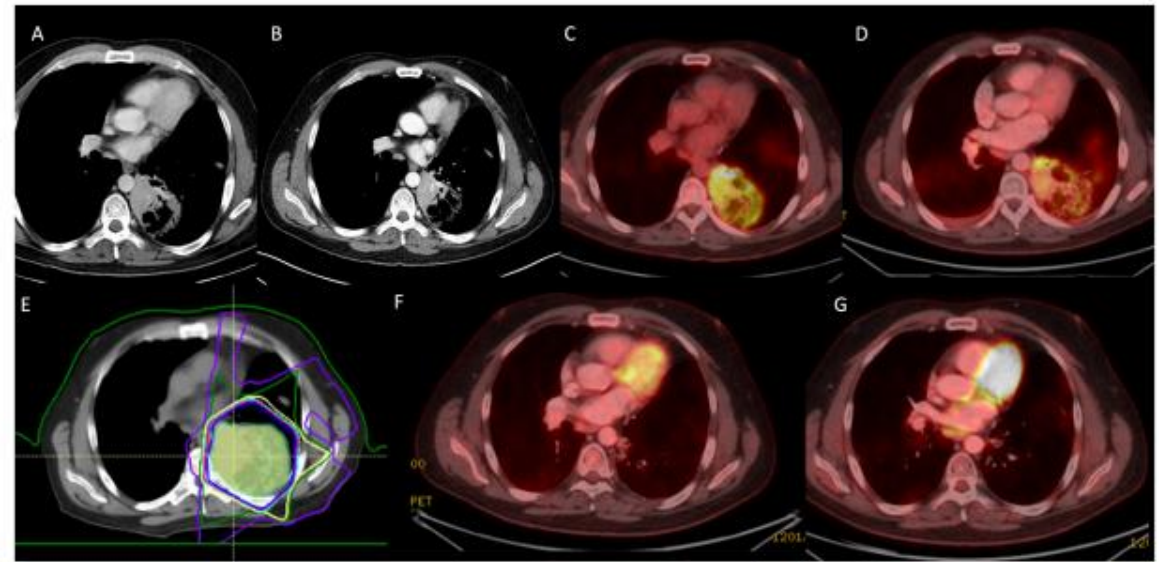


Figure 1 A 47-year-old man with a history of recurrent lung infections refractory to antibiotics and biopsy-proven lung mucosa-associated lymphoid tissue lymphoma (A) prior to therapy, (B) after weekly rituximab \times 4 with improvement, (C) subsequent progression on positron emission tomography (PET)/computed tomography (CT), (D) with slight improvement following a 3-month trial of zanubrutinib, which was discontinued due to hemoptysis. He had a biopsy redemonstrating mucosa-associated lymphoid tissue lymphoma prior to (E) ultra–low-dose radiation therapy, 4 Gy in 2 fractions, with (F) a complete metabolic response on PET/CT 2 months later with a Deauville score of 2, and (G) ongoing response 26 months following radiation.



PMID: 39524525

Susan Wu

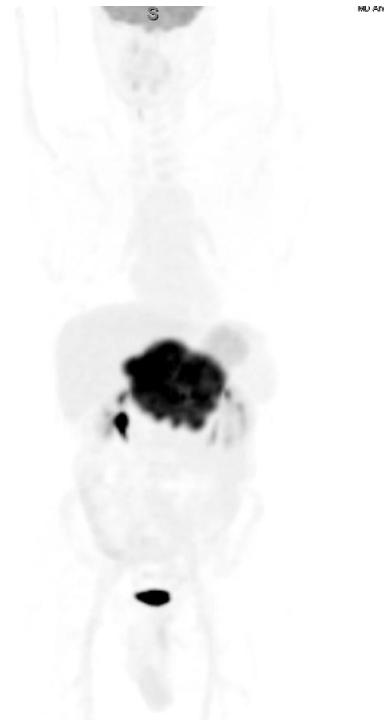
Case 2: Gastric B Cell Lymphoma – High Grade

- Patient reported 2-3 week history of constant dull, aching epigastric pain and fullness
- **CT CAP:** Masslike wall thickening in distal stomach with soft tissue nodularity extending beyond the anterior gastric wall serosa. Concerning for gastric malignancy.
- **EGD:** Mass in the antrum and posterior wall of the stomach body
- **Stomach biopsy:** Diffuse large B cell lymphoma, non germinal center type. Ki67: nearly 100%

Gastric DLBCL

PETCT

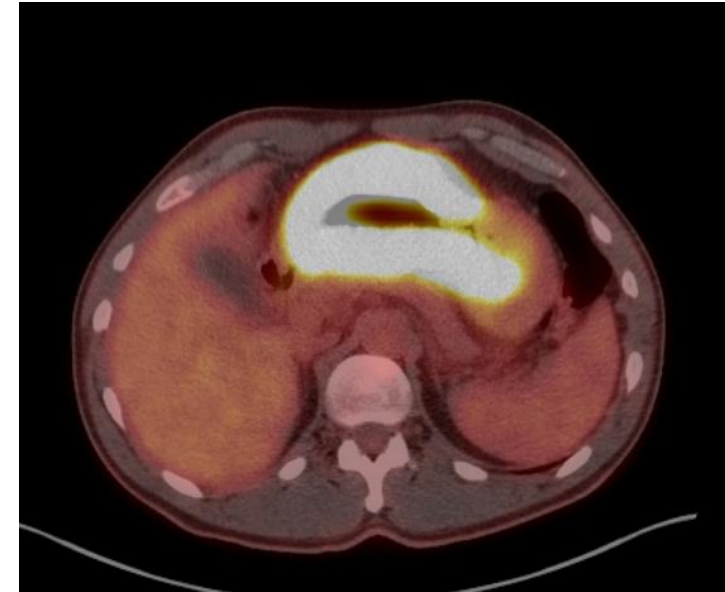
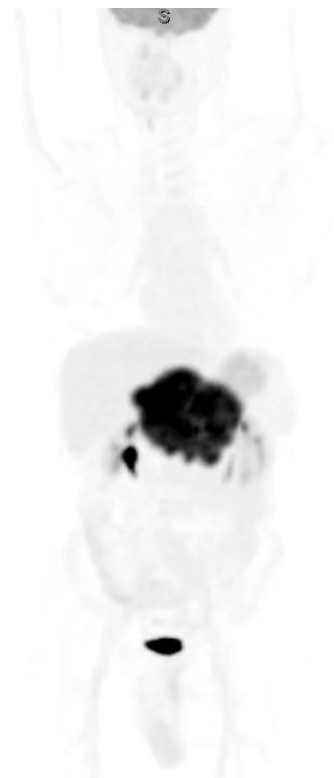
- Prominent hypermetabolic wall thickening of the distal stomach compatible with lymphoma. Max SUV 27.
- No suspicious PET findings outside of the abdomen.



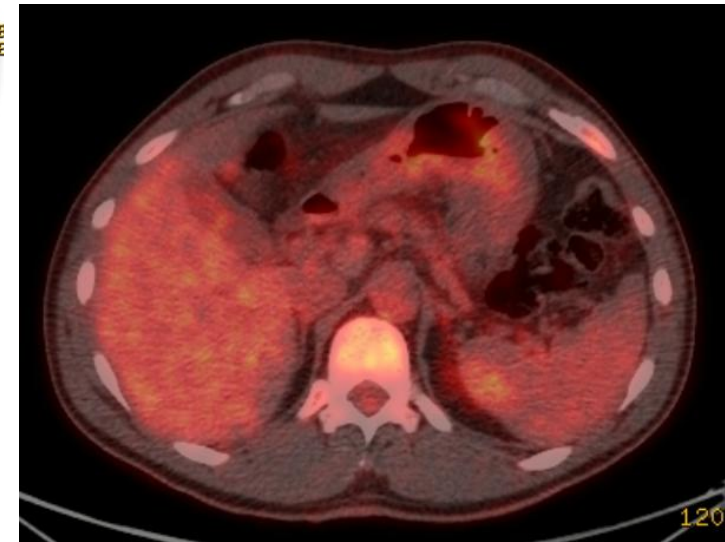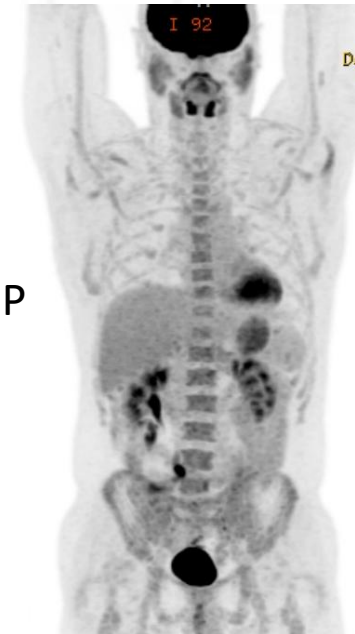Gastric DLBCL

- Received 4 cycles of pola-RCHP
- Complete metabolic response after 2 cycles

Initial



Post-polaRCHP



Gastric DLBCL – benefit of RT?

- Even for non bulky patients, consolidation RT provides benefit
 - 10-year LRFS: 100% with RT and 81.4% without RT ($p = 0.028$)
 - PMID: 26193661
- Stomach directed-RT may mitigate relapse risk associated with incomplete disease response or bulky disease
 - PMID: 39324011

Penny Fang

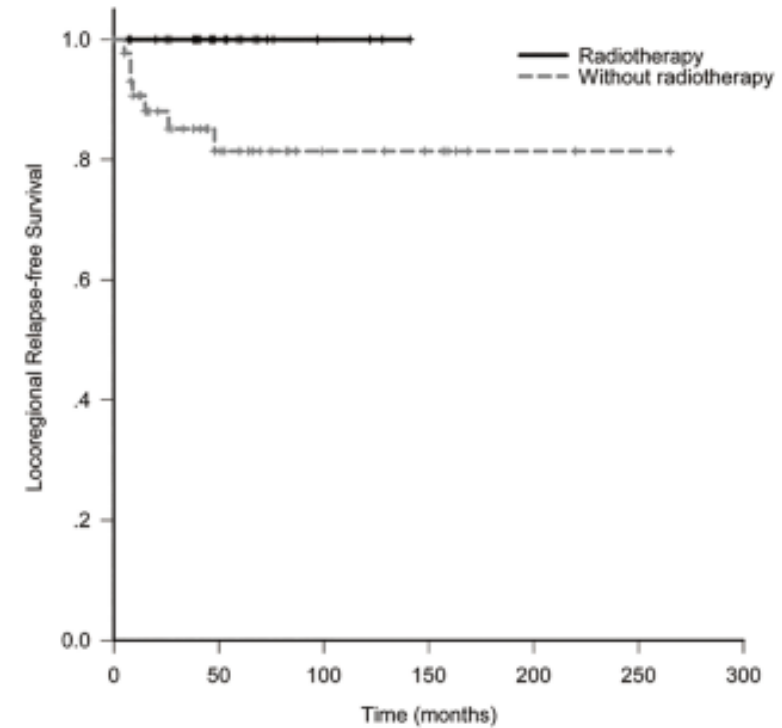
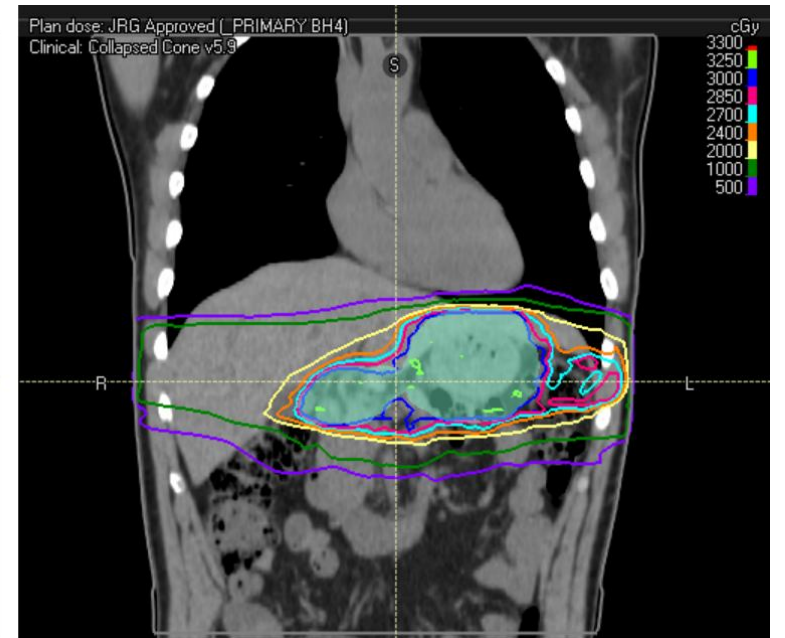
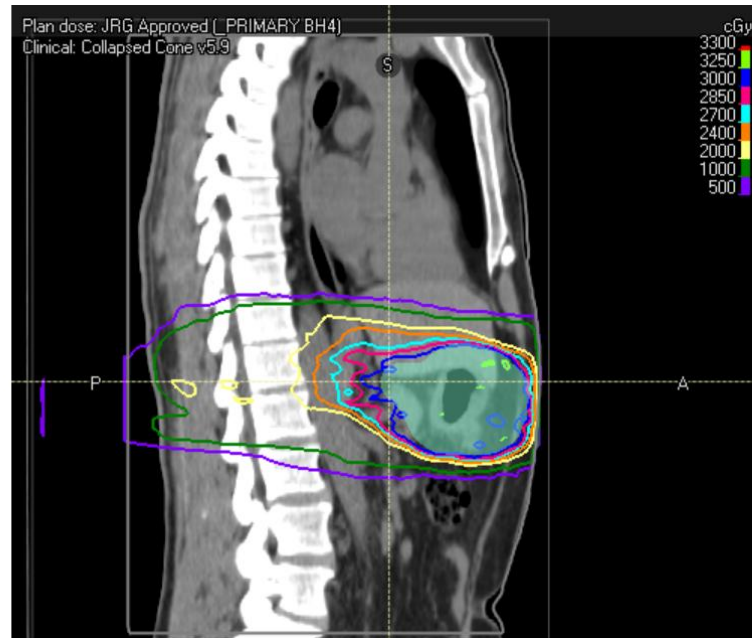
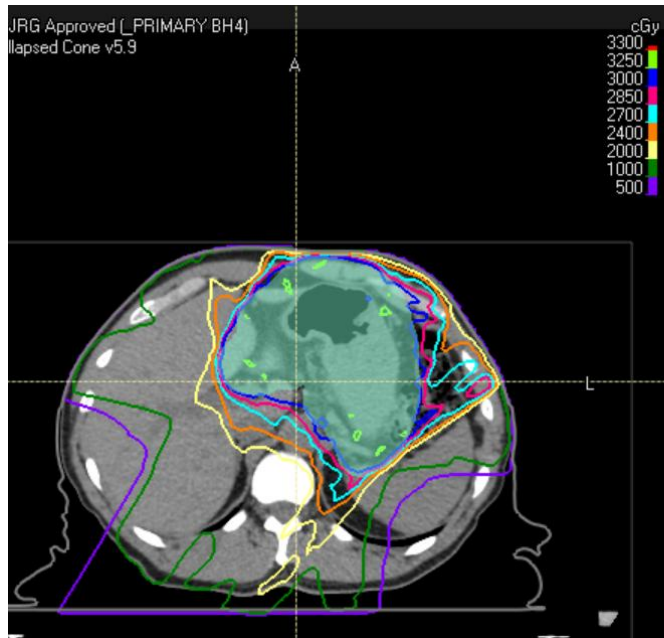


Fig 1. Locoregional relapse-free survival of patients with or without radiotherapy.

PMID: 26193661

Gastric DLBCL

ISRT with 30 Gy in 15 fractions



Gastric DLBCL

ROI Name	Vol. (cc)	Mean (cGy)	D0.03cc (cGy)	D0.1cc (cGy)	D1cc (cGy)	D70 (cGy)	D50 (cGy)	D40 (cGy)	D20 (cGy)
Lung_R	3212	96	2043	2029	1908	22	37	50	105
Lung_L	2840	259	3281	3264	3208	21	40	59	274
Lungs	6052	172	3281	3264	3208	22	38	53	146
Heart	773	143	2559	2356	1866	51	84	118	226
Esophagus	32.3	713	3199	3193	3135	12	99	204	1874
Bag_Bowel	1994	894	3336	3331	3296	102	277	494	2124
SpinalCord_PRV05	197	523	2134	2106	2031	31	102	201	1309
Liver	1908	1157	3296	3291	3264	495	1032	1167	1767
Kidney_R	146	190	834	792	573	82	115	153	360
ROI Name	Vol. (cc)	Mean (cGy)	D0.03cc (cGy)	D0.1cc (cGy)	D1cc (cGy)	D70 (cGy)	D50 (cGy)	D40 (cGy)	D20 (cGy)
Kidney_L	169	241	1521	1387	930	95	240	289	386
SpinalCord	73.8	556	2041	2032	1957	37	115	285	1334
Spleen	276	972	3172	3165	3145	426	658	972	1369

Asplenic vaccinations?

Considerations for Extranodal Sites - Gastric

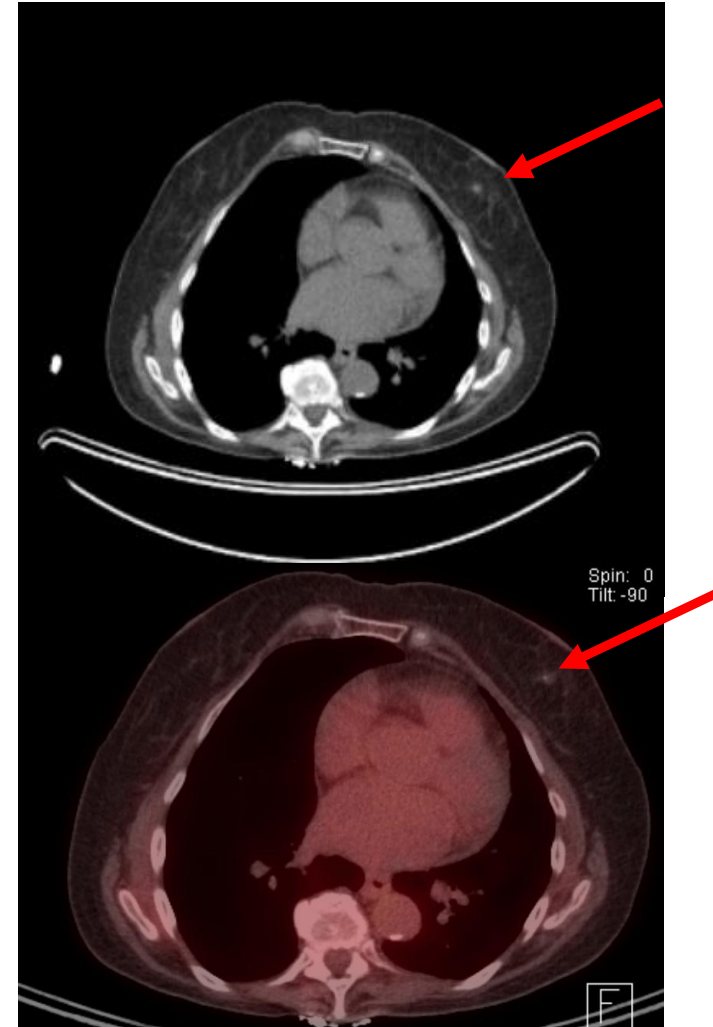
- PETCT is not as useful - reassessment includes endoscopy
 - For low grade lymphomas s/p definitive RT, this is required
 - Disease is often not visible on PETCT
 - For high grade lymphomas
 - If avid on PETCT, can be used for response assessment
 - Consider endoscopy for any question on response (common in stomach to have physiologic stomach uptake)
- RT target delineation
 - For low grade lymphomas, entire stomach must be included
 - Disease may not be clinically apparent on endoscopy
 - For high grade lymphoma, practices vary
 - Entire stomach is appropriate. Some treat well defined lesions with partial stomach

Breast B cell Lymphoma

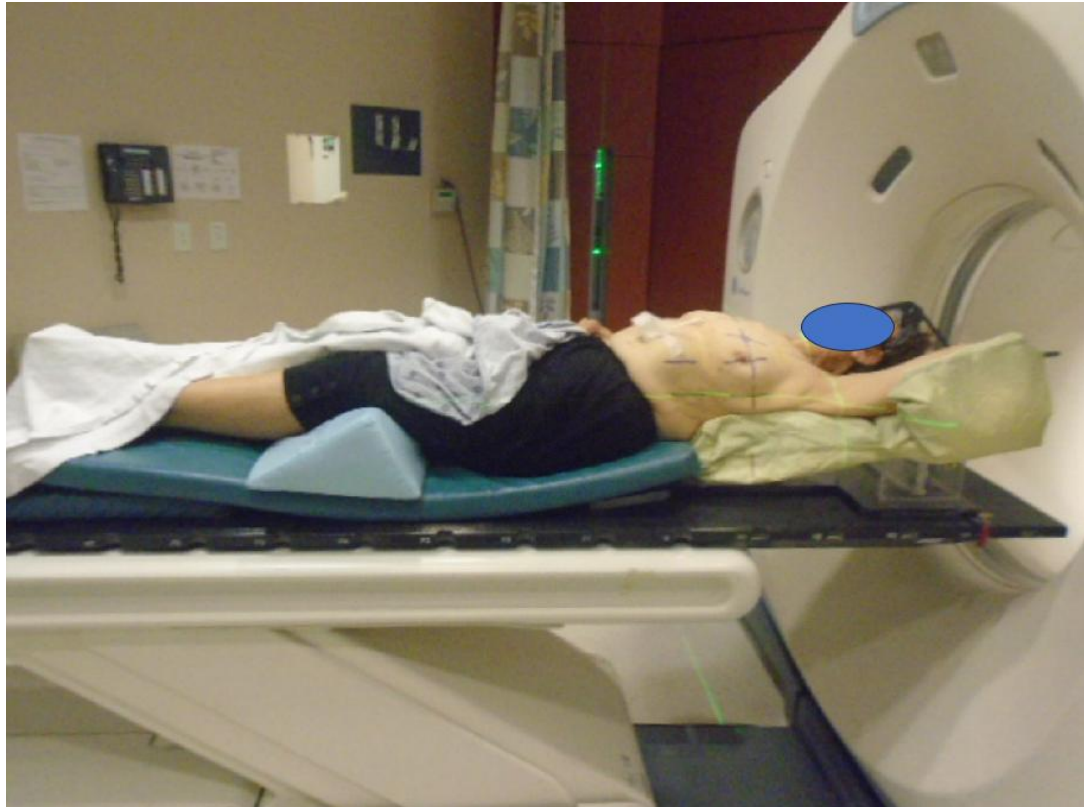Case 3: Breast B Cell Lymphoma: Low Grade

- ~70 y.o. female with L breast nodule on screening mammography
- Left breast, image-guided core biopsies:
 - EXTRANODAL MARGINAL ZONE LYMPHOMA
- PETCT
 - No FDG avid lesion of concern. The biopsy-proven subcentimeter left breast lymphoma is not FDG avid.
- Bone marrow biopsy negative

Sent for Radiation Oncology Consult

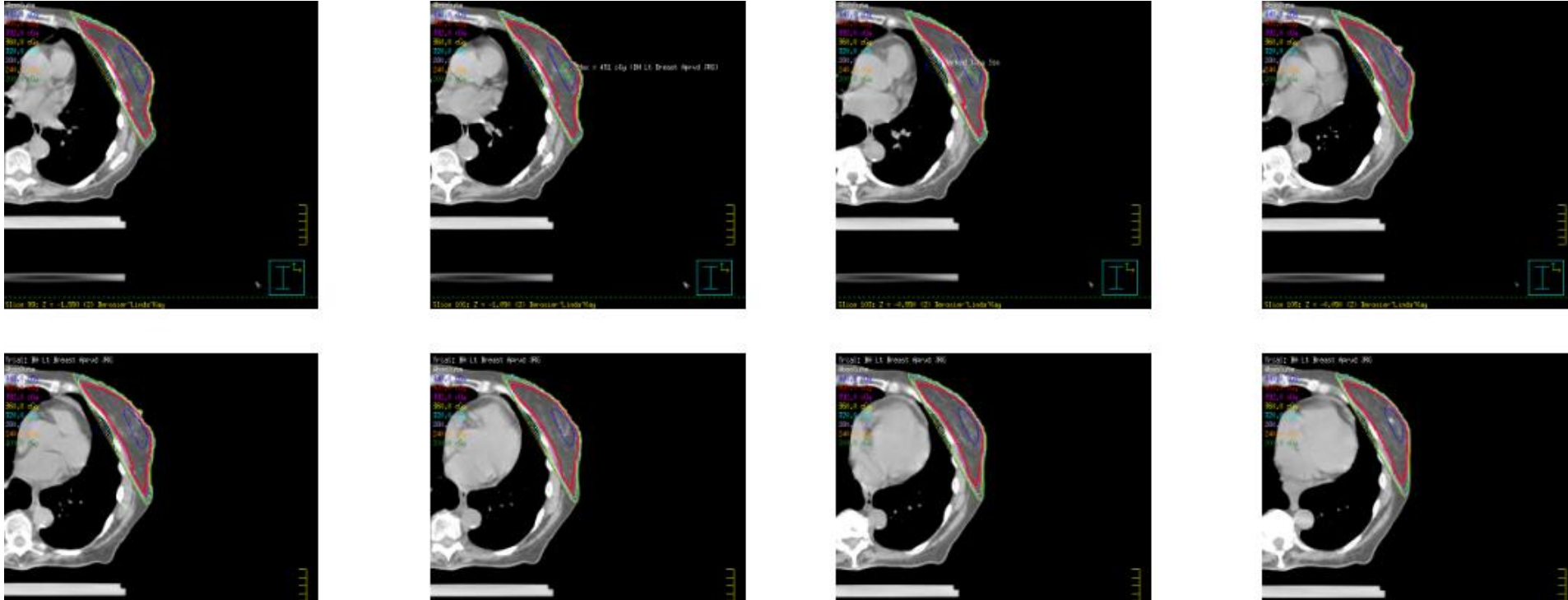


Simulation



- Ipsi arm over head
- Angle board
- Deep inspiration breath hold

Radiation Therapy Plan with 4 Gy



- Given pt age and minimal radiographic findings, opted to treat entire breast

Reassessment at three months

US breast:

- The biopsy-proven site of lymphoma is again seen in the left breast 6:00 position
- There has been **no increase in size or progression of disease since prior ultrasound**

CT chest

- Patient with known history of subcentimeter left breast lymphoma, **poorly evaluated on CT** and can be correlated with dedicated breast imaging
- IMPRESSION:
- No evidence of progressive adenopathy in the chest, abdomen or pelvis.

Reassessment at three months

US breast:

- The biopsy-proven site of lymphoma is again seen in the left breast 6:00 position
- There has been **no increase in size or progression of disease since prior ultrasound**

CT chest

- Patient with known history of subcentimeter left breast lymphoma, **poorly evaluated on CT** and can be correlated with dedicated breast imaging

IMPRESSION:

- No evidence of progressive adenopathy in the chest, abdomen or pelvis.

- Reassessment can be difficult without FDG-avid disease
- If in doubt, recommend continued close observation
 - If no growth, consider findings as treated disease/no active disease

Case 2: Breast B Cell Lymphoma – High Grade

- 70 yo with palpable right breast lump and right axillary swelling
- CT Chest Abdomen Pelvis
 - Multiple enlarged bulky nodes in the right axilla - the largest measures 4 x 3 cm
 - 2.7 x 2.5 cm soft tissue density/nodule in the right breast
- Biopsy of the right axillary lymph node and right breast mass
 - Large B-cell lymphoma
- PETCT
 - FDG avid right breast mass is concerning for malignancy
 - FDG avid right lower cervical/supraclavicular and axillary nodes are most compatible with nodal disease.
- Bone marrow – negative
- MRI brain – negative
- LP – negative

Recommended to start therapy with RCHOP

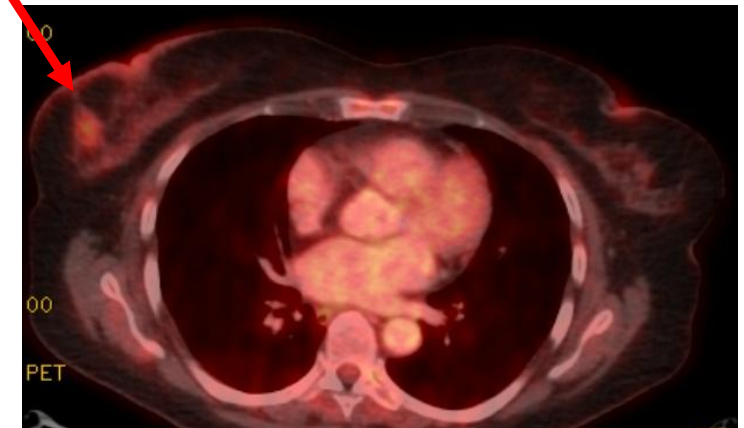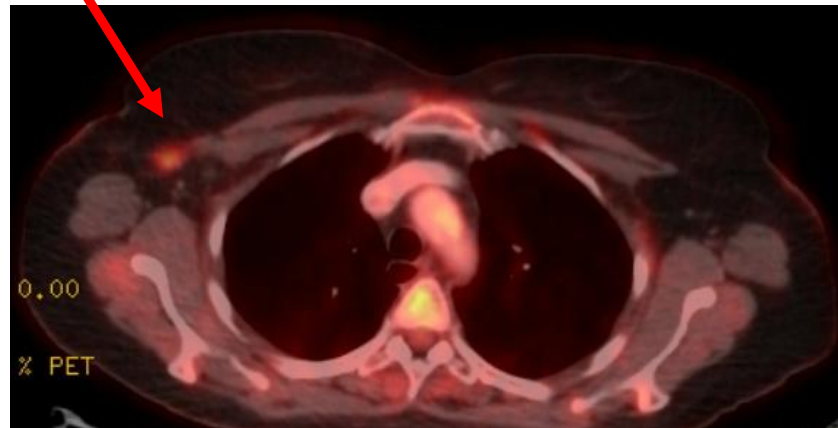
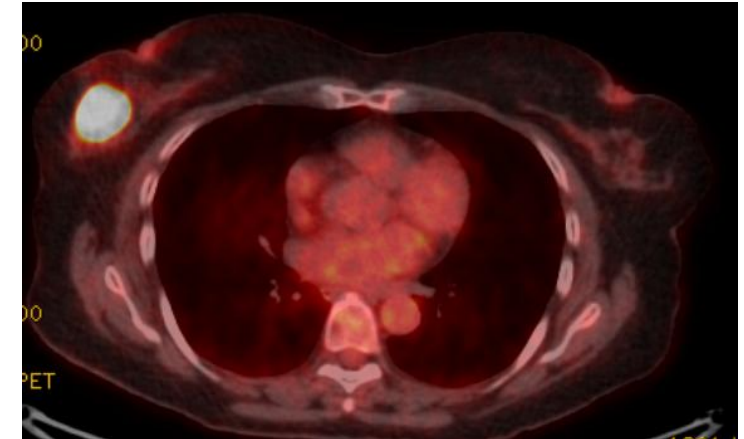
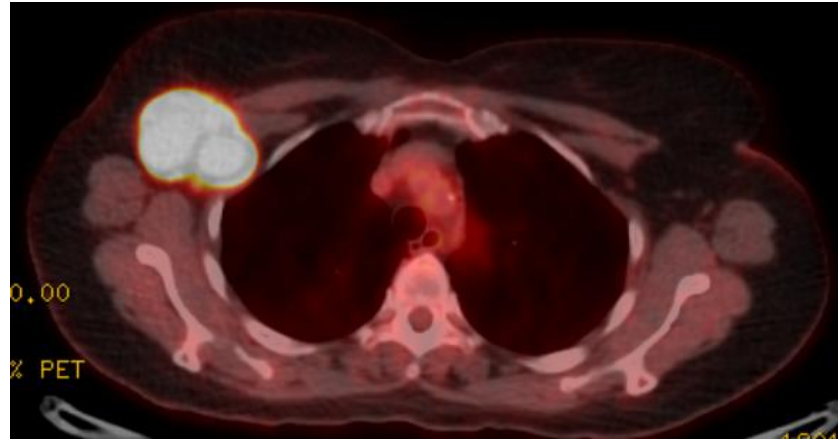
PETCT imaging

Initial PETCT with FDG avid breast and axillary disease

3c RCHOP

Restaging PETCT

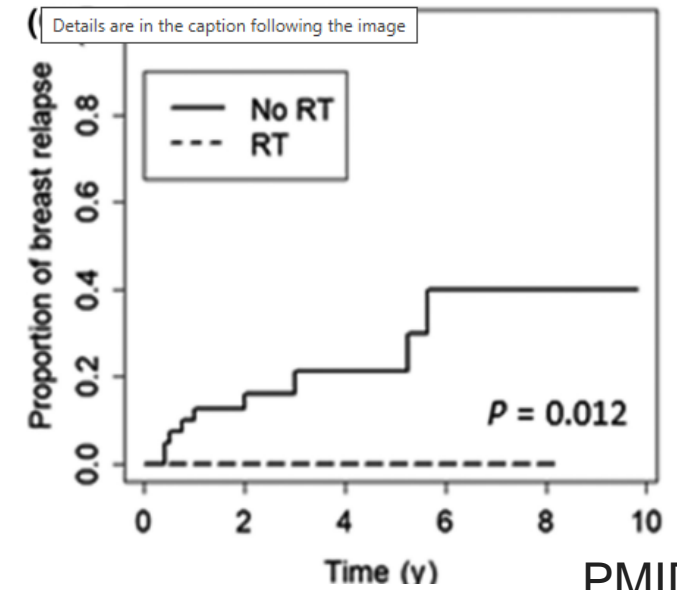
- Significant decrease in R breast and R neck/axillary lesions
 - Residual lesions show uptake similar or less than the liver parenchyma
 - No new FDG avid lesions
- Lymphoma 5-PS: 3



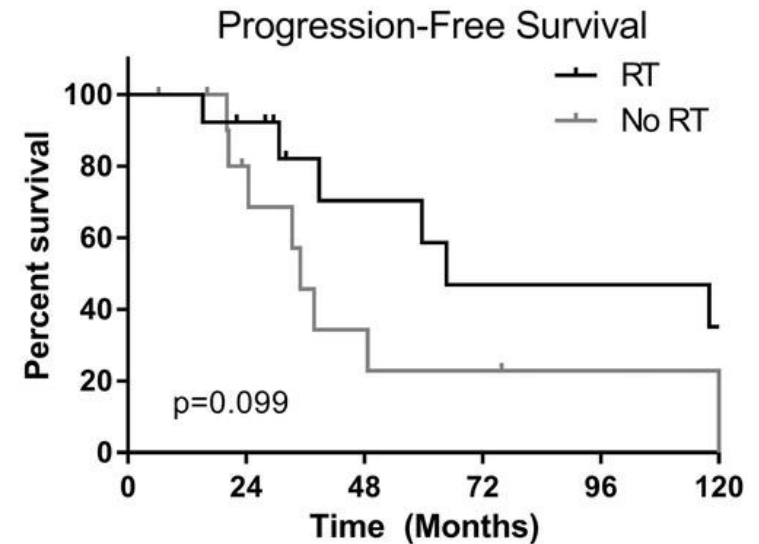
Patient completed 6c RCHOP and 2c HD methotrexate

Rad Onc Consult

- Studies show benefit of consolidation RT for breast DLBCL:
 - Improved local control
 - Improved progression free survival
- Given high risk of relapse and low toxicity field for 70 yo, she was recommended consolidation RT

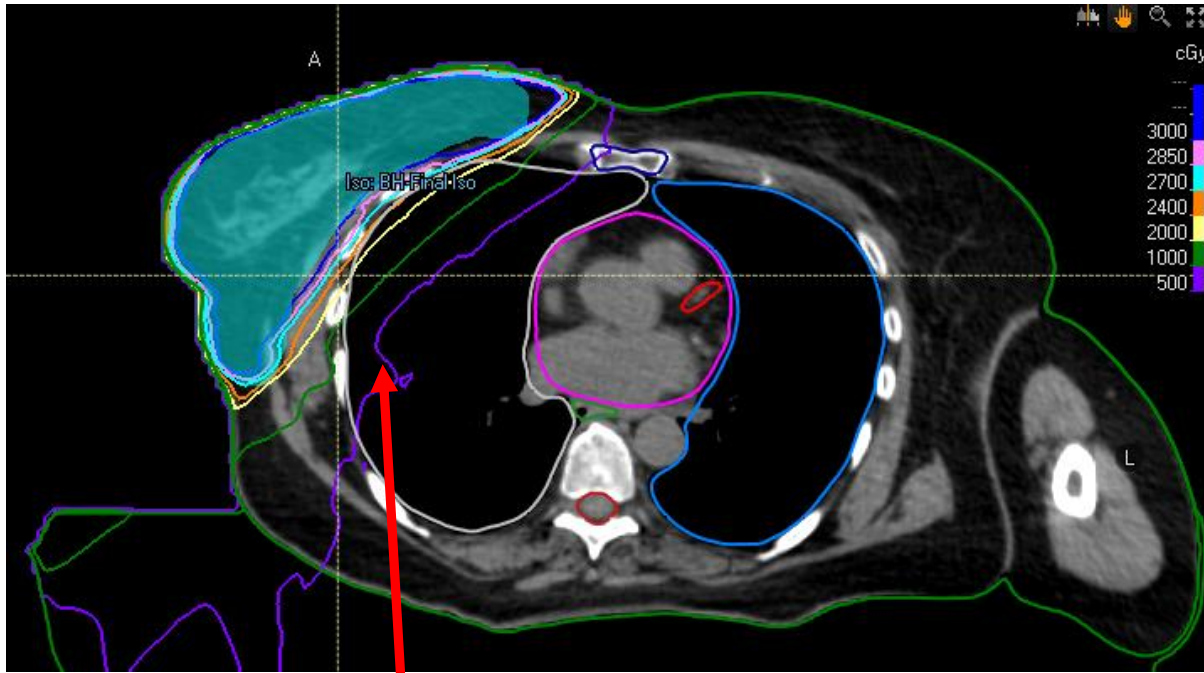


PMID: 30302857

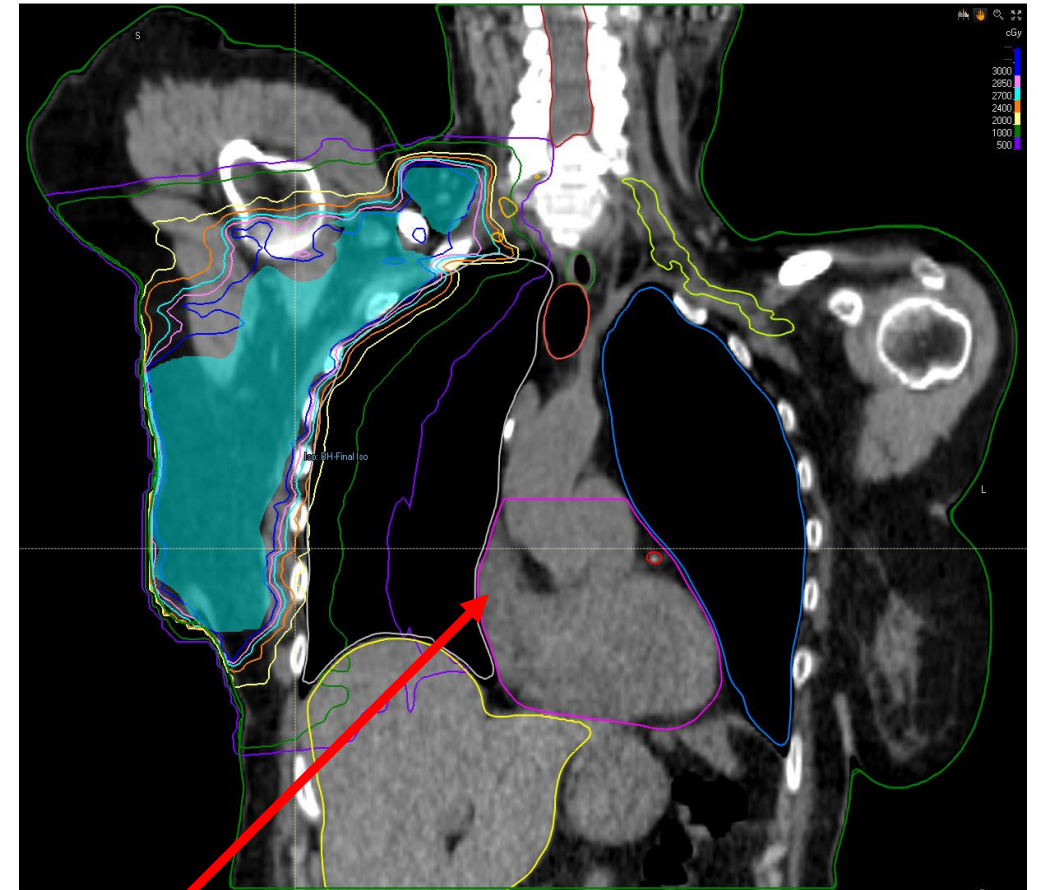


PMID: 29697005

RT Plan with 30 Gy in 15 fractions



Even low dose 5 Gy line off most of R lung



Heart completely spared

Considerations for Extranodal Sites - Breast

- Reassessment. Non avid – mammogram? US? MRI?
- Different relapse risk patterns – high grade
 - CNS risk – ppx?
 - Also true for adrenal, kidney, testes
 - Late/continuous relapse
- RT target volume considerations
 - Low grade lymphoma
 - Often entire breast
 - Can consider partial breast in young patient with well-circumscribed lesion
 - High grade lymphoma
 - Often still whole breast with involved nodes. Use PETCT to guide ISRT treatment volumes

Printed by julian.guntner on 20/12/2026 3:51:51 PM. Copyright © 2026 National Comprehensive Cancer Network, Inc. All Rights Reserved. NCCN Guidelines Version 3.2026
Diffuse Large B-Cell Lymphoma

PROGNOSTIC MODEL TO ASSESS THE RISK OF CNS DISEASE ^d	
RISK FACTORS	RISK GROUPS
<ul style="list-style-type: none"> • Age >60 years • Serum LDH > normal • Performance status >1 • Stage III or IV • Extranodal involvement >1 site • Kidney or adrenal gland involvement 	<ul style="list-style-type: none"> • Low risk 0–1 • Intermediate-risk 2–3 • High-risk 4–6 or kidney or adrenal gland involvement
<ul style="list-style-type: none"> • Additional indications for CNS prophylaxis independent of CNS risk score <ul style="list-style-type: none"> ▶ Testicular lymphoma ▶ Primary cutaneous DLBCL, leg type ▶ Stage IE DLBCL of the breast ▶ Kidney or adrenal gland involvement • Role of CNS prophylaxis remains controversial but can be considered in patients with high-risk factors based on the aforementioned criteria. If CNS prophylaxis is used, options include: <ul style="list-style-type: none"> ▶ Systemic high-dose methotrexate (3–3.5 g/m² for 2–4 cycles) during or after the course of treatment^e and/or ▶ IT methotrexate and/or cytarabine (4–8 doses) during or after the course of treatment 	

Considerations for Extranodal Lymphomas

- Different methods of reassessment beyond PETCT. May require:
 - Endoscopy/colonoscopy
 - MRI brain
 - Mammogram/MRI breast
 - Specialized derm exam
 - MRI bone
 - Cystoscopy
- ISRT target volume delineation
 - Include entire extranodal organ?
 - Can be appropriate for orbit, breast, salivary gland, stomach
 - Not for lung, skin, bone, bowel
- Different patterns of relapse/relapse risk compared to nodal BCLs
 - CNS risk increased for adrenal/kidney/testes/breast
 - Late/continuous risk of relapse for sites such as breast and testes

Acknowledgements

Department of Radiation Oncology – Heme RO



Tim Lin * Penny Fang * Chelsea Pinnix * Bouthaina Dabaja * Jillian Gunther * Susan Wu * Omran Saifi

Clinic Team

JoAnn Shank
Shryll Turner
Paula Barrenechea
Jinsu James
Jennifer Pimentel
Erin Espinosa
Bettina Calalang

Research Team

Nathan Comeaux
Elizabeth Dunegan
Amanda Martinez Lopez
Chris Pearlath
Tiara Willis
Diana Amaya
Charles Masino

Collaborators

Department of Gastroenterology Hepatology and Nutrition

Manoop Bhutani MD

Department of Diagnostic Radiology

Priya Bhosale

Department of Hematopathology

Jie Xu MD

Department of Biostatistics

Wenli Dong MS

Sterling Foundation

Department of Lymphoma/Myeloma

Christopher Flowers MD
Sairah Ahmed MD
Dai Chihara MD
Ayushi Chauhan MD
Luis Fayad MD
Fateeha Furqan MD
Frederick Hagemester MD
Mark Hamilgon MD PhD
Hun Ju Lee MD
Swami Iyer MD
Preetesh Jain MD PhD
Anath Lionel MD PhD
Dustin McCurry MD
Luis Malpica MD
Sattva Neelapu MD
Ranjit Nair MD
Chijioke Nze MD
Alma Rodriguez MD
Paolo Strati MD
Michael Wang MD
Jason Westin MD

The Patients

