Doctors of Thoracic Surgery®

EBUS: from Invention to Clinical Gold Standard

Kazuhiro Yasufuku MD, PhD, FRCSC
Head, Division of Thoracic Surgery, University Health Network
FG Pearson – RJ Ginsberg Chair in Thoracic Surgery
William Coco Chair in Surgical Innovation for Lung Cancer
Director of Endoscopy, University Health Network
Director, Interventional Thoracic Surgery Program
Professor and Chair, Division of Thoracic Surgery, University of Toronto

50th Toronto Thoracic Surgery Refresher Conference *June 12th 2026*

UHN Canada's Hospital

Doctors of Thoracic Surgery®

Disclosure

- Industry-sponsored grants
  - Olympus Corp.
  - Johnson and Johnson
  - ODS Medical Inc
- Consultant
  - Olympus America Inc.
  - Medtronic
  - Johnson and Johnson
  - Astra Zeneca
  - Merck
- Research Collaboration
  - OKF Technology
- Advisory Board
  - Olympus America Inc
  - Medtronic
  - Johnson and Johnson
  - Node AI

UHN Canada's Hospital

Doctors of Thoracic Surgery®

Objective

- Review the history of the convex probe EBUS
- Introduce new developments in convex probe EBUS
- Look into the future of EBUS-TBNA in management of lung cancer

UHN Canada's Hospital

Doctors of Thoracic Surgery

History – CP-EBUS Preliminary studies

Bronchoscopic Ultrasonography in the Diagnosis of Lung Cancer

Ryosuke Ono[1], Keiichi Suemasu[2] and Toshiyuki Matsunaka[3]

Departments of [1]Endoscopy and [2]Surgery, National Cancer Center Hospital, and [3]Aloka Research Laboratory, Tokyo

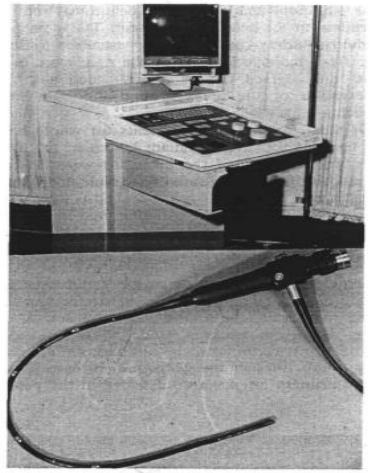

Fig. 1. Instrumentation for ultrasonic bronchoscopic diagnosis. Echo-camera, SSD-630, and ultrasonic bronchoscope

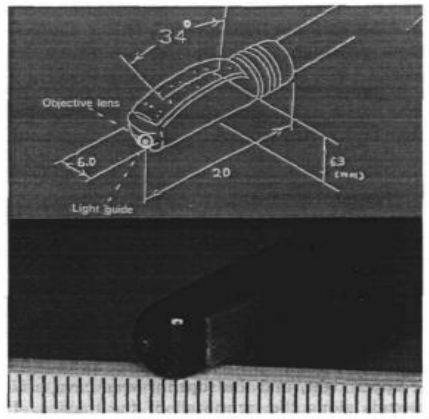

Fig. 2. Specifications of ultrasonic bronchoscope tip. Curve linear transducer (convex type) with a transmission frequency of 7.5 MHz. The maximum diameter of the tip is 6.3 mm and the resulting sector field has a divergence of 34°.

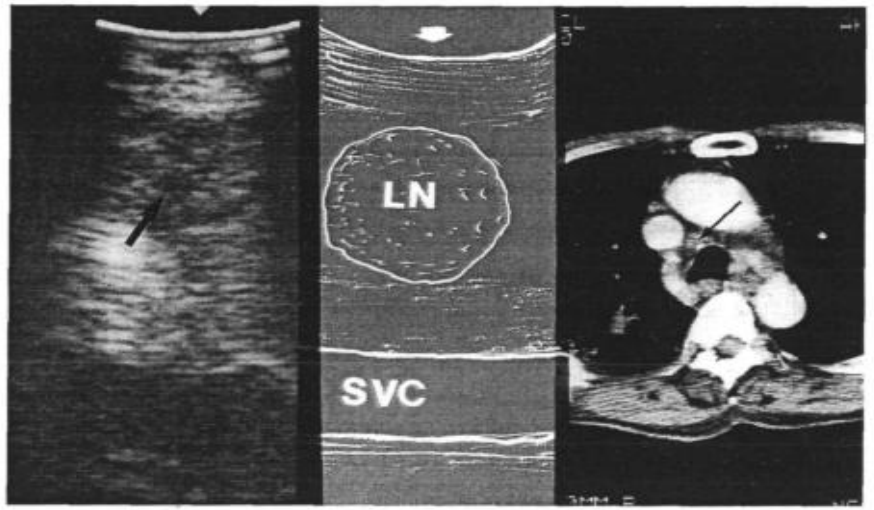

Ono et al. Jpn J Clin Onc 1993; 23: 34-40

UHN Canada's Hospital

Doctors of Thoracic Surgery

Development – CP-EBUS

- BF-UM40





UHN Canada's Hospital

Doctors of Thoracic Surgery

Development – CP-EBUS

- Radial ⇒ Convex Probe

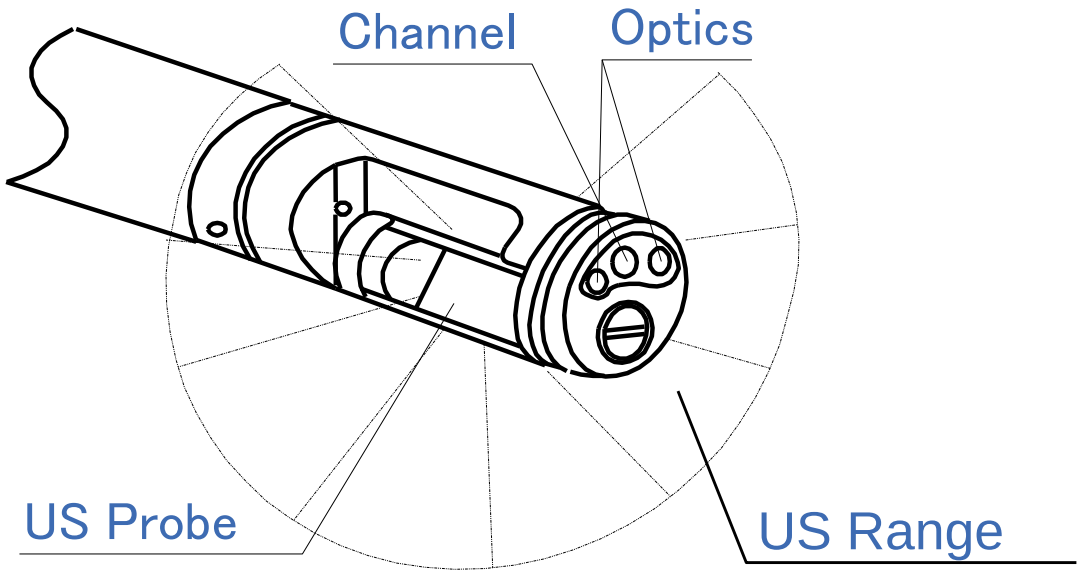

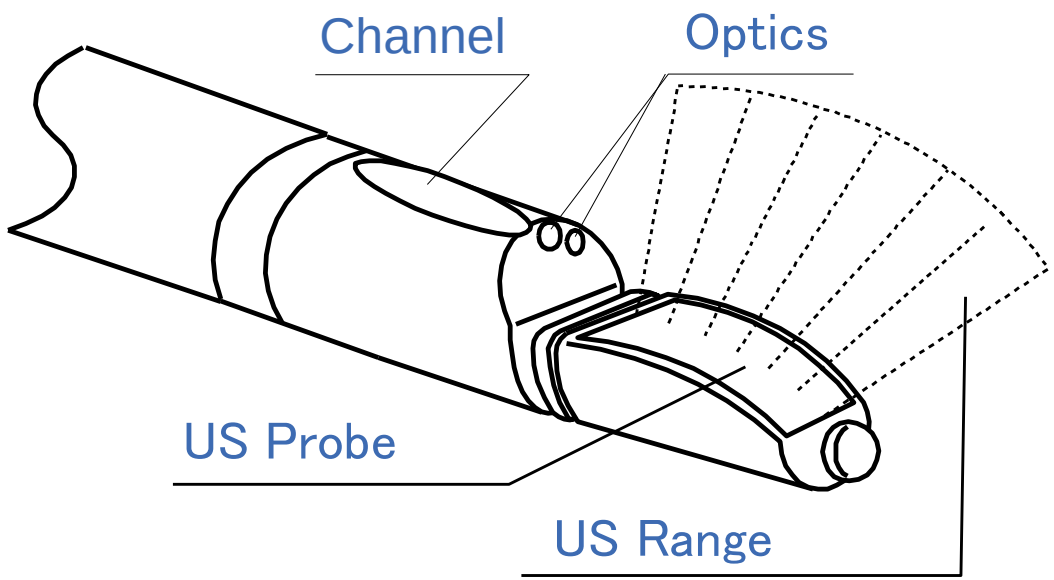

UHN Canada's Hospital

Doctors of Thoracic Surgery

History – CP-EBUS Preliminary studies

- Endobronchial ultrasound using a new convex probe: a preliminary study on surgically resected specimens.
  - Convex-probe endobronchial ultrasound
  - First described in 2004

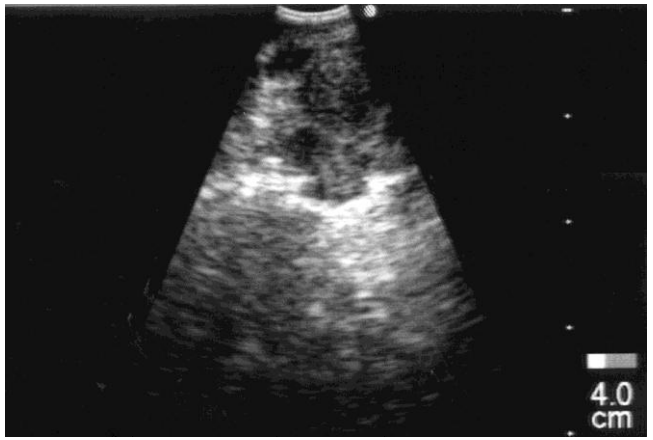





Yasufuku et al. Oncol Rep 2004; 11:293-6

UHN Canada's Hospital

Doctors of Thoracic Surgery

First Clinical Case – 2002



Visualization of LN
March 2002



EBUS-TBNA of LN
May 2002

UHN Canada's Hospital

Convex Probe EBUS (CP-EBUS)



Division of Thoracic Surgery
Toronto General Hospital

Doctors of Thoracic Surgery

EBUS Scope - EB1970UK (Pentax Medical)

New Small Hitachi Linear Array Ultrasound Transducers

- 19 French
- 6.3mm Insertion Tube
- 2mm working channel
- Color CCD video images
  - 45° Forward Oblique
- Hitachi 5500 scanner
  - 75° Forward Oblique
  - 5,6.5,7.5,9, 10 MHz options



UHN Canada's Hospital

EBUS scope – EB-530US (FUJIFILM)

Fujifilm Ultra Small Super CCD Chip

10° forward oblique view

Wide Field of View: 120°

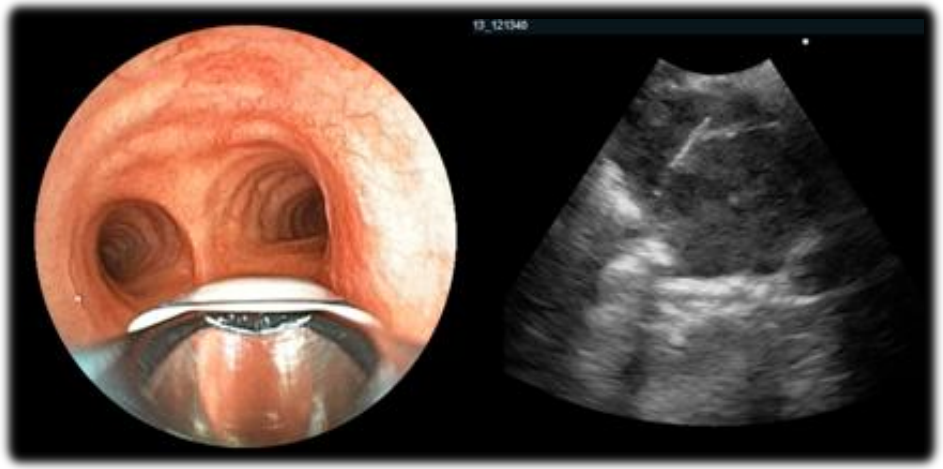





Doctors of Thoracic Surgery

New EBUS Bronchoscope (BF-UC190F)



- NEW CP-EBUS
- BF-UC190F/BF-UC290F enables enhanced access and control to support staging and diagnosis of even difficult-to-reach lymph nodes and lesions

UHN Canada's Hospital

Doctors of Thoracic Surgery

Endoscopic Staging - EBUS-TBNA

- Access to all LN stations accessible by Med as well as N1 nodes
- A minimally invasive modality
- Sensitivity 85-96%
- Real time procedure
- Doppler mode enables differentiation of LN from vessels
- Gold standard of invasive mediastinal staging

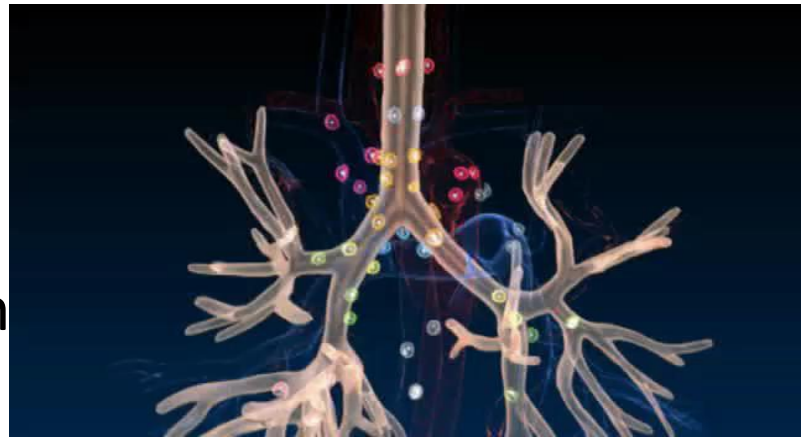

Hanna WC, Yasufuku K. Ther Adv Respir Dis. 2013; 7(2): 111-8

UHN Canada's Hospital

Clinical Applications of EBUS-TBNA

- Lymph node staging of lung cancer
  - Pre-operative staging
  - Post-operative evaluation
  - Restaging
- Dx of centrally located intrapulmonary tumors
- Mediastinal and hilar adenopathy NYD
  - Sarcoidosis (Overall yield of 90-96%)
  - Lymphoma (Sensitivity 57-91%)

Doctors of Thoracic Surgery

EBUS-TBNA for Lung Ca Staging

- EBUS-TBNA Systematic Review and Meta-analysis
    - 22 studies
    - >2000 patients

- Sensitivity: 0.88-0.93 (95% CI 0.79-0.94)
- Specificity: 1 (95% CI 0.92-1)

- Equivalent to Mediastinoscopy sensitivity, NPV, diagnostic accuracy

Gu P. et al. Eur J Ca. 2009;45:11389-96
Adams K. et al. Throax. 2009;64:757-62
Zhang R. et al. Eur J Ca. 2013;49:1860-67

UHN Canada's Hospital

Lung ca mediastinal staging

- Invasive Mediastinal Staging of Lung Cancer
  - ACCP Evidence-Based Clinical Practical Guideline (3rd Edition)
  - Overall sensitivity 89% (46-97%), NPV 91% (n=2756)

Study	Year	No.	Stage	Thoro	Prev	Sens	Spec[a]	PPV[a]	NPV
Fielding[341]	2009	68	cN1-3	Sel	87	95	(100)[a]	(100)[a]	(67)[b]
Steinfort[334]	2011	117	cN1-3	Sys	80	97	(100)[a]	(100)[a]	87
Cetinkaya[332]	2011	52	cN2-3	Sys	80	95	(100)[a]	(100)[a]	83
Rintoul[344]	2009	109	cN1-3	Sys	77	91	(100)[a]	(100)[a]	60
Gilbert[339]	2009	67	cN1-3	Sel	70	93	(100)[a]	(100)[a]	83
Yasufuku[349]	2005	108	cN1-3	Sys	69	95	(100)[a]	(100)[a]	90
Yasafuku[350]	2004	70	cN1-3	Sys	67	96	(100)[a]	(100)[a]	92
Szlubowski[343]	2009	226	cN0-3	Sys	64	89	(100)[a]	(100)[a]	84
Ye[333]	2011	101	cN1-3	Sel	63	95	(100)[a]	(100)[a]	93
Cerfolio[336]	2010	92	cN2	Sys	63	57	(100)[a]	(100)[a]	79
Lee BE[329]	2012	73	cN0-3	Sys	62	95	(100)[a]	(100)[a]	94
Bauwens[345]	2008	106	cN1-3	Sys	58	95	(100)[a]	(100)[a]	91
Sun[337]	2010	49	cN1-3	Sys	53	85	96	96	85
Herth[307]	2010	139	cN1-3	Sel	52	91	(100)[a]	(100)[a]	92
Memoli[331]	2011	100	cN1-3	Sys	47	87	(100)[a]	(100)[a]	89
Omark Petersen[340]	2009	151	cN2-3	Lim	43	85	(100)[a]	(100)[a]	89
Yasufuku[330]	2011	153	cN0-3	Sys	35	81	(100)[a]	(100)[a]	91
Hwangbo[335]	2010	150	cN2-3	Sys	31	84	(100)[a]	(100)[a]	93
Wallace[296]	2008	138	cN2-3	Sys	30	69	(100)[a]	(100)[a]	88
Lee HS[346]	2008	102	cN2-3	Sys	30	94	(100)[a]	(100)[a]	97
Hwangbo[342]	2009	117	cN2-3	Sys	26	90	(100)[a]	(100)[a]	97
Yasufuku[348]	2006	102	cN1-3	Sys	25	92	(100)[a]	(100)[a]	97
Szlubowski[343]	2010	120	cN0	Sel	22	46	99	93	86
Herth[211]	2006	100	cN0	Sys	21	92	(100)[a]	(100)[a]	96
Nakajima[338]	2010	49	cN1-3	Sys	18	67	(100)[a]	(100)[a,c]	93
Herth[210]	2008	97	cN0	Sys	10	89	(100)[a]	(100)[a,c]	99
Median: Prevalence ≥ 80						**96**			**83**
Median: Prevalence 60-79						**91**			**83**
Median: Prevalence 40-59						**87**			**89**
Median: Prevalence 20-39						**87**			**95**
Median: Prevalence < 20						**78**			**96**
Median: cN1-3						**91**			**89**
Median: cN0						**89**			**96**
Summary: median		**2,756**			**58**	**89**	**(100)[a]**	**(100)[a]**	**91**

Minimally invasive needle techniques to stage the mediastinum have become increasingly accepted and are the tests of first choice to confirm mediastinal disease in accessible LN stations

If negative, these needle techniques should be followed by surgical biopsy

All abnormal scans should be confirmed by tissue biopsy (by whatever method is available) to ensure accurate staging

Silvestri et al. Chest. 2013; 143: e211s-250s

Doctors of Thoracic Surgery®

Indications for Invasive Mediastinal Staging

- ACCP Guidelines, ESTS Guidelines
  - Positive CT (short axis diameter ≥ 1cm)
  - Positive PET
  - T2 or greater peripheral tumors
  - Centrally Located tumors
  - N1 disease
- Personal Indications
  - High risk surgery
  - Sublobar resection
  - SBRT, other ablative treatment (Hashimoto K, Yasufuku K et al. Lung Cancer. 2018 Sep; 123: 1-6)

UHN Canada's Hospital

Doctors of Thoracic Surgery

Proposed N Categories and Descriptors for N staging – 9th edition

Table 5. Proposed N Categories and Descriptors

Eighth	Ninth	Descriptor
NX		Regional lymph nodes cannot be assessed
N0		No regional lymph node metastasis
N1		Metastasis in ipsilateral peribronchial and/or ipsilateral hilar lymph nodes and intrapulmonary nodes, including involvement by direct extension
N2		Metastasis in ipsilateral mediastinal and/or subcarinal lymph node(s)
	N2a	Single N2 station involvement
	N2b	Multiple N2 station involvement
N3		Metastasis in contralateral mediastinal, contralateral hilar, ipsilateral or contralateral scalene or supraclavicular lymph node(s)

The current N descriptors should be maintained, with the addition of new subdescriptors to N2 for single-station involvement (N2a) and multiple-station involvement (N2b).

JTO 2023; 19(5): 766-785

UHN Canada's Hospital

Systematic EBUS LN Assessment

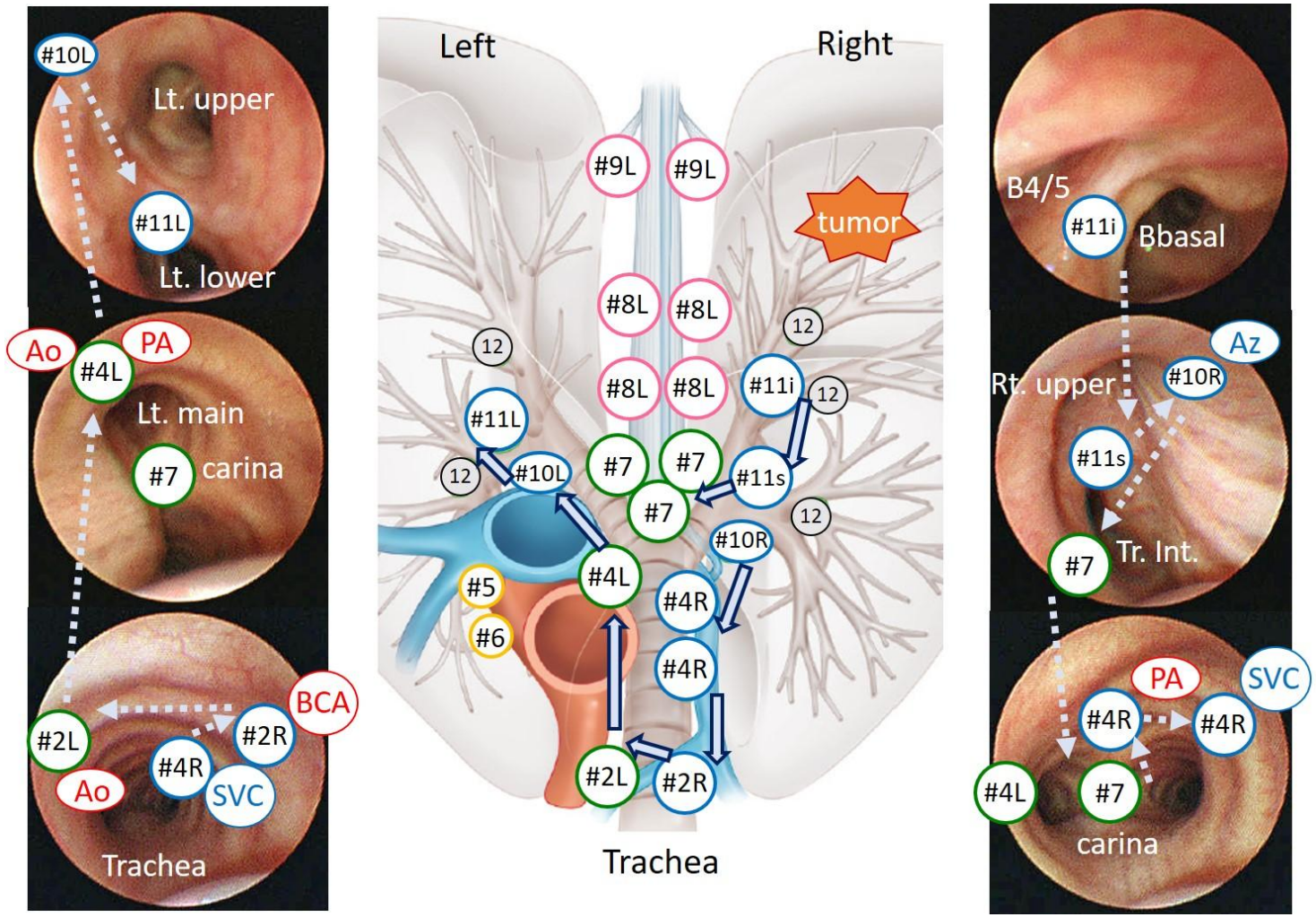

Courtesy Dr. T Nakajima

Doctors of Thoracic Surgery®

New Developments

UHN Canada's Hospital

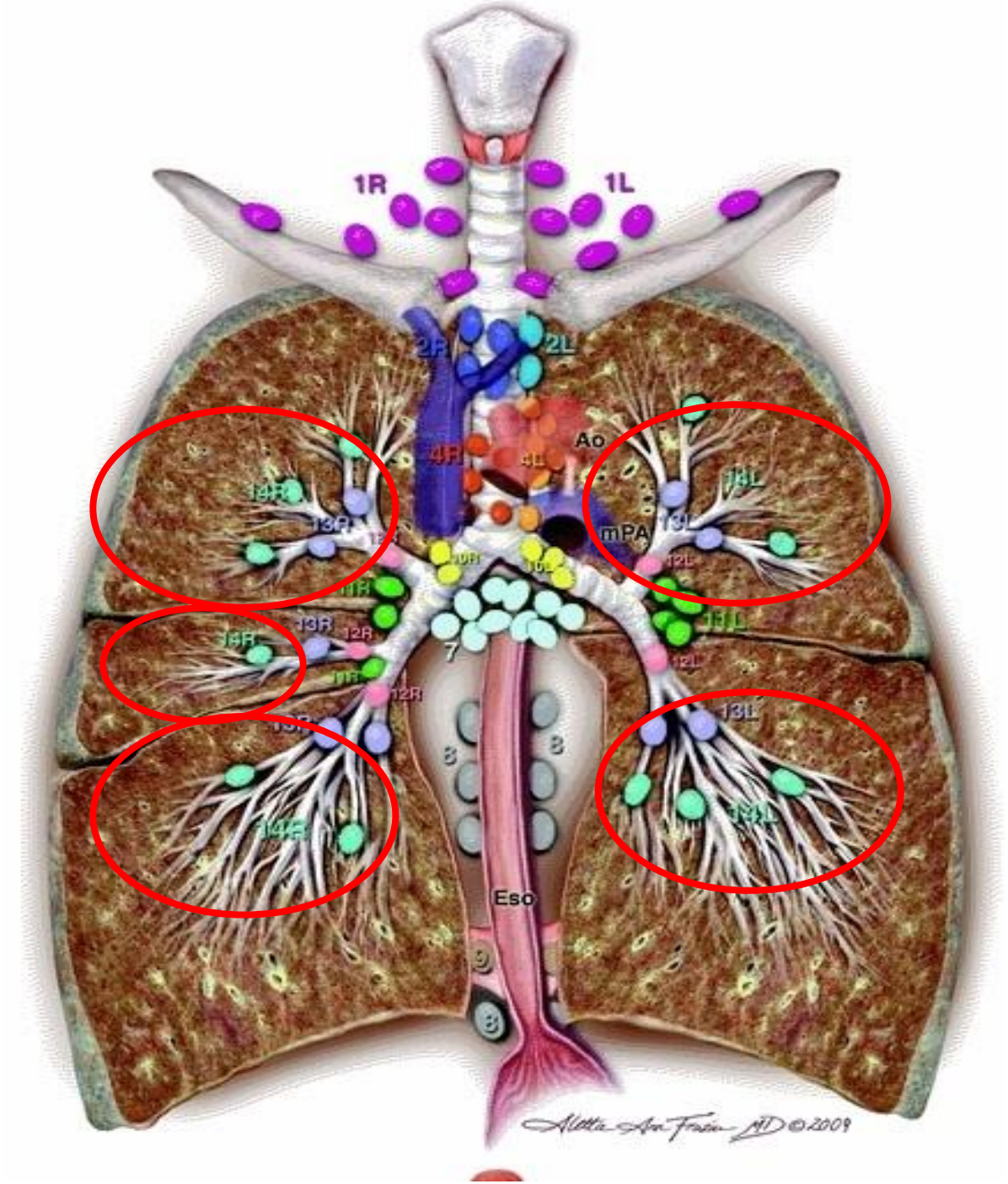

LN not assessable by EBUS

N1 LNs
part of 12, 13, 14

Doctors of Thoracic Surgery

Thin EBUS-TBNA scope



Wada et al, JOBIP 2014

UHN Canada's Hospital

Prototype TCP-EBUS in human lung

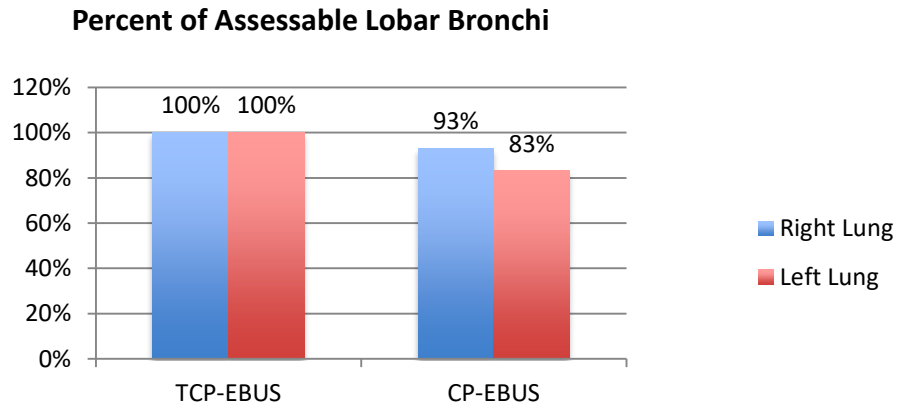



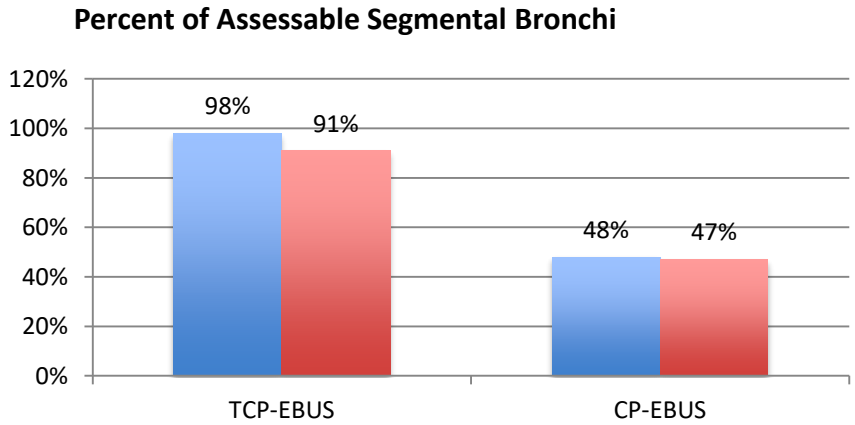



Patel et al, Ann Thorac Surg. 2016

Doctors of Thoracic Surgery

Olympus BF-UCP190F





UHN Canada's Hospital

BF-UCP190F / BF-UC190F / BF-UC180F



BF-UCP190F BF-UC190F BF-UC180F



BF-UC180F

BF-UC190F

BF-UCP190F



BF-UCP190F BF-UC190F BF-UC180F

	BF-UCP190F	BF-UC190F/UC290F	BF-UC180F/260FW
Distal end diameter (mm)	**5.9**	6.6	6.9
Channel diameter (mm)	**1.7**	2.2	2.2
Angulation range (U/D) (degrees)	**170/70**	160/70	120/90
Balloon Structure	**No**	Yes	Yes
Direction of View (degree)	**14**	20	35

Spectrum Analysis of EBUS Image

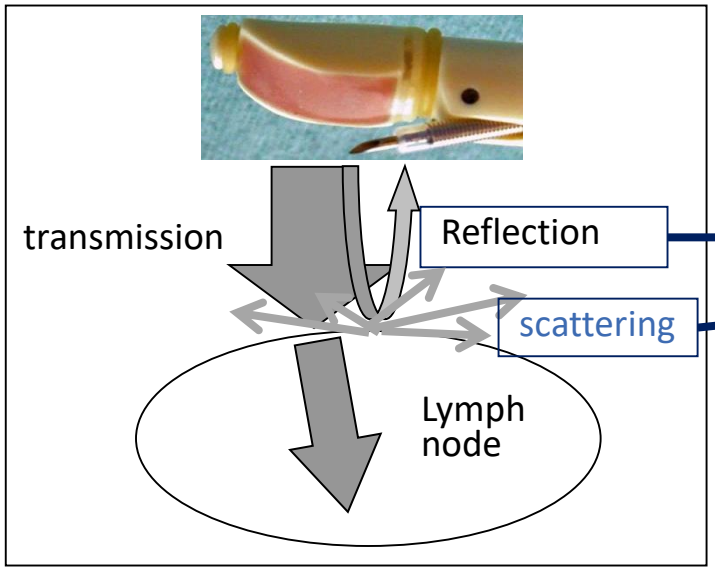

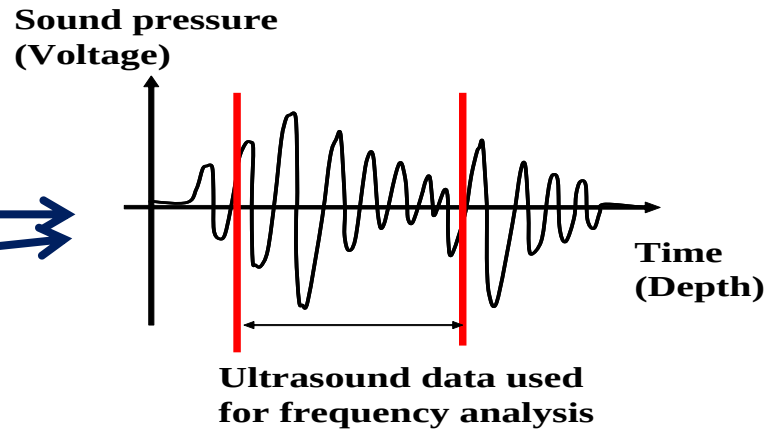

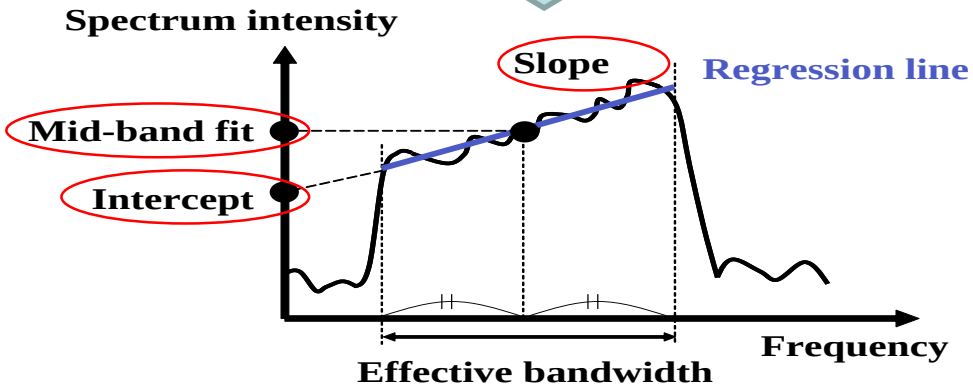

1) Midband-fit (dB, value of the regression line at the center frequency),
2) Slope (dB/MHz),
3) Intercept (dB, extrapolation to zero frequency)

Doctors of Thoracic Surgery

Intercept Parameter

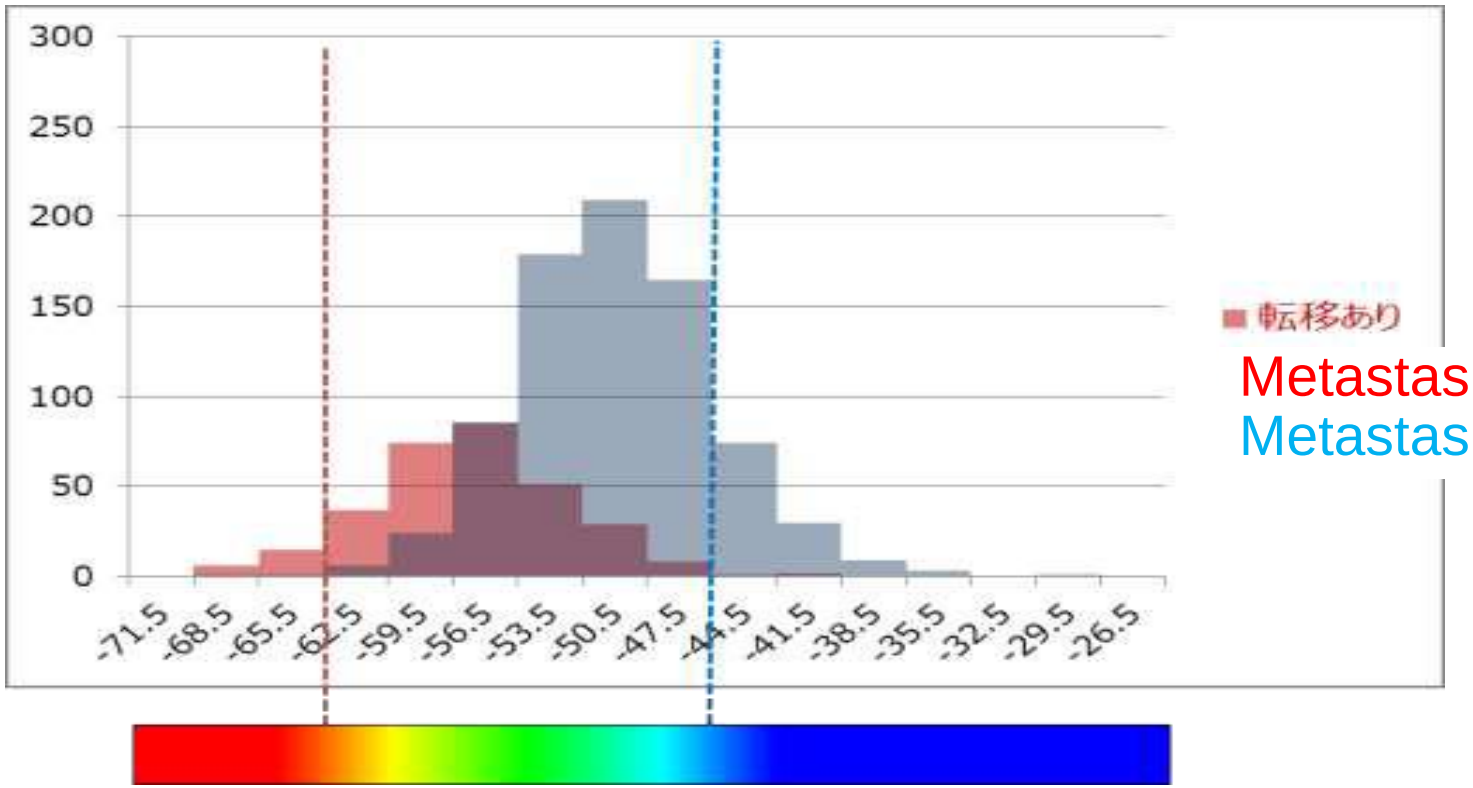

Ujiie et al, Chest 2016 abstract

UHN Canada's Hospital

Doctors of Thoracic Surgery

Example use of Spectrum Analysis

Metastasis (+)

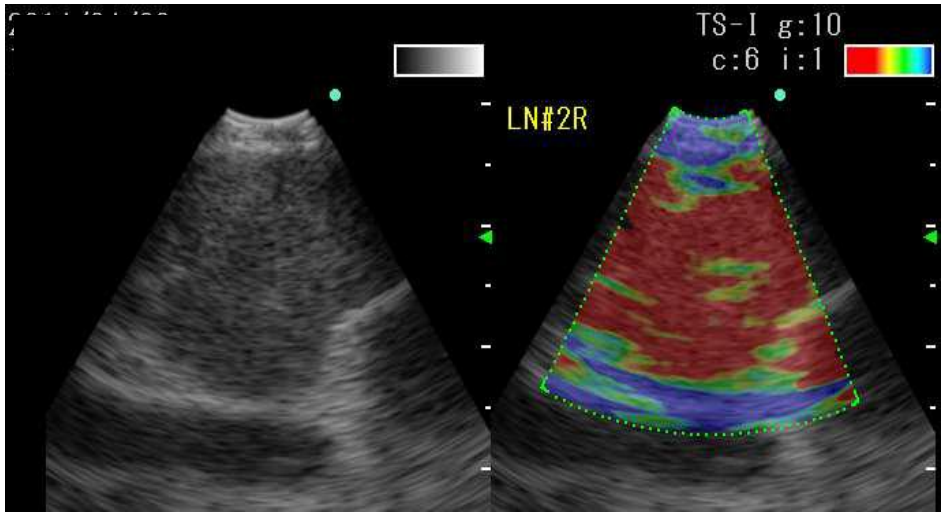

Metastasis (-)

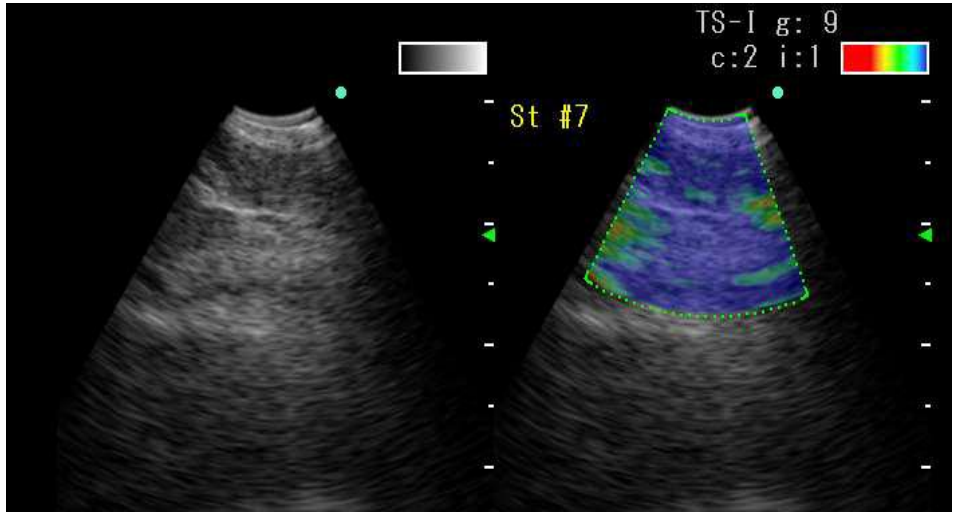



Malignant

Benign

Ujiie et al, Chest 2016 abstract

UHN Canada's Hospital

Artificial intelligence

EndoBRAIN-EYE® (OLYMPUS)

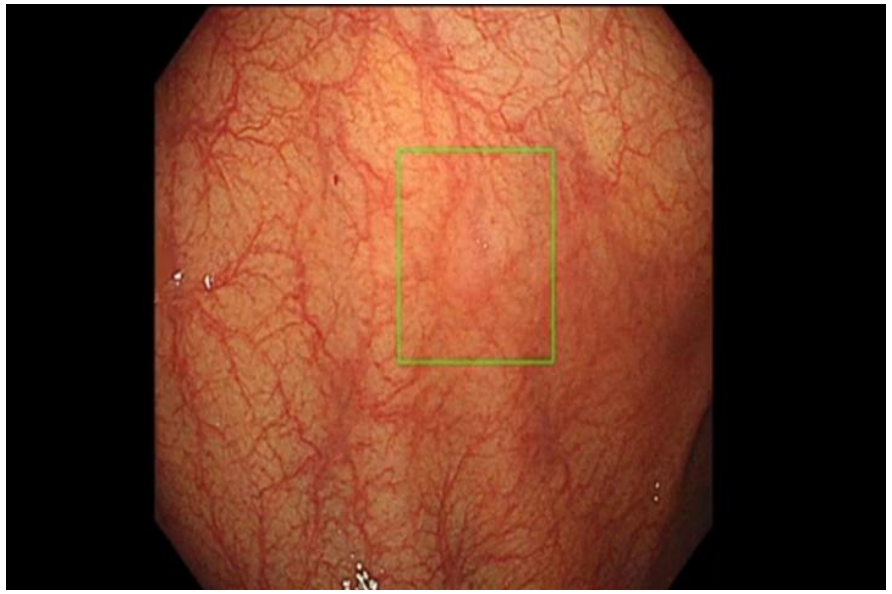

AI-powered real-time diagnostic system

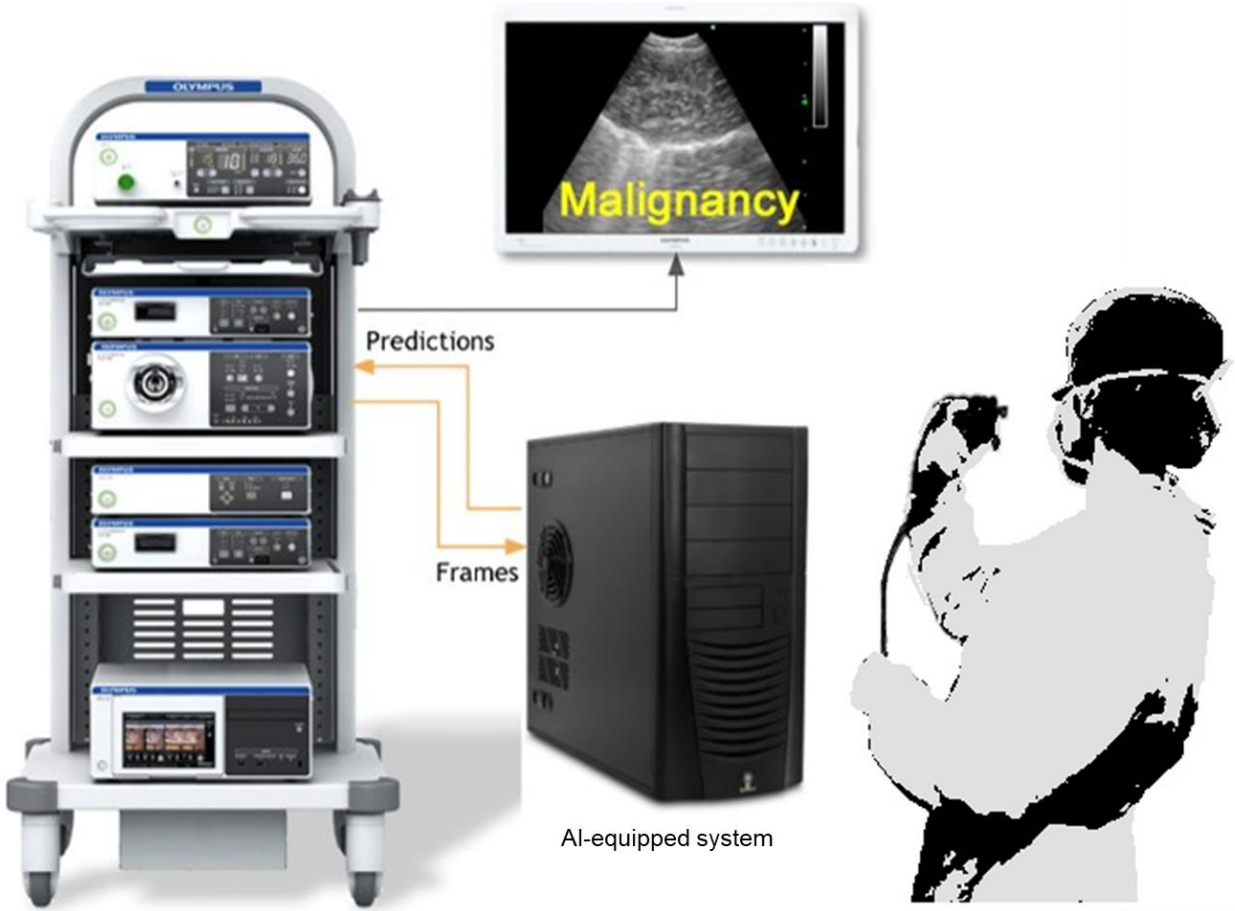

Convolutional Neural Network

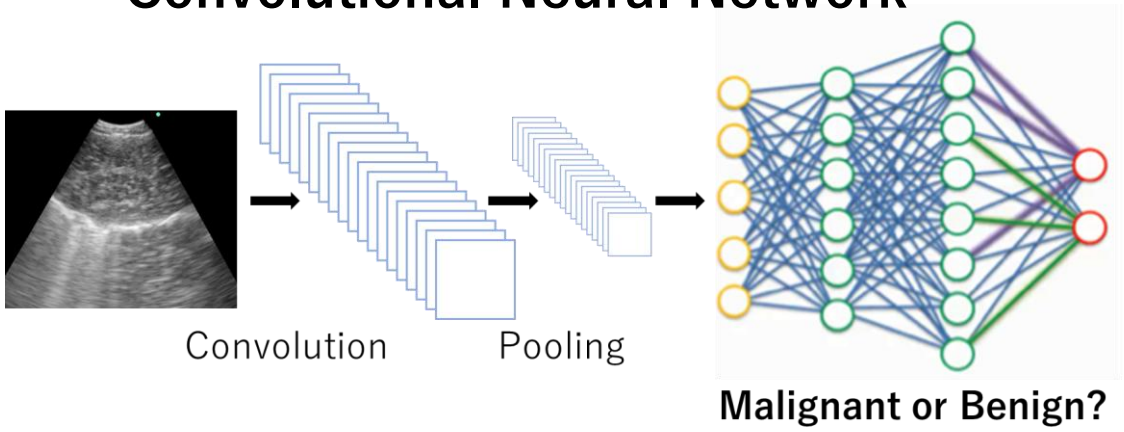

Artificial intelligence for EBUS [Preliminary results]

- 122 lymph nodes (76 malignant, 46 benign)
- 64 video files (5400 frames)

EBUS image　　SELF (Grad-CAM)

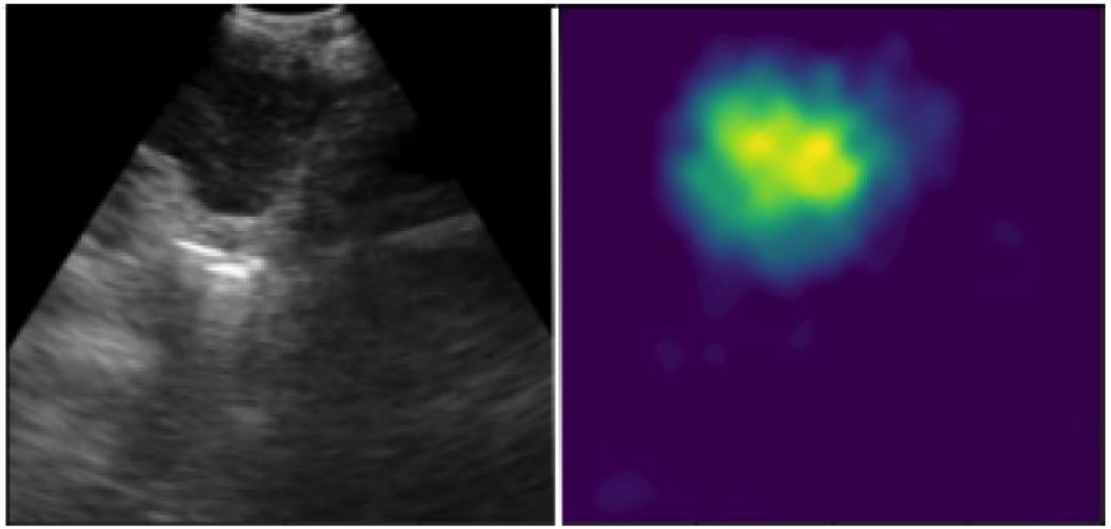

*Grad-CAM: a technique for creating a class-specific heatmap

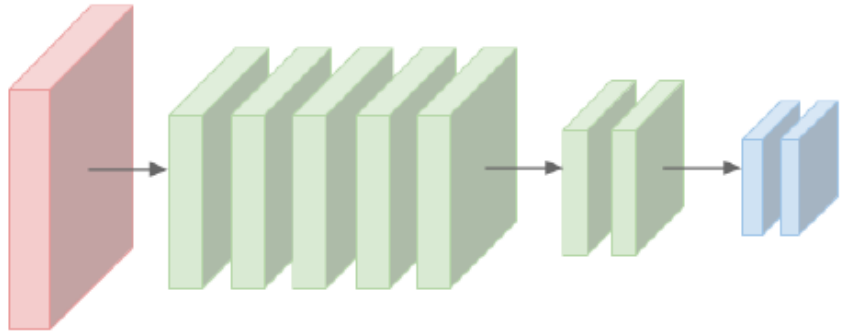

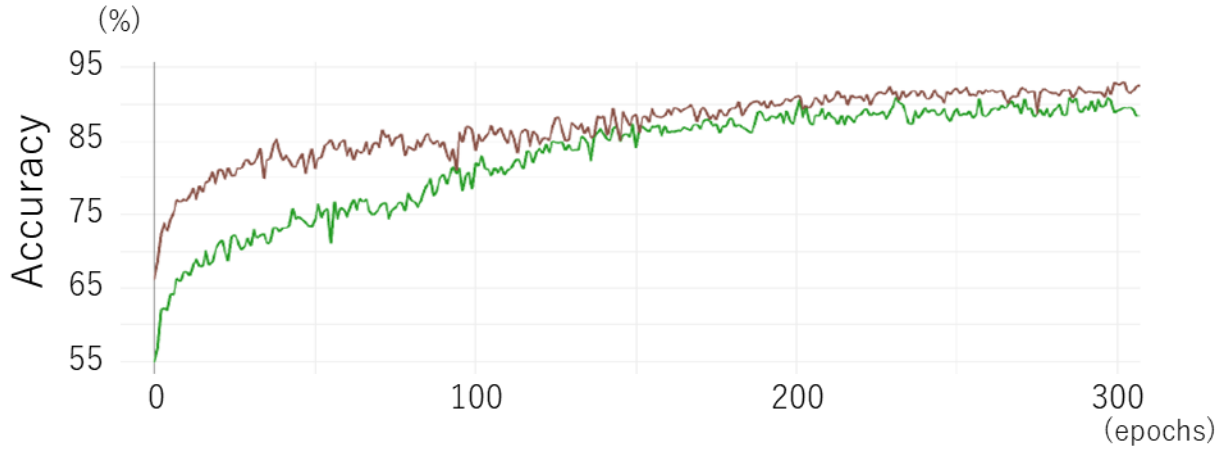

Accuracy for SELF model with pretraining
(Brown, transfer learning)

SELF with pretrained operations	**87%**	**83%**	**93%**

Ishiwata et al, JTCVS Techniques 2024, accepted

Doctors of Thoracic Surgery

Standard EBUS Image Classification

Size	Shape	Margin	Ecogenecity	Central Hilar Structure	Coagulation Necrosis Sign
(a) ≦ 1cm	(c) oval	(e) indistinct	(g) homogeneous	(i) present	(k) present
(b) >1cm	(d) round	(f) distinct	(h) heterogeneous	(j) absent	(l) absent

96% of LNs non-malignant when all four categories determined as benign

Fujiwara T, Yasufuku K et al. Chest. 2010 138(3):641-7

UHN Canada's Hospital

Doctors of Thoracic Surgery

Canada Lymph Node Score

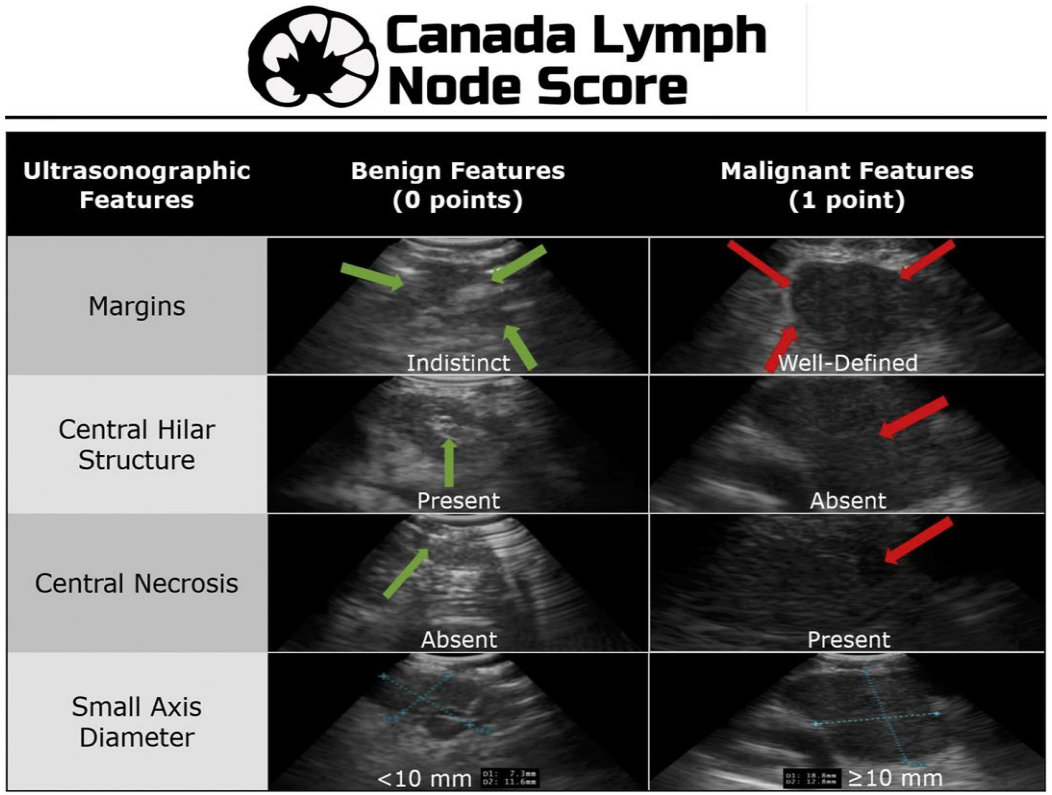

Scores: 0-1 = Low chance of malignancy | 2-4 = High chance of malignancy

- 4-point score demonstrating excellent performance in identifying malignant LNs during EBUS
- Triple-normal LNs
  - cN0 on CT scanning (short axis, < 1 cm)
  - PET scanning (no hypermetabolic activity)
  - EBUS (CLNS, < 2)
- Specificity 60% (95% CI, 51.2%-68.3%)
- NPV 93.1% (95% CI, 85.6%-97.4%)

JTCVS 2020; 159: 2499-507
CHEST 2021; 159(6):2470-2476

UHN Canada's Hospital

Doctors of Thoracic Surgery

Node AI - Device

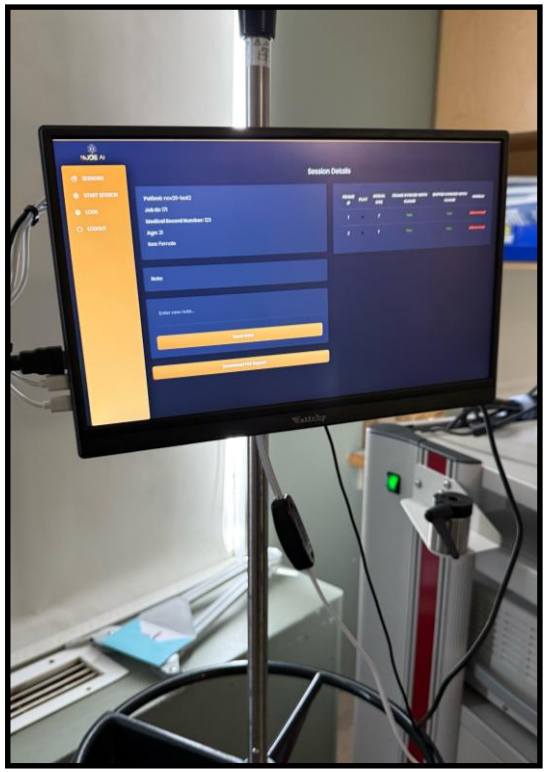

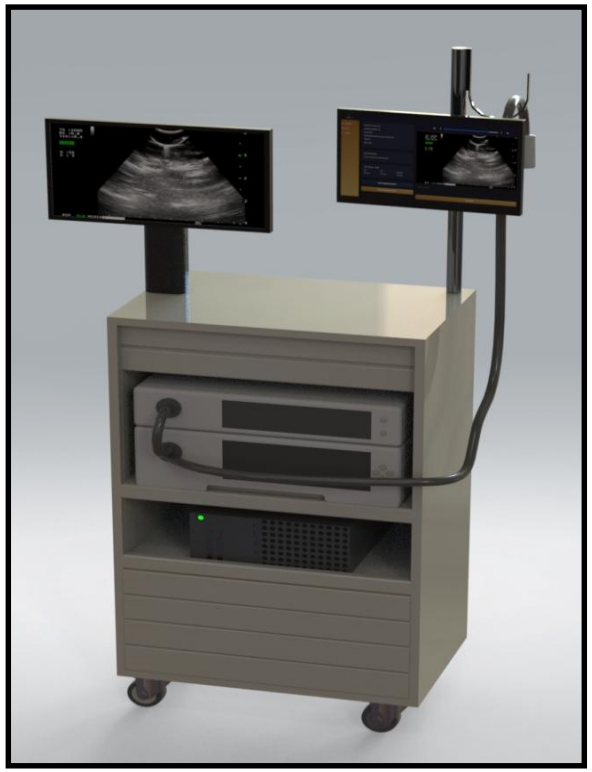

TRL 8

Easy to manufacture and transport

Plug and Play

Currently in human trials

Real-time cloud-based results

FDA Pathway of Class II medical device

UHN Canada's Hospital

Doctors of Thoracic Surgery

Node AI – Clinical Trial



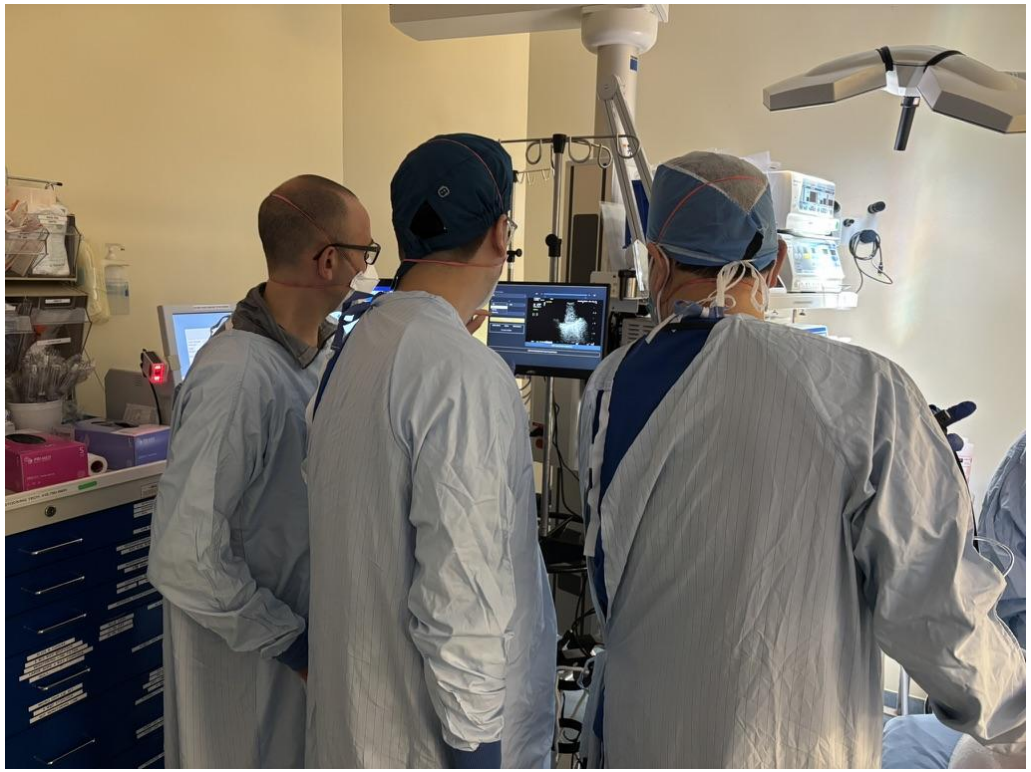

UHN Canada's Hospital

Doctors of Thoracic Surgery®

Innovations in Therapeutics

UHN Canada's Hospital

EBUS-TBNA – from Diagnosis to Therapeutics?

- Access to all LN stations accessible by Med as well as N1 nodes
- Access to centrally located peribronchial tumors
- Real time confirmation of access
- Real time monitoring during therapeutic
- Ease of use

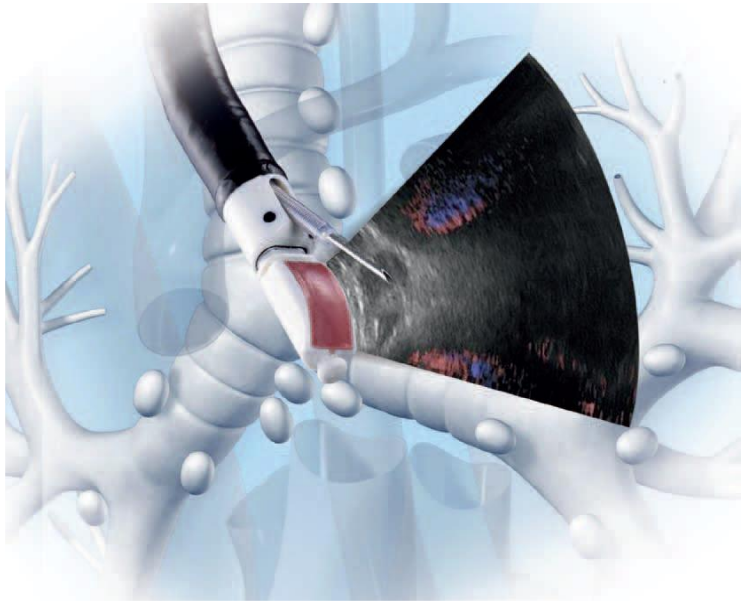

Hanna WC, Yasufuku K. Ther Adv Respir Dis. 2013; 7(2): 111-8

Transbronchial RFA for lung cancer

Active Needle Endoscopic Treatment (ANET)

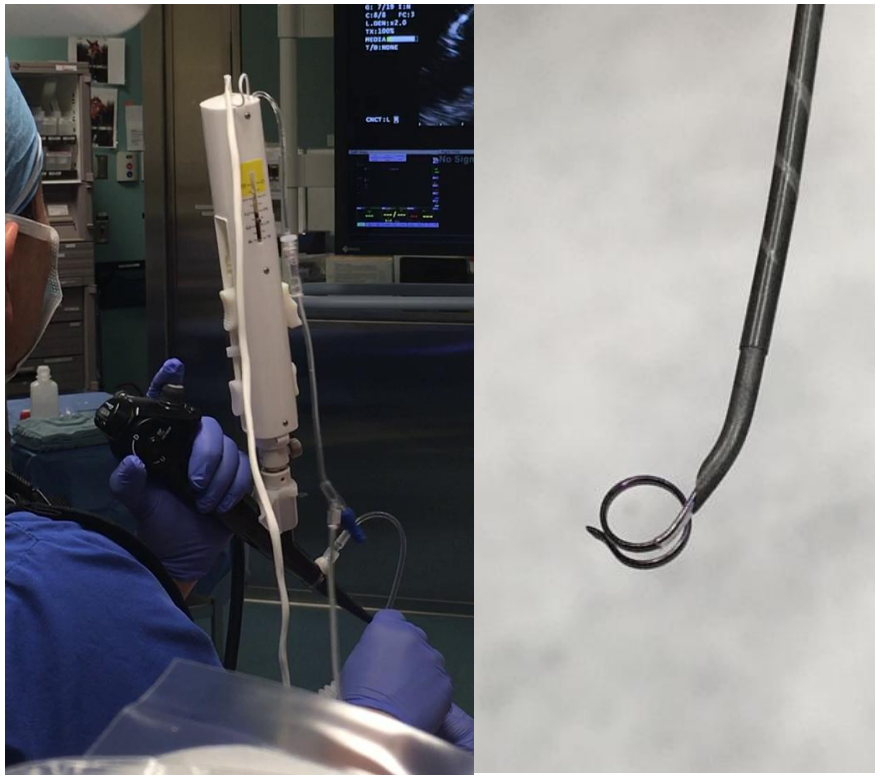

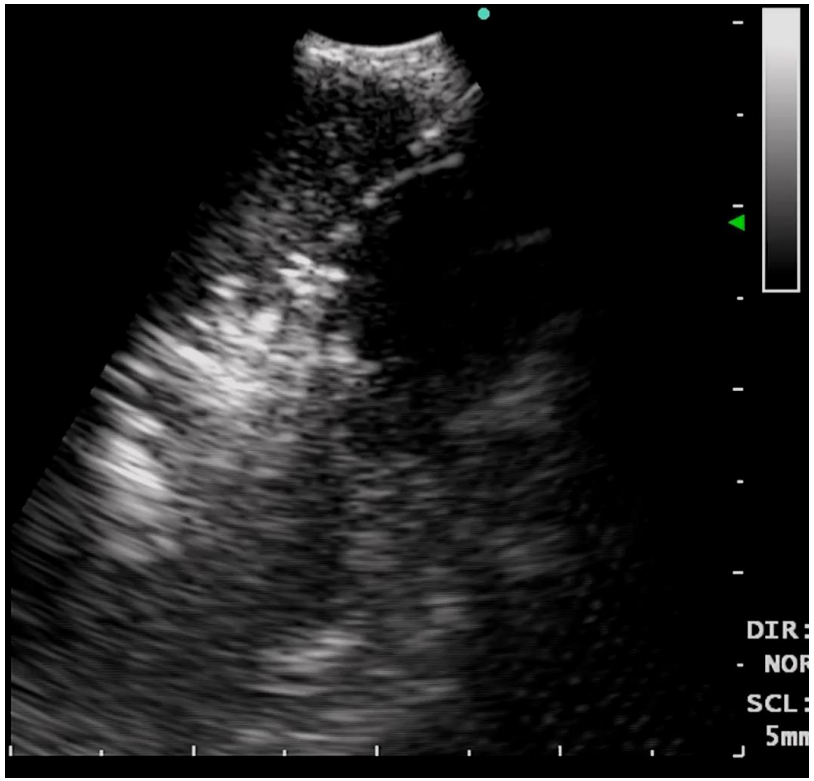

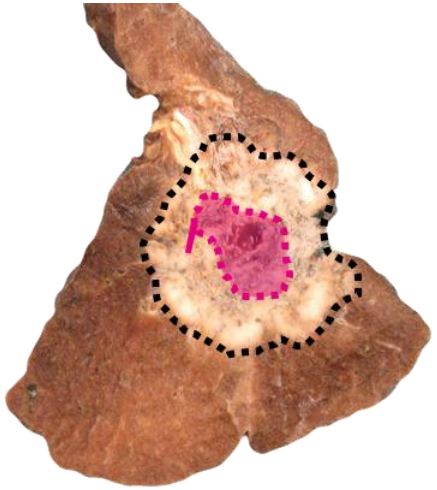

RFA treatment via minimally invasive EBUS approach may represent a therapeutic option for medically inoperable patients with centrally located lung tumors

Ishiwata et al, JTCVS 2022

Doctors of Thoracic Surgery

Direct Tumor Injection – EBUS-TBNI

- EBUS-TBNI Cisplatin for recurrent lung cancer
  - Combination of endobronchial debridement and EBUS-TBNA
  - 1mg/ml Cisplatin 2ml/injection x 4 injections
  - Repeated procedures (total 3)
  - Good local control but distant recurrence

- Retrospective review
  - 27/38 lesions – partial or complete remission (71%)
  - Measures of tumor density are more highly associated with response

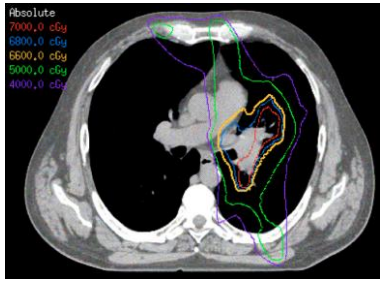



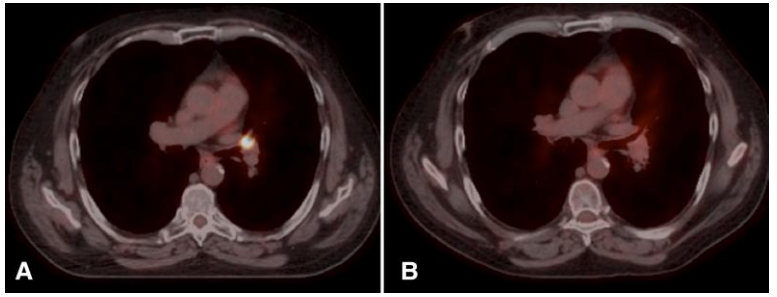

CM Kinsey et al. Ann Am Thorac Soc 2015; 101–104
CM Kinsey et al. J Thorac Dis 2020; 12(9): 4825-4832

UHN Canada's Hospital

Summary

- EBUS-TBNA has become the standard of care for invasive mediastinal lymph node staging of lung cancer
- New CP-EBUS systems are in development which may allow for more precise assessment of N1 lymph nodes and possibly greater access to intrapulmonary lesions that are normally inaccessible to the conventional CP-EBUS
- New imaging analysis and therapeutics during EBUS are on the horizon

Division of Thoracic Surgery, Toronto General Hospital







Kazuhiro Yasufuku, MD, PhD, FRCSC
kazuhiro.yasufuku@uhn.ca