Complex Airway Reconstruction

Benign Disease

- ***Pathophysiology / Indications***
- ***Resections / Reconstructions***
- ***Predictors of outcome***
- ***Research***



Paulo F. G. Cardoso M.D., M.Sc. Ph.D.
Associate Professor & Senior Researcher
Department of Cardiopneumology, Division of Thoracic Surgery
Heart Institute, Hospital das Clinicas (InCor-HCFMUSP)
Faculty of Medicine of the University of Sao Paulo
Sao Paulo - Brazil

Complex Airway Reconstruction

Benign Disease



Disclosure - Declaration of Conflict of Interest

- The speaker received grants from FAPESP* related to the following research projects mentioned in this presentation:
  - *Contact diode laser for laryngofissure (grant # 15/17847-1).*
  - *Tracheal tissue engineering (grants # 17/19806-6; 21/03555-0).*
  - *Morphology and markers in early tracheal stenosis (grant # 23/01788-2).*

(*) FAPESP: Foundation for Research Support of the State of Sao Paulo, Brazil

Complex Airway Reconstruction

Benign Disease

- **Historic note – Airway reconstruction**
  - Key contributions
    - Resection / reconstruction
      - Grillo (1964)
        - » Limits / techniques
      - Pearson (1975)
        - » Subglottic resection
          - Laryngeal function

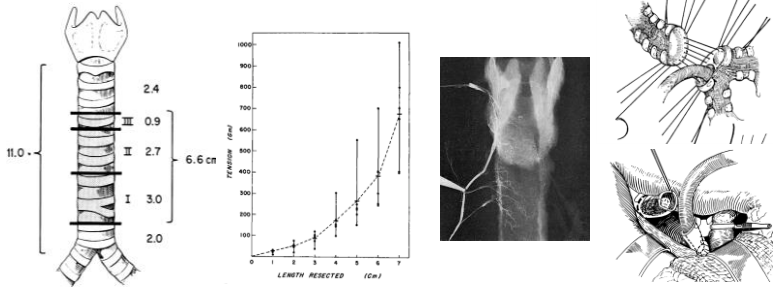



Hermes C. Grillo
1923-2006
Mass.General Hospital
(Boston, EUA)

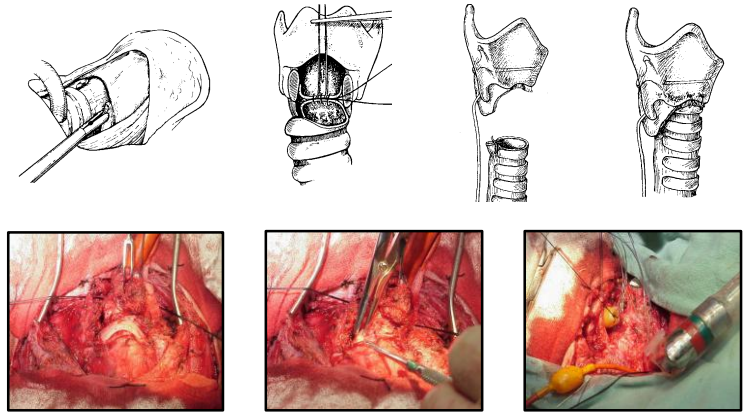



Frederick G. Pearson
1926-2016
Toronto General Hospital
(Toronto, Canada)

Grillo. J Thorac Cardiovasc Surg 1964;48:741
Pearson. J Thorac Cardiovasc Surg 1975;70:806

Complex Airway Reconstruction

Benign Disease

- **Definition – Complex central airway disease**
  1. Long-segment stenosis (> 40mm)

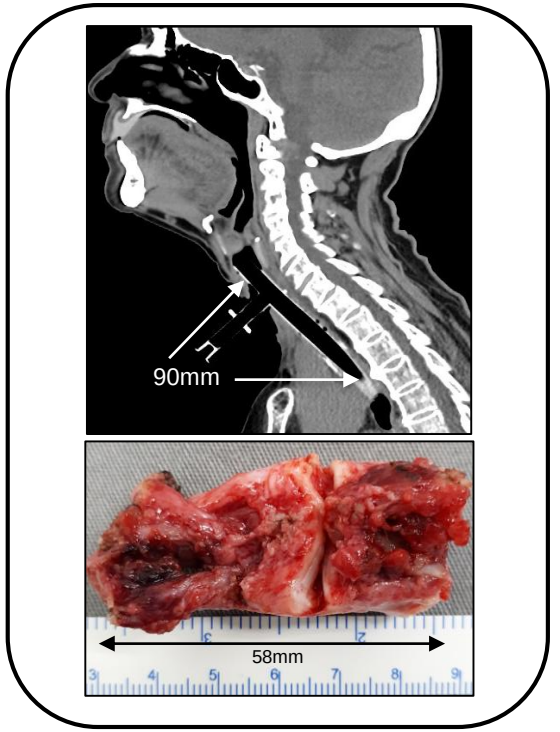

Complex Airway Reconstruction

Benign Disease

- **Definition – Complex central airway disease**
  1. Long-segment stenosis (> 40mm)
  2. Multilevel disease

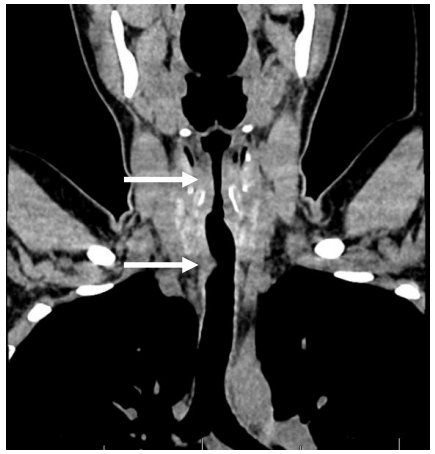

Complex Airway Reconstruction

Benign Disease

- **Definition – Complex central airway disease**
  1. Long-segment stenosis (> 40mm)
  2. Multilevel disease
  3. Laryngotracheal / tracheal-bronchial



Complex Airway Reconstruction

Benign Disease

- **Definition – Complex central airway disease**
  1. Long-segment stenosis (> 40mm)
  2. Multilevel disease
  3. Laryngotracheal / tracheal-bronchial
  4. Previous resection / long-term stenting

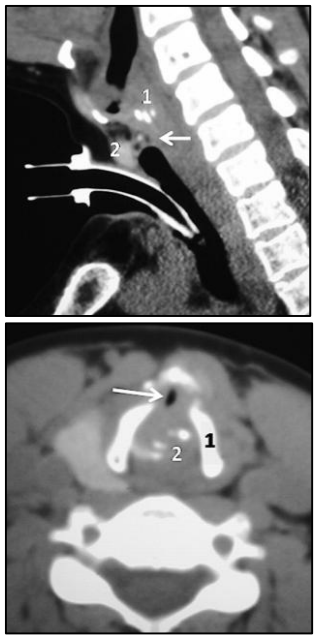

Complex Airway Reconstruction

Benign Disease

- **Definition – Complex central airway disease**
  1. Long-segment stenosis (> 40mm)
  2. Multilevel disease
  3. Laryngotracheal / tracheal-bronchial
  4. Previous resection / long-term stenting
  5. Extensive inflammation / fibrosis

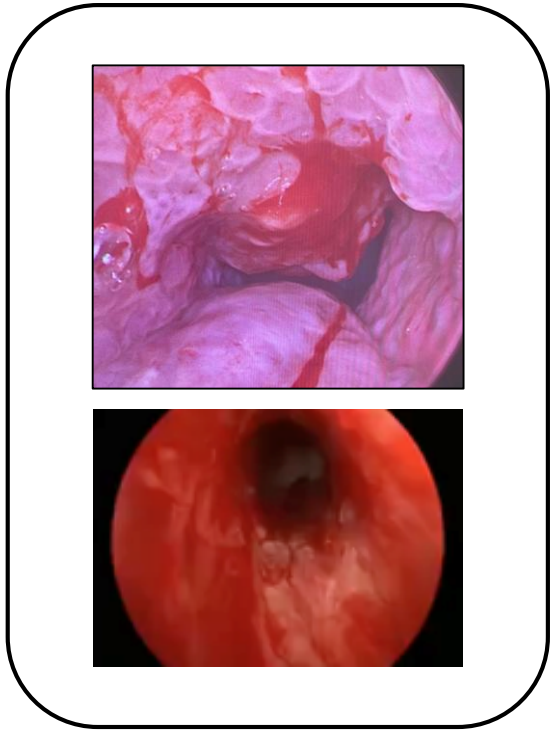

Complex Airway Reconstruction

Benign Disease

- **Definition – Complex central airway disease**
  1. Long-segment stenosis (> 40mm)
  2. Multilevel disease
  3. Laryngotracheal / tracheal-bronchial
  4. Previous resection / long-term stenting
  5. Extensive inflammation / fibrosis
  6. Combined airway & vascular (TIF) *

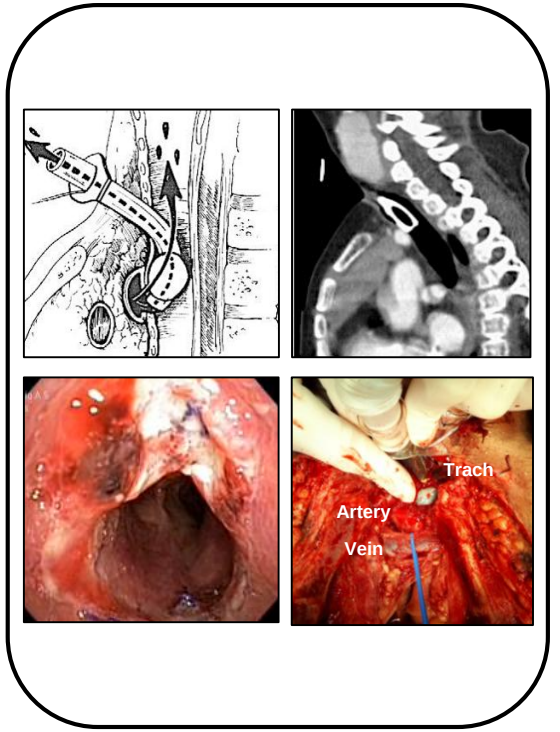

(*) ***T**racheo**I**nnominate **F**istula*

Complex Airway Reconstruction

Benign Disease

- **Definition – Complex central airway disease**
  1. Long-segment stenosis (> 40mm)
  2. Multilevel disease
  3. Laryngotracheal / tracheal-bronchial
  4. Previous resection / long-term stenting
  5. Extensive inflammation / fibrosis
  6. Combined airway & vascular (TIF) *
  7. Combined airway & esophageal (TEF) **

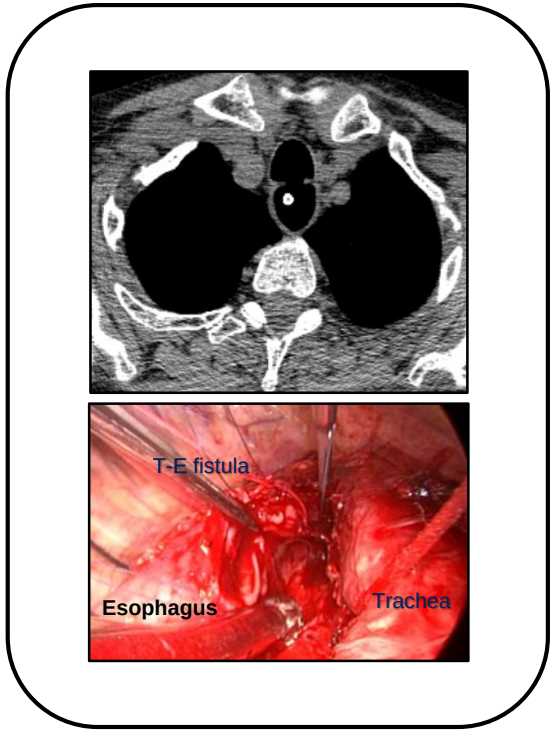

*(**) Acquired **T**racheo**E**sophageal **F**istula*

Complex Airway Reconstruction

Benign Disease

- **Acquired benign causes**
  - Iatrogenic → Post-intubation / tracheostomy
  - Idiopathic → Subglottic
  - Inflammatory → Polyangeiitis (Wegener's), polychondritis
  - Infeccious → TB, fungal
  - Airway burn → Inhalation injury
  - Deposit → Amiloidosis

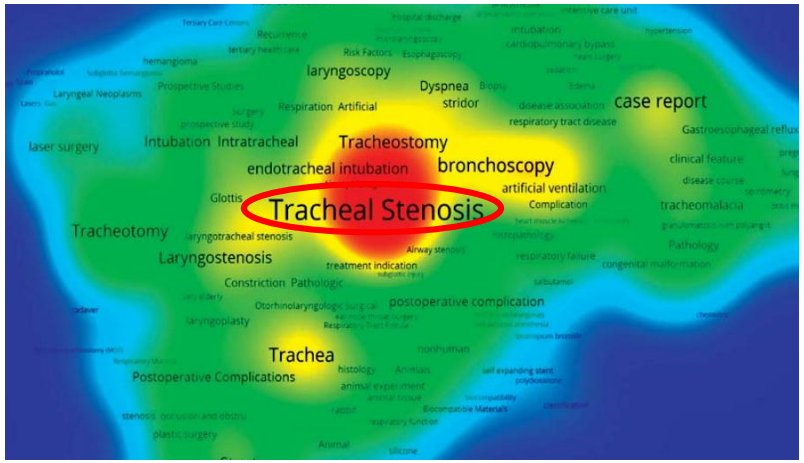

Density map
(keywords–*SCOPUS*)

Farzanegan. Arch Iran Med 2017;20:598

Complex Airway Reconstruction

Benign Disease

- **Acquired benign – Iatrogenic**
  - Post-intubation tracheal stenosis (PITS) ⇨ 6.0% – 20%
  - Post-tracheostomy tracheal stenosis (PTTS) ⇨ 0.6% – 21%
  - Mechanical ventilation
    - Prospective – UK (N=654)*
      - 389 survivors ⇩

Stenosis (6-12 months) = 3,1%
Lesser degrees = 4.6%

Nouraei. J Intens Care Soc 2009;10:229
(*) Esteller-Moré. Eur Arch Otorhinolaryngol 2005;262:880

Complex Airway Reconstruction

Benign Disease

- **Acquired benign – Iatrogenic**
  - Post-intubation – PITS, PTTS (+ freq.)
    - Sao Paulo, Brazil - Population 11,9 million

3.8 million automobiles
1.1 million motorcycles

- Prolonged intubation/trach (trauma, other)
- Inadequate airway care (ICUs)
- Cricothyroidotomy >> Tracheostomy

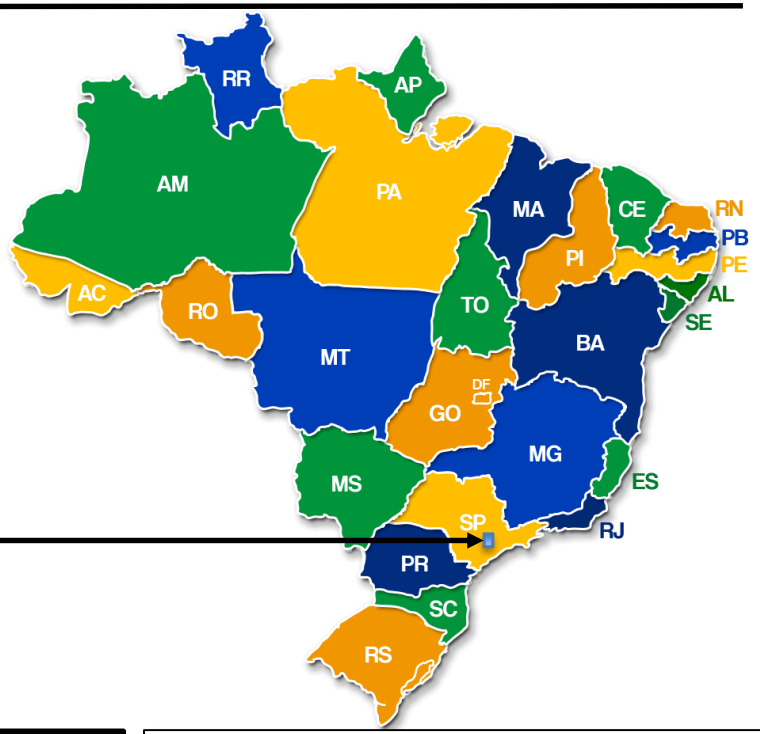

COVID-19
SARS-CoV-2

Airway stenosis
Subglottic / Tracheal / Laringotracheal

Long-term intubation and high rate of tracheostomy in COVID-19 patients might determine an unprecedented increase of airway stenoses: a call to action from the European Laryngological Society

Cesare Piazza[1,2] · Marta Filauro[3,4,5] · Frederik G. Dikkers[6] · S. A. Reza Nouraei[7] · Kishore Sandu[8] · Christian Sittel[9] · Milan R. Amin[10] · Guillermo Campos[11] · Hans E. Eckel[12] · Giorgio Peretti[3]

Piazza C. Arch Oto-Rhino-Laryngol 2021;278:1

https://www.detran.sp.gov.br/detransp?id=frota_dados
https://cidades.ibge.gov.br/brasil/sp/sao-paulo/panorama

Complex Airway Reconstruction

Benign Disease

- **Pathophysiology – Balloon pressure**
  - PITS (iatrogenic) ≈ 85% - 90% cases
    - Normal mucosal capillary pressure >> 20 – 30 mmHg

- **Pressure > 30 mmHg**
- **Secretions**
- **Local tissue response**

→ **Ischemia**
→ **Infection**
→ **Inflammation**

→ **Circumferential scarring**
Stenosis



Tracheal mucosal / cartilage exposure
(prolonged intubation) *

Cooper. Ann Surg 1969;169:334
(*) Cardoso PFG – personal archive

Complex Airway Reconstruction

Benign Disease

- **Pathophysiology – Mucosal ischemia**
  - Chondritis >> Local inflammation >> Fibrosis
    - New concepts

Mechanical stress

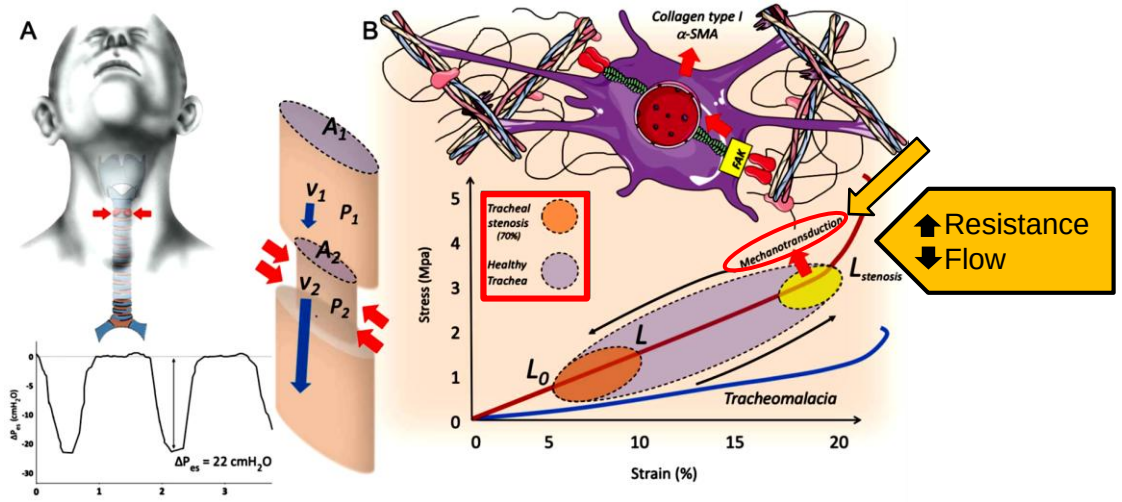

Local microbiota

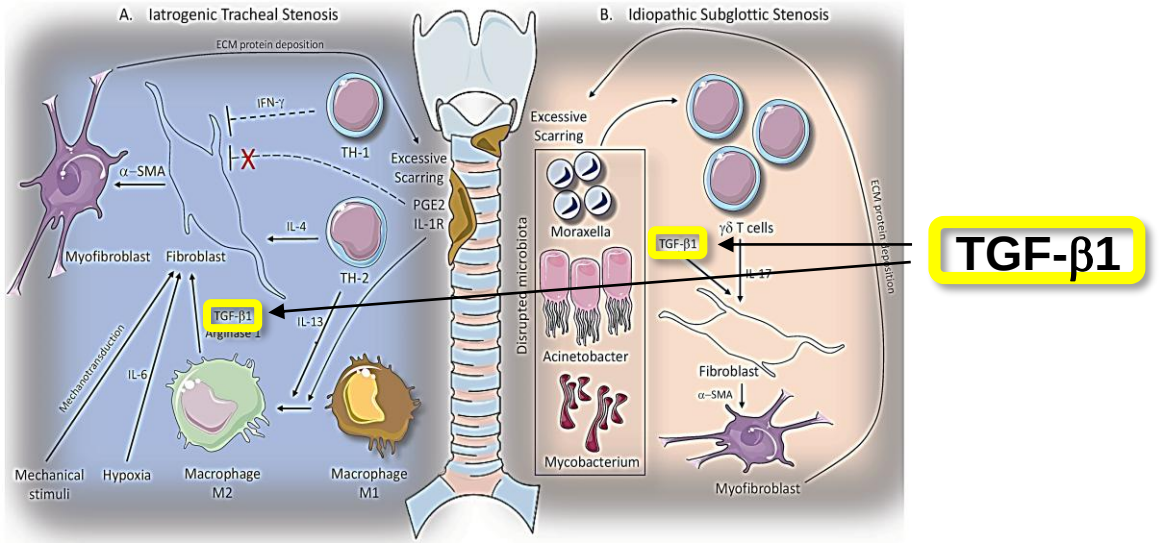

Marchioni. Int J Mol Sci 2022;23:2421
Gelbard. Laryngoscope 2017;127:179

Complex Airway Reconstruction

Benign Disease

- **Pathophysiology – GER & microaspiration**
  - Thoracoabdominal pressure gradient
    - Cytokine expression (**TGF-β**)

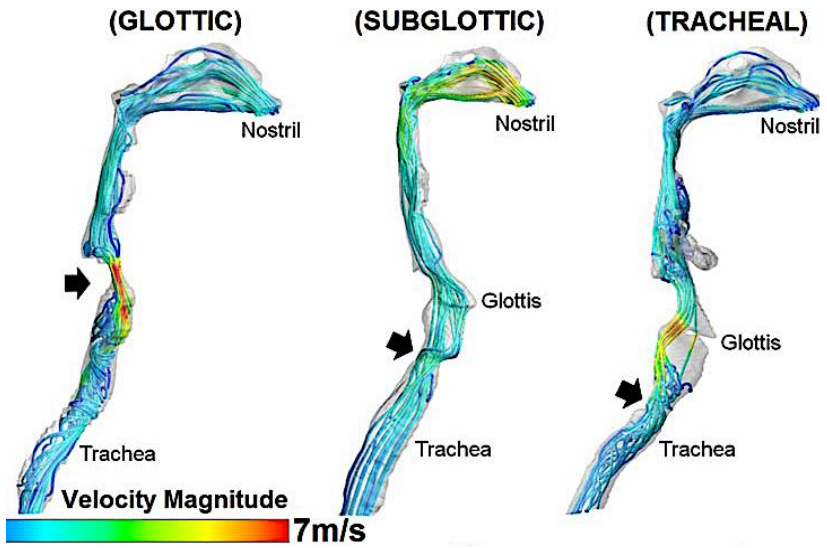

CFD – Computational Fluid Dynamics

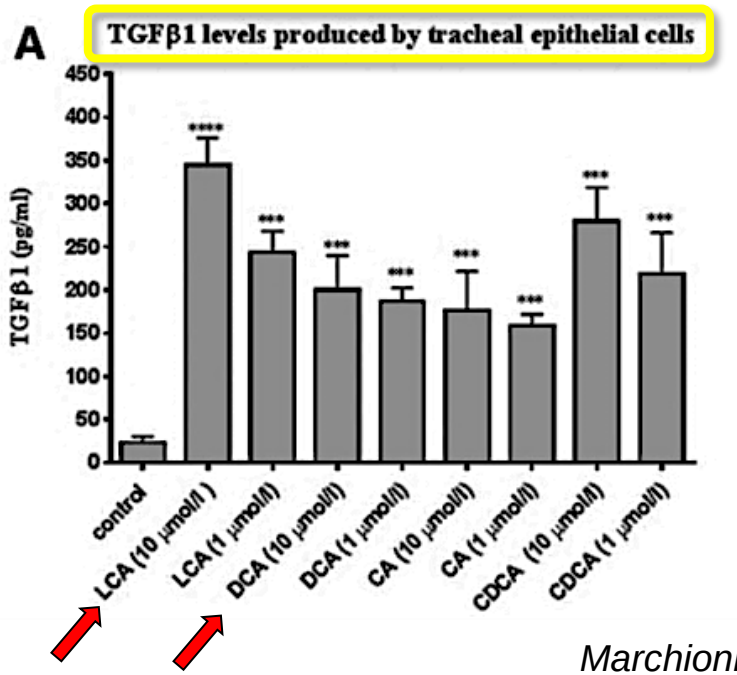

Marchioni. Int J Mol Sci 2022;23:2421
Aldhahrani. Laryngoscope 2018;128:2029

Complex Airway Reconstruction

Benign Disease

Bianchi et al Thoracic

Impact of fundoplication for gastroesophageal reflux in the outcome of benign tracheal stenosis

Edno Tales Bianchi, MD,[a] Paulo Francisco Guerreiro Cardoso, MD, MSc, PhD,[b] Helio Minamoto, MD, PhD,[b] Benoit Jacques Bibas, MD,[b] Michele Salati, MD, PhD,[c] and Paulo Manuel Pego-Fernandes, MD, PhD,[b] The Surgery of the Digestive Tract Group[d]

- **Pathophysiology – GER control**
  - Esophageal pH study ; Retrospective / PSM

• Fundoplication vs. Omeprazole (80mg/d)

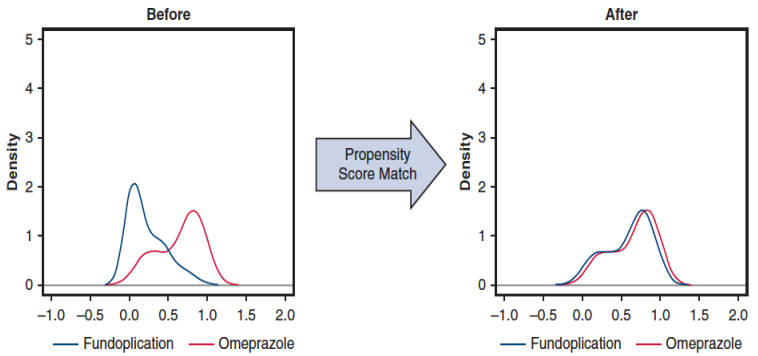

	Odds Ratio	Standard Error	95% Confidence Interval	P
Intercept	-	0.52	-	.31
Fundoplication	5.31	0.79	2.41 - 11.7	.03
Hypotonic LES	0.44	0.82	0.19 - 0.99	.31

• Fundoplication vs. Observation (no GER)

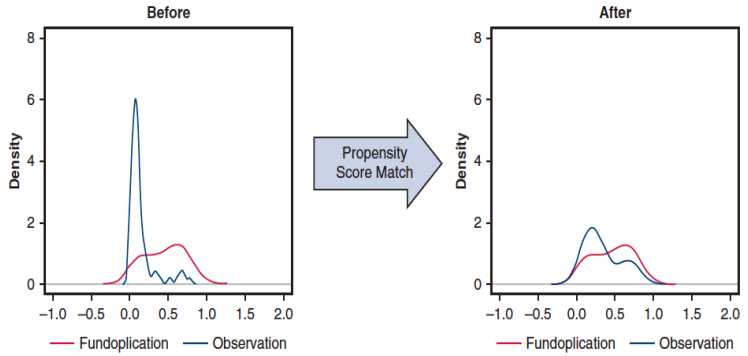

	Odds Ratio	Standard Error	95% Confidence Interval	P
Intercept	-	0.5	-	.5
Fundoplication	1	0.75	0.47 - 2.11	.99
Hypotonic L.E.S.	2.14	0.83	0.93 - 4.93	.36

• Observation (no GER) vs. Omeprazole (80mg/d)

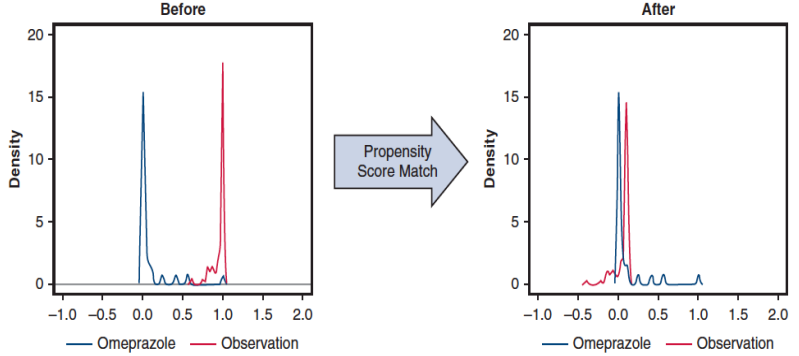

	Odds Ratio	Standard Error	95% Confidence Interval	P
Intercept	-	1.69	-	.91
Observation	3.54	0.56	2.02 - 6.19	.02
BMI	0.98	0.06	0.92 - 1.04	.71

Fundoplication

Better chance of stenosis resolution (2 yrs)

Bianchi, Cardoso, Minamoto et al. J Thorac Cardiovasc Surg 2019;158:1698

Complex Airway Reconstruction

Benign Disease

- **Pathophysiology – Laryngotracheal stenosis**
  - Collagen type I / Citokines
    - Excessive ECM *

–12x Collagen type I

–4x IL-4

–2.5x Interferon-γ

–2x **TGF-β**

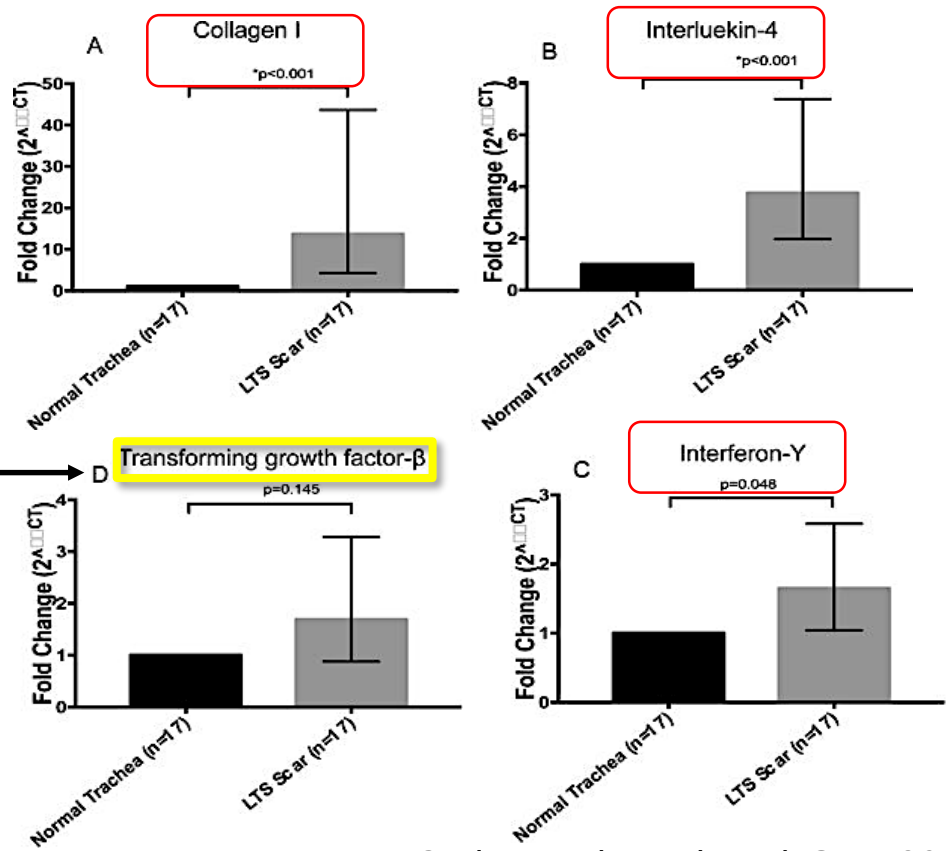

Motz. Otolaryngol Head Neck Surg 2017;157:466

*(*) **E**xtra**C**ellular **M**atrix*

Complex Airway Reconstruction

Benign Disease

- **Resection – Indications**
  - Symptomatic stenosis >> Dyspnea
  - Mature fibrosis >> No active inflammation
  - Recurrent stenosis >> Failed repeated dilatations
  - Unstable airway >> Permanent structural damage
  - Long-term stenting >> T-tube, stents

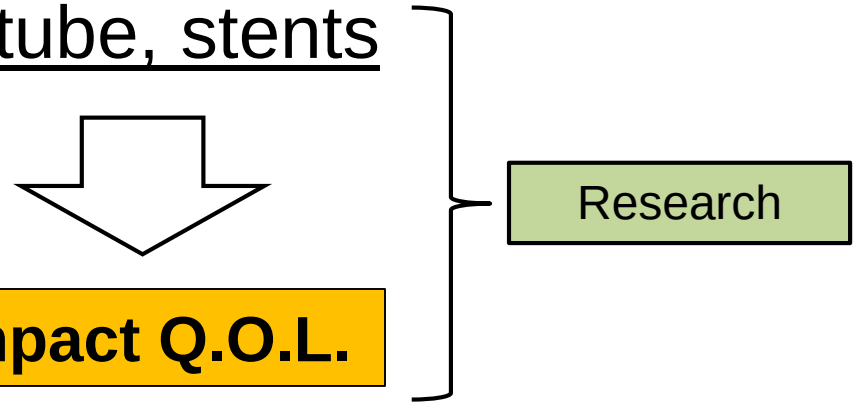

Complex Airway Reconstruction

Benign Disease

- **Resection – Indications**
  - Long-term stenting / tracheostomy
    - SF36 (poor Q.O.L.)

Health-related quality of life evaluation in patients with non-surgical benign tracheal stenosis

Benoit Jacques Bibas[1], Paulo Francisco Guerreiro Cardoso[1], Michele Salati[2], Helio Minamoto[1], Mauro Federico Luiz Tamagno[1], Ricardo Mingarini Terra[1], Paulo Manuel Pêgo-Fernandes[1]

[1]Division of Thoracic Surgery, Heart Institute (InCor), Hospital das Clínicas da Faculdade de Medicina da Universidade de São Paulo, São Paulo, Brazil; [2]Unit of Thoracic Surgery, AOU Ospedali Riuniti di Ancona, Ancona, Italy

Quality-of-life evaluation in patients with laryngotracheal diseases

Benoit Jacques Bibas, Paulo Francisco Guerreiro Cardoso, Helio Minamoto, Paulo Manoel Pêgo-Fernandes

Division of Thoracic Surgery, Heart Institute (InCor), Hospital das Clínicas da Faculdade de Medicina da Universidade de São Paulo, São Paulo, Brazil

Silicone prosthesis

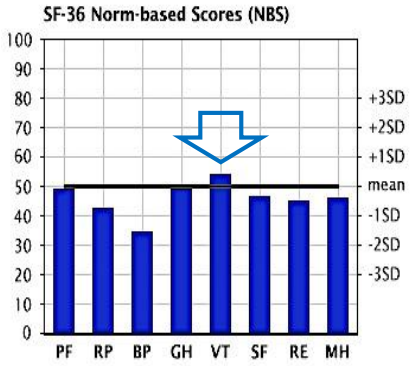

T-tube

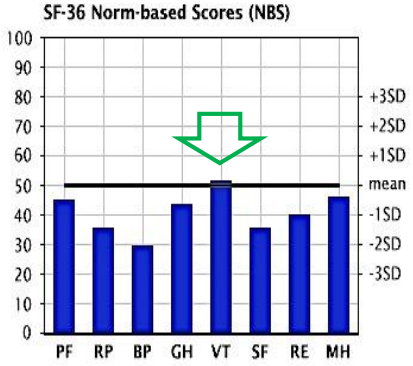

Tracheostomy

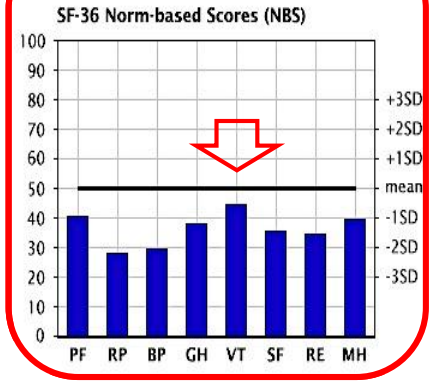

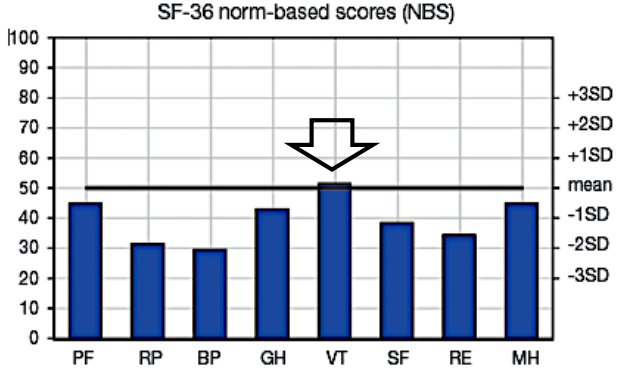

Table 4 Multivariate regression analysis for the PCS

Parameter	Coefficient	95% CI	P
Total treatment time, months	1.76	0.38 to 3.14	0.013
Type of tracheal device	7.44	−0.32 to 15.2	0.06

Bibas, Cardoso, Minamoto. J Thorac Dis 2018;10:4782
Bibas, Cardoso, Minamoto. Transl Cancer Res 2020;9:2099

Complex Airway Reconstruction

Benign Disease


Artificial Organs

MAIN TEXT ARTICLE

Artificial Organs homepage

Treatment of tracheal stenosis with extracorporeal membrane oxygenation support in infants and newborns

Flavio Pola dos Reis, Helio Minamoto, Benoit Jacques Bibas, Fabio Eiti Nishibe Minamoto, Paulo Francisco Guerreiro Cardoso, Luiz Fernando Caneo, Paulo Manuel Pêgo-Fernandes

- **Resection – Cornerstones**
  - Segmental vascular supply
  - Length of resection (< 50%)
  - Meticulous anastomotic technique
  - Cross-field ventilation vs. ECMO
  - Release maneuvers
  - “Guardian stitch”

    …*no more*…

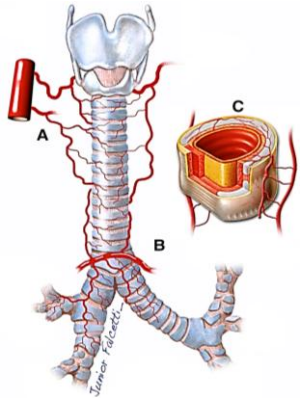

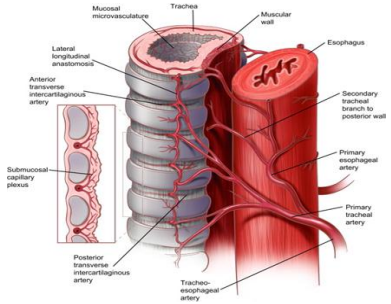

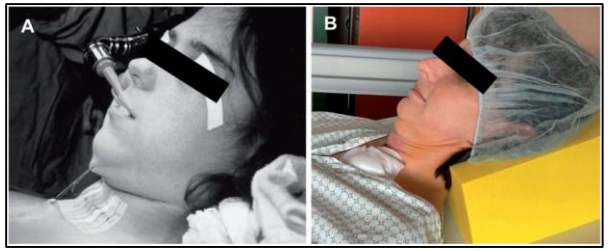

Table 4: Anastomosis-related complications and findings during the hospital stay and 3 months after surgery

	Total study cohort (n = 165)	
Early anastomotic complication (in-hospital)		
Partial necrosis	2	1.2
Traumatic rupture	1	0.6
Dehiscence	0	0
Re-stenosis	0	0

Schweiger. Eur J Cardiothorac Surg 2021;60:420
Pola-dos-Reis. Artif Organs.2021;45:748
Grillo. Surg Gynecol Obstet 1966;123:99

Complex Airway Reconstruction

Benign Disease

- **Resection & Reconstruction**
  - Type of resection
    - Location + Extension

TYPE OF RESECTION (anatomic location)	**DISTANCE** (stenosis >> vocal folds)
Laryngotracheal resection	≤ 5 mm
Subglottic resection	6 mm - 10 mm
Cervical tracheoplasty	≥ 11 mm
Mediastinal tracheoplasty	Below mediastinal boundary *
Intrathoracic tracheobronchoplasty	

(*) CT scan (sagital): Line T1 >> manubrium

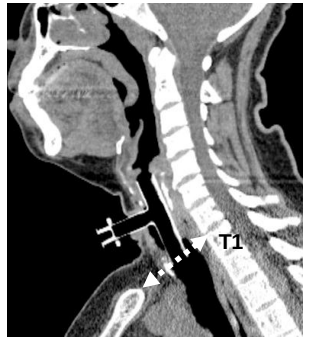

Complex Airway Reconstruction

Benign Disease

- **Resection & Reconstruction**
  - Planning the approach
    - Upper 3rd >> Cervicotomy
    - Middle 3rd >> Cervicotomy+/-sternotomy
    - Lower 3rd >> Right thoracotomy/sternotomy

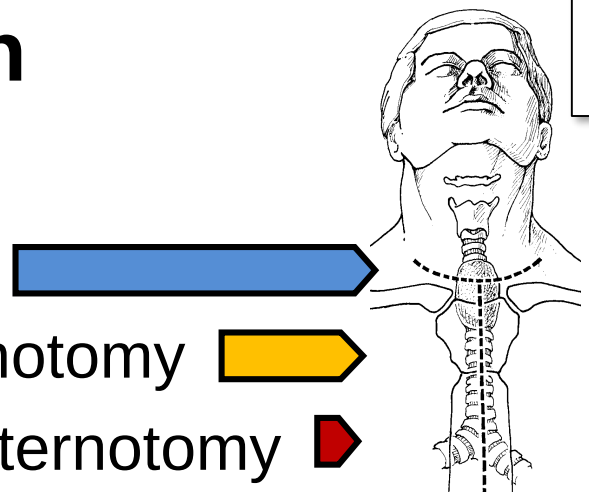

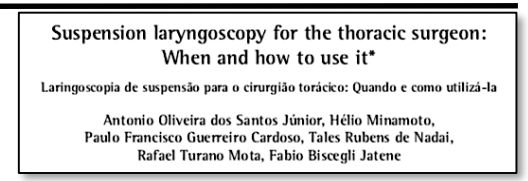
Suspension laryngoscopy for the thoracic surgeon: When and how to use it*

Laringoscopia de suspensão para o cirurgião torácico: Quando e como utilizá-la

Antonio Oliveira dos Santos Júnior, Hélio Minamoto, Paulo Francisco Guerreiro Cardoso, Tales Rubens de Nadai, Rafael Turano Mota, Fabio Biscegli Jatene

  - Assessment >> Type & Length of resection
    - CT scan + airway endoscopy (suspension laryngoscopy / bronchoscopy)

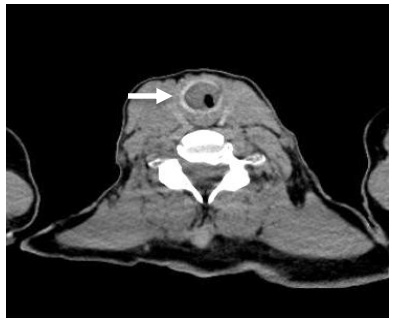

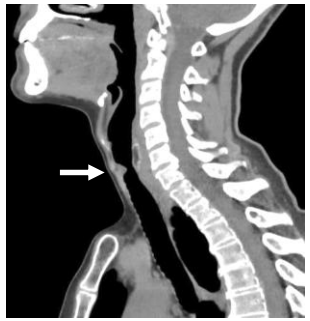

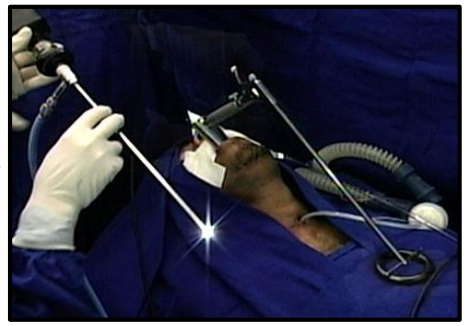



Santos Jr. J Bras Pneumol 2011;37:238

Complex Airway Reconstruction

Benign Disease


General Thoracic Surgery Terra

Laryngeal split and rib cartilage interpositional grafting: Treatment option for glottic/subglottic stenosis in adults

Ricardo Mingarini Terra, MD, Hélio Minamoto, MD, Felipe Carneiro, MD, Paulo Manuel Pego–Fernandes, MD, and Fábio Biscegli Jatene, MD

- **Resection & Reconstruction**
  - Laryngeal split & costal cartilage interposition (3-step procedure)

Step 1
Laryngofissure + solid stent + tracheostomy

6 wks

Step 2
Removal stent + T-tube placement

1 - 2 yrs

Step 3
Decannulation



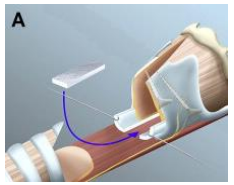

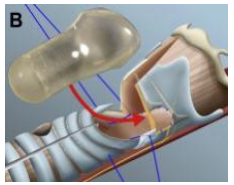

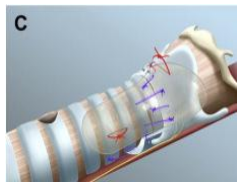



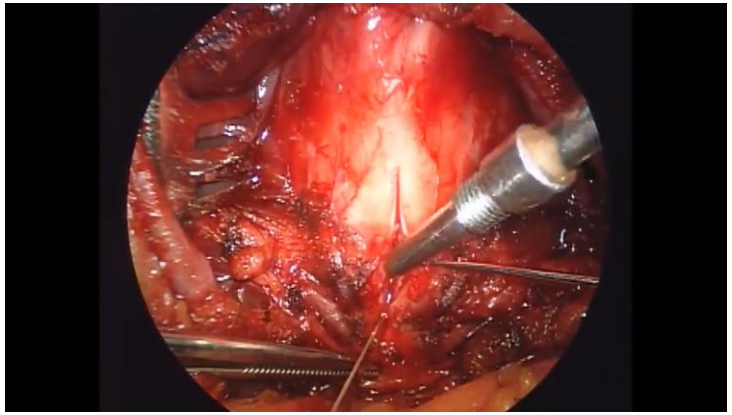

InCor-HFMUSP – Trachea and Airway Surgery Group

Complex procedure
(multiple steps / 2-3 years)

Research

Terra. J Thorac Cardiovasc Surg 2009;137:818

Complex Airway Reconstruction

Benign Disease

Decannulation in Tracheal Stenosis Deemed Inoperable Is Possible After Long-Term Airway Stenting

Ricardo Mingarini Terra, MD, PhD, Benoit Jacques Bibas, MD, Helio Minamoto, MD, PhD, Daniel Reis Waisberg, MD, Mauro Federico Luis Tamagno, MD, Miguel Lia Tedde, MD, PhD, Paulo Manuel Pêgo-Fernandes, MD, PhD, and Fabio Biscegli Jatene, MD, PhD

Thoracic Surgery Department, Heart Institute (InCor), Hospital das Clínicas da Faculdade de Medicina da Universidade de São Paulo, São Paulo, Brazil

- **Resection & Reconstruction**
  - Laryngeal split & costal cartilage interposition
    - Criteria for decannulation

Before laryngeal split

High stenosis

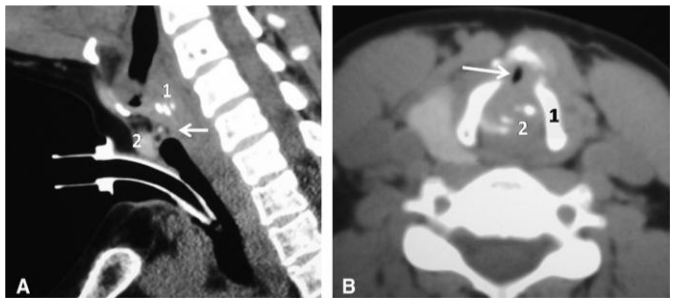

Before T tube removal

2-3 years after laryngeal split

Ant./posterior grafts

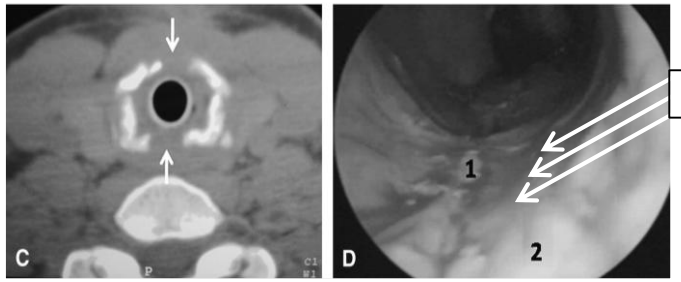

Smooth mucosal lining

After T tube removal

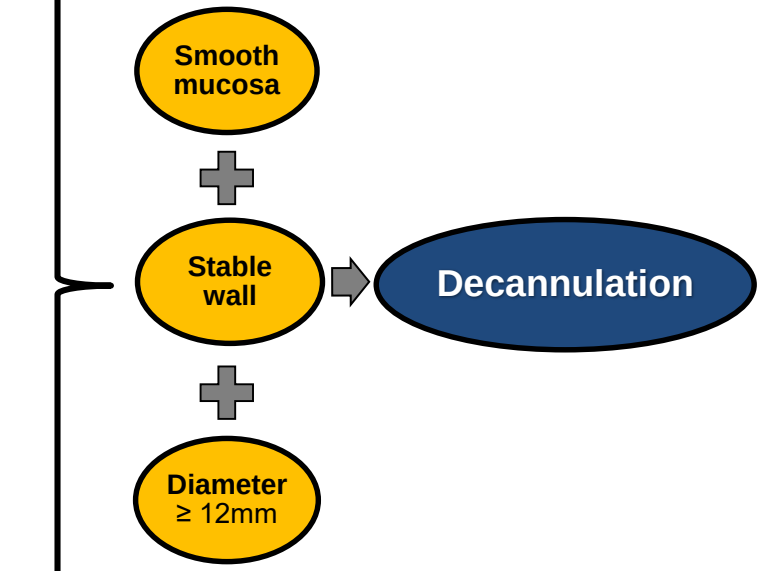

Terra. Ann Thorac Surg 2013;95:440
Terra. J Thorac Cardiovasc Surg 2009;137:818

Complex Airway Reconstruction
Benign Disease

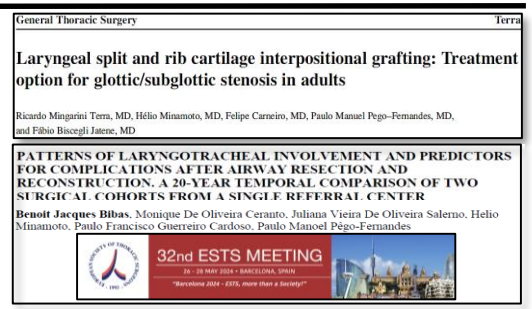
General Thoracic Surgery Terra

Laryngeal split and rib cartilage interpositional grafting: Treatment option for glottic/subglottic stenosis in adults

Ricardo Mingarini Terra, MD, Hélio Minamoto, MD, Felipe Carneiro, MD, Paulo Manuel Pego–Fernandes, MD, and Fábio Biscegli Jatene, MD

PATTERNS OF LARYNGOTRACHEAL INVOLVEMENT AND PREDICTORS FOR COMPLICATIONS AFTER AIRWAY RESECTION AND RECONSTRUCTION. A 20-YEAR TEMPORAL COMPARISON OF TWO SURGICAL COHORTS FROM A SINGLE REFERRAL CENTER

Benoit Jacques Bibas, Monique De Oliveira Ceranto, Juliana Vieira De Oliveira Salerno, Helio Minamoto, Paulo Francisco Guerreiro Cardoso, Paulo Manoel Pêgo-Fernandes

32nd ESTS MEETING

- **Resection & Reconstruction**
  - Laryngeal split & costal cartilage interposition
    - Results
      - Outcomes

TABLE 2. Outcomes and complications

	LTR	LTR/CTR	Total
n	14	6	20
Complications			
Infection	2	1	3 (15%)
Subcutaneous emphysema	1	1	2 (10%)
Bleeding	1	0	1 (5%)
Dysphonia	4	1	5 (25%)
Tracheocutaneous fistula	3	1	4 (20%)
Time			
Laryngeal stent (d)	57.8	60.2	58.4 (14-134)
T-tube (mo)	23.5	21.2	22.5 (2-49)
Until total decannulation (mo)	25.2	20.3	23.4 (4-55)
Follow-up after decannulation (mo)	29	27	28
Success rate			
Decannulation	11	5	16 (80%)

LTR, Standard laryngotracheal reconstruction; *LTR/CTR*, laryngotracheal reconstruction associated with cricotracheal resection.

- Comparison
  - Periods: 2002-09 vs. 2012-23

Type of surgery	2002-09 (n = 94)	2012-23 (n = 113)	
End-to-end tracheal anastomosis	55.3%	43.9%	***0.039***
Crico-tracheal anastomosis	25.5%	45.6%	
Laryngo-tracheal anastomosis	19.2%	10.5%	

Predictor of anastomotic complications
OR 4.86 [95% CI 0.94-25], p=0.05

Terra. J Thorac Cardiovasc Surg 2009;137:818
32nd ESTS Meeting – Barcelona, Spain, May 2024

Complex Airway Reconstruction

Benign Disease

- **Resection & Reconstruction**
  - Laryngeal split & costal cartilage interposition

Vienna

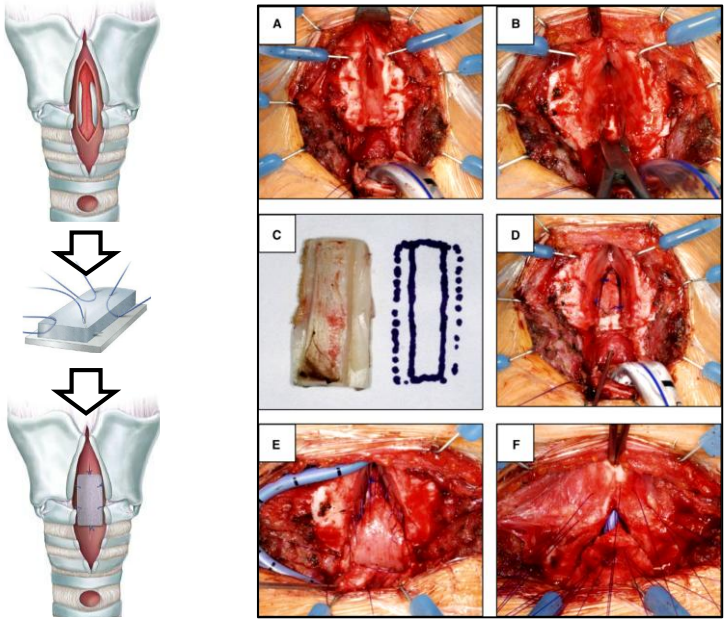

Hoetzenecker. J Thorac Cardiovasc Surg 2016;152:1008

Rome

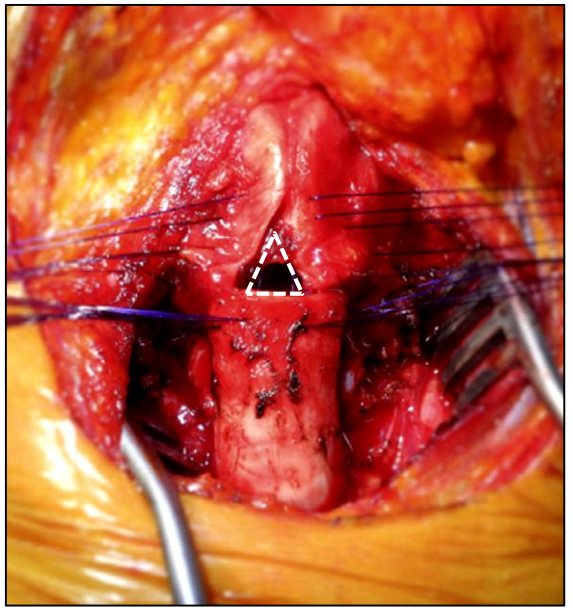

Maurizi. J Thorac Cardiovasc Surg 2021;161:845

Complex Airway Reconstruction

Benign Disease

- **Resection & Reconstruction**
  - Long-segment subglottic stenosis
    - Subglottic resection & Suprahyoid release



Pre-op.



InCor-HFMUSP – Trachea and Airway Surgery Group



Post-op.

Pearson. J Thorac Cardiovasc Surg 1975;70:806
Montgomery. Ann Otol Rhinol Laryngol 1968;77:534

Complex Airway Reconstruction

Benign Disease

- **Resection & Reconstruction**
  - Subglottic stenosis with posterior mucosal thickening
    - Subglottic resection & Posterior mucosal flap

- Thyrotracheal anastomosis *(Pearson-Grillo)*
- Tailored Cricoplasty *(Liberman-Mathisen)*

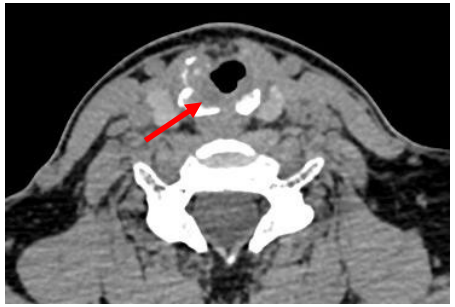

Pre-op.

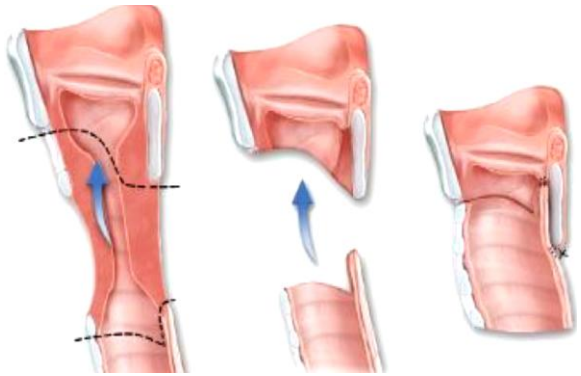

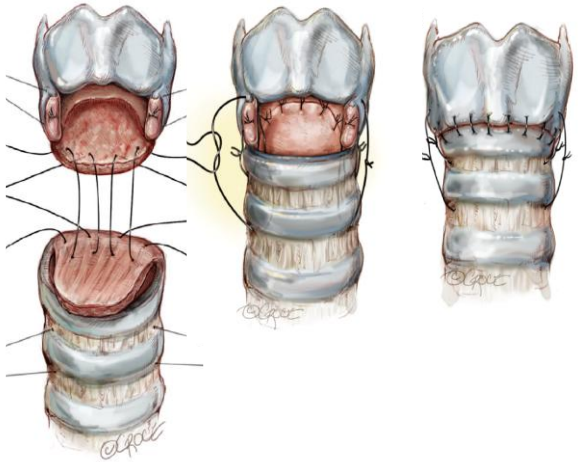

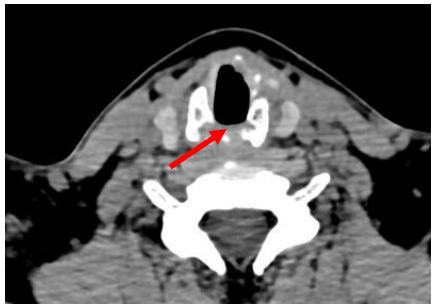

Post-op.

Complex Airway Reconstruction

Benign Disease

- **Resection & Reconstruction**
  - Mediastinal trachea & bronchi
    - Approaches

• *Median sternotomy*

(manubrium / full)

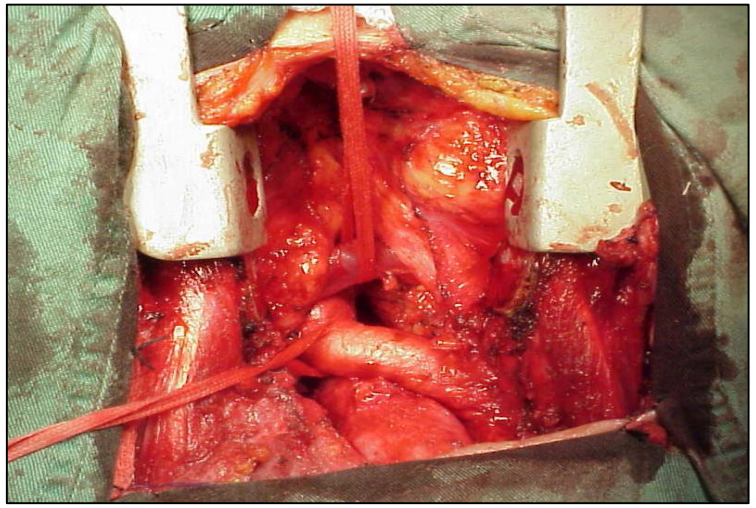

• *Right thoracotomy*

(open / VATS / RATS)

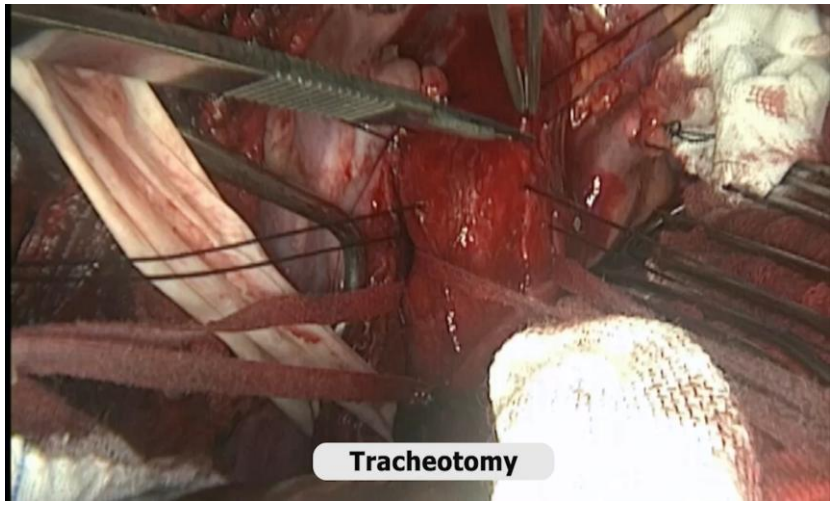

Complex Airway Reconstruction

Benign Disease

- **Resection & Reconstruction**
  - Mediastinal trachea & bronchi
    - Tracheobronchial TB - Stenosis R.U.L. (atelectasis + recurrent infections)

- *Feasible reconstruction (case 1)*

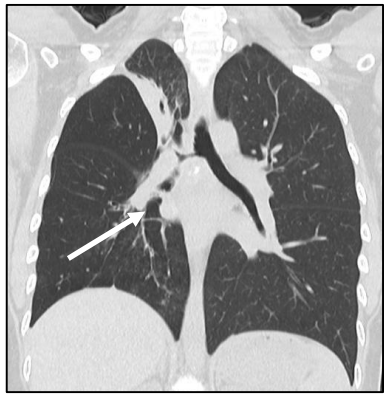

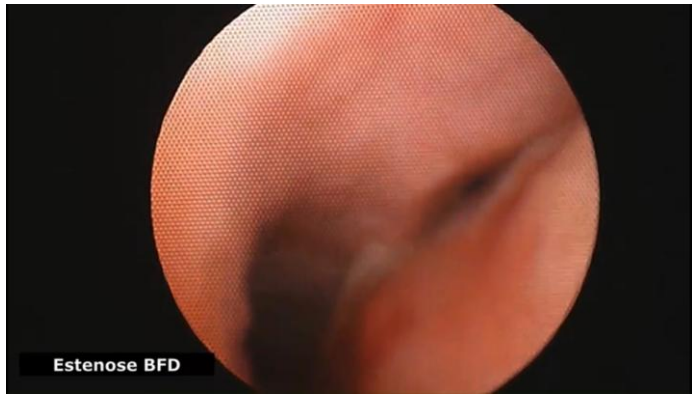

Preserved bronchus intermedius + distal trachea
(right upper lobectomy + tracheobronchoplasty)

- *Unfeasible reconstruction (case 2)*

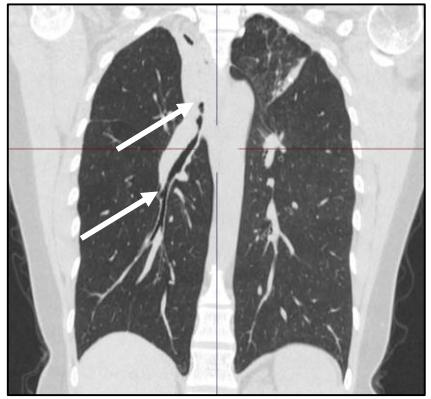

(2022)

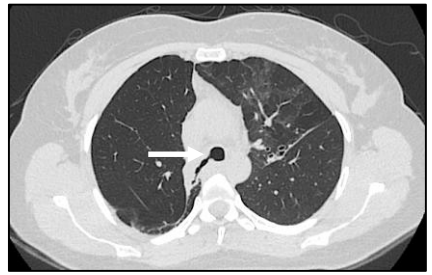

Right upper lobectomy
(2024)

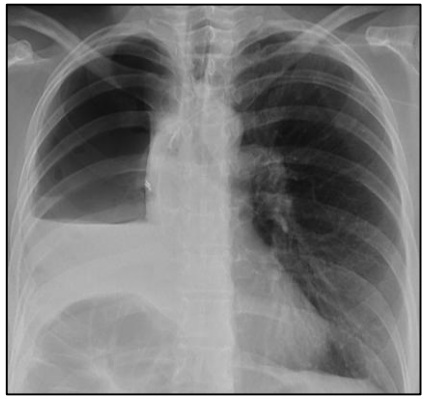

Pneumonectomy (2025)

Compromised bronchus intermedius + distal trachea
(right completion pneumonectomy >> platypnea-orthodeoxia syndrome)

Complex Airway Reconstruction

Benign Disease

- **Resection & Reconstruction**

Surgical Management of Benign Acquired Tracheoesophageal Fistulas: A Ten-Year Experience

Benoit Jacques Bibas, MD, Paulo Francisco Guerreiro Cardoso, MD, PhD, Helio Minamoto, MD, PhD, Leandro Picheth Eloy-Pereira, MD, Mauro Federico L. Tamagno, MD, Ricardo Mingarini Terra, MD, PhD, and Paulo Manoel Pêgo-Fernandes, MD, PhD

– Tracheoinnominate fistula

- *Surgical / Endovascular*

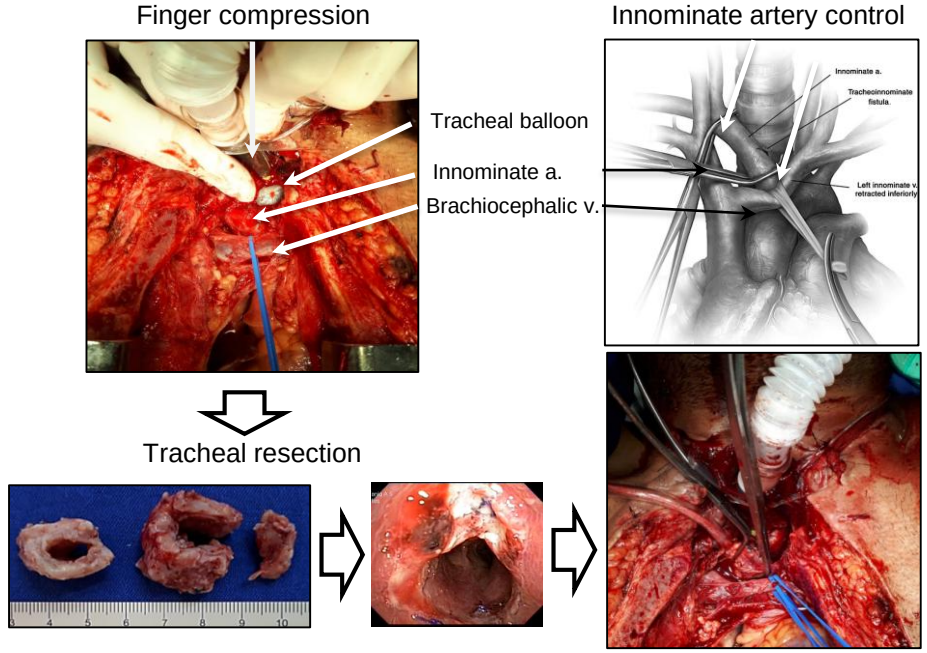

– Tracheoesophageal fistula

- *Surgical / Prosthesis (T-tube)*



Table 5. Summary of Published Results in TEF Repair

Study	Year	n	PII, %	TS, %	PFR, %	Morbidity, %	Mortality, %	TEF Recurrence, %
Bibas and colleagues	2016	20	80	55	15	55	5	5
Muniappan and colleagues [2]	2013	36	47	61	36	56	2.8	11
Shen and colleagues [12]	2010	21	9.5	9.5	22.8	54.3	5.7	8.6
Camargo and colleagues [11]	2010	16	93.8	100	18.8	25	0	0
Macchiarini and colleagues [9]	2000	32	NI	43.8	63	22	3.1	3.2
Baisi and colleagues [13]	1999	29	74.2	3.4	0	NI	3.4	0
Mathisen and colleagues [1]	1991	38	71.1	81.6	21.1	NI	10.5	7.9

NI = not informed; PFR = previous failed TEF repair; PII = postintubation injury; TEF = tracheoesophageal fistula; TS = tracheal stenosis.

Cardoso. Thorac Surg Clin 2018; 28:227
Bibas, Cardoso, Minamoto. Ann Thorac Surg 2016;102:1081

Complex Airway Reconstruction

Benign Disease


Predictors for Postoperative Complications After Tracheal Resection

Benoit Jacques Bibas, MD, Ricardo Mingarini Terra, MD, PhD, Antonio Lopes Oliveira Junior, MD, Mauro Federico Luis Tamagno, MD, Helio Minamoto, MD, PhD, Paulo Francisco Guerreiro Cardoso, MD, PhD, and Paulo Manuel Pêgo-Fernandes, MD, PhD

Thoracic Surgery Department, Heart Institute (InCor), Hospital das Clínicas da Faculdade de Medicina da Universidade de São Paulo, São Paulo, Brazil

- **Predictors of outcome – Complications**
  - Complications after tracheal resection
    - Univariate analysis

Variable (pre-op)	WITHOUT complications	WITH complications	OR	*p*
Comorbidities	9 (11,8%)	6 (33%)	3,7	***0,036***
Previous T-tube	10 (13%)	7 (38%)	4,2	***0,018***
BMI > 30	3 (3.9%)	4 (22%)	6,9	***0,024***
Previous tracheostomy	51 (67%)	17 (94%)	8,3	***0,020***

- Diabetes
- Cardiovascular
- Neurological

    - Multivariate analysis

Variable (pre-op)	OR	95% C.I.	*p*
Resection > 40mm	5,16	1,935–13,7	***0,001***
Comorbidites	7,04	1,510–32,8	***0,013***
Previous resection	49,9	2,403–1038	***0,012***

- Diabetes
- Cardiovascular
- Neurological

Bibas. Ann Thorac Surg 2014;98:277

Complex Airway Reconstruction

Benign Disease

- **Thoracic Surgery Research Laboratory**
  - LIM 61 / Organ & Tissue lab (InCor-HCFMUSP)
    - Coordinators



Paulo Fernandes PhD (Chair)



Paulo Cardoso MSc, PhD (Vice-chair)



Fernanda Lopes PhD (Senior researcher)

    - Researchers



*Rogerio Pazetti**



*Natalia Nepomuceno**



*Aristides Correia**



*Liliane Ruiz**



Tatiana Machado (administrator)

    - Post-graduate students – Ph.D. program *
    - Undergraduate students – Jr. scientist program

(*) Ph.D.- Post-Graduate Program in Thoracic and Cardiovascular Surgery
Faculty of Medicine of the University of Sao Paulo, Brazil

Complex Airway Reconstruction

Benign Disease

- **Research – Laryngotracheal stenosis**
  - Endoscopic posterior laryngofissure
    - Contact diode Laser (pigs)
      - Less invasive

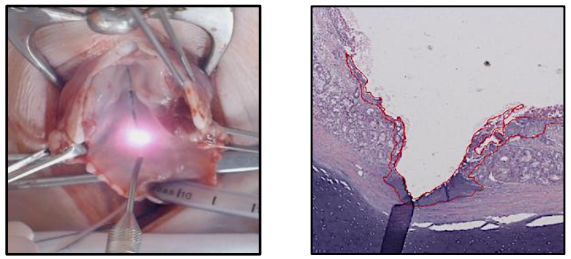

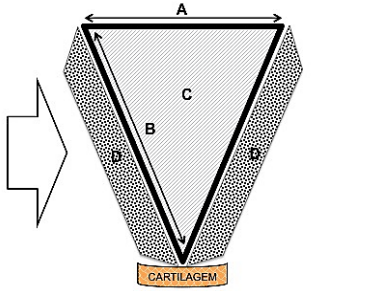

Medida A = distância entre as bordas do epitélio íntegro
Medida B = distância do epitélio até o ponto mais profundo da incisão
Medida C = área correspondente ao espaço gerado pela incisão
Medida D = área de dano térmico lateral

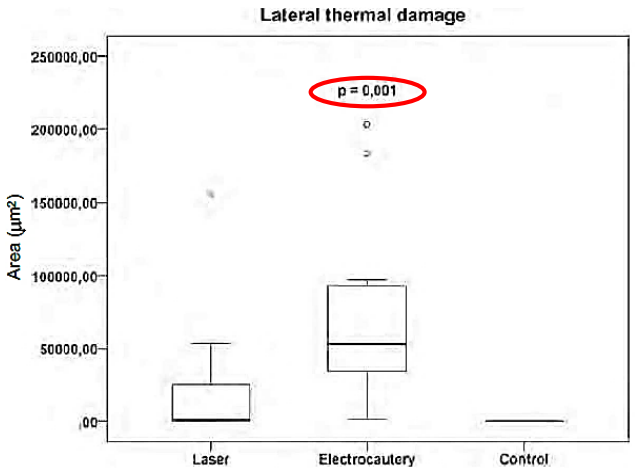

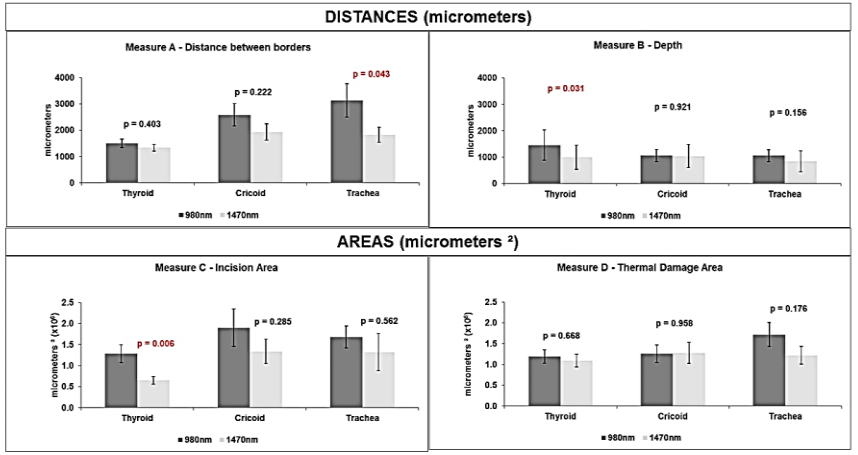



Menezes. Lasers Med Sci 2019;34:1441
Rodrigues. Scientific Rep 2024;14:11457

Complex Airway Reconstruction

Benign Disease

- **Research – Long-segment stenosis**
  - Tissue engineered tracheal segments
    - Descellularization protocol
      - Scaffolds (production / storage)

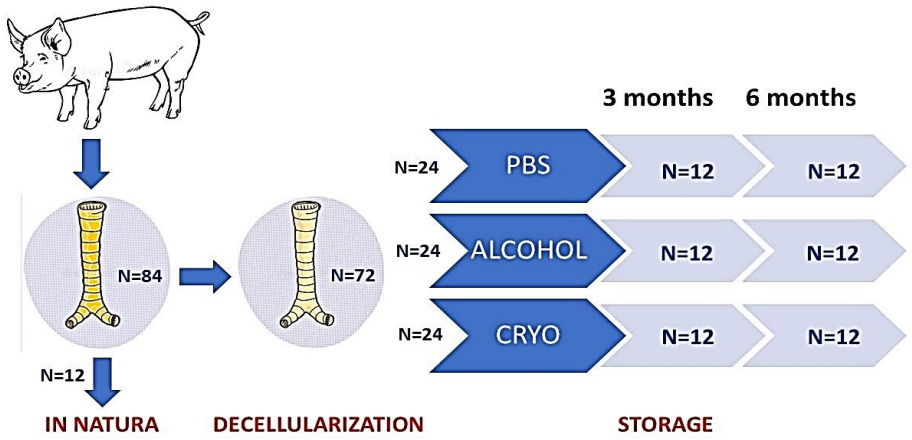

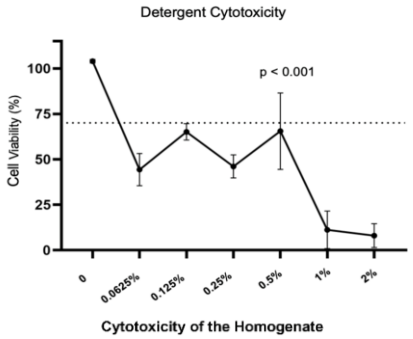

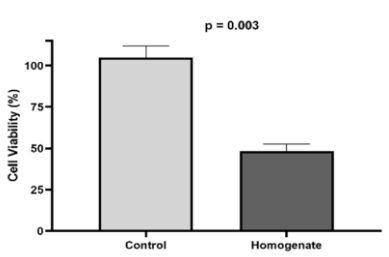

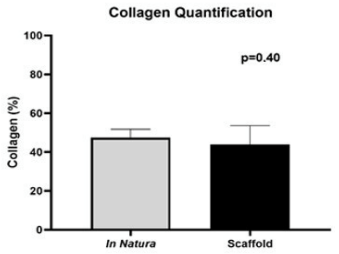

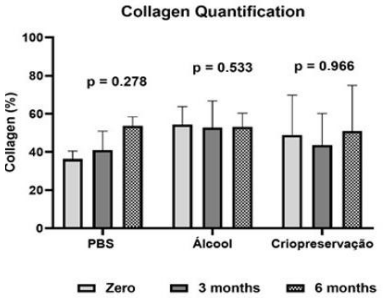

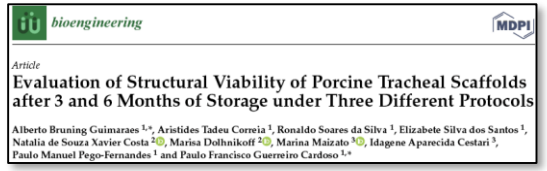

PhD - Alberto Brunning Guimaraes
Post-Graduate Program in Thoracic and Cardiovascular Surgery
Guimaraes. Bioengineering 2023 (doi.org/10.3390/Bioengineering10050584)

Complex Airway Reconstruction

Benign Disease

- **Research – Early detection of tracheal stenosis**
  - Non-invasive diagnostic methods (rabbit model)
    - Early diagnosis

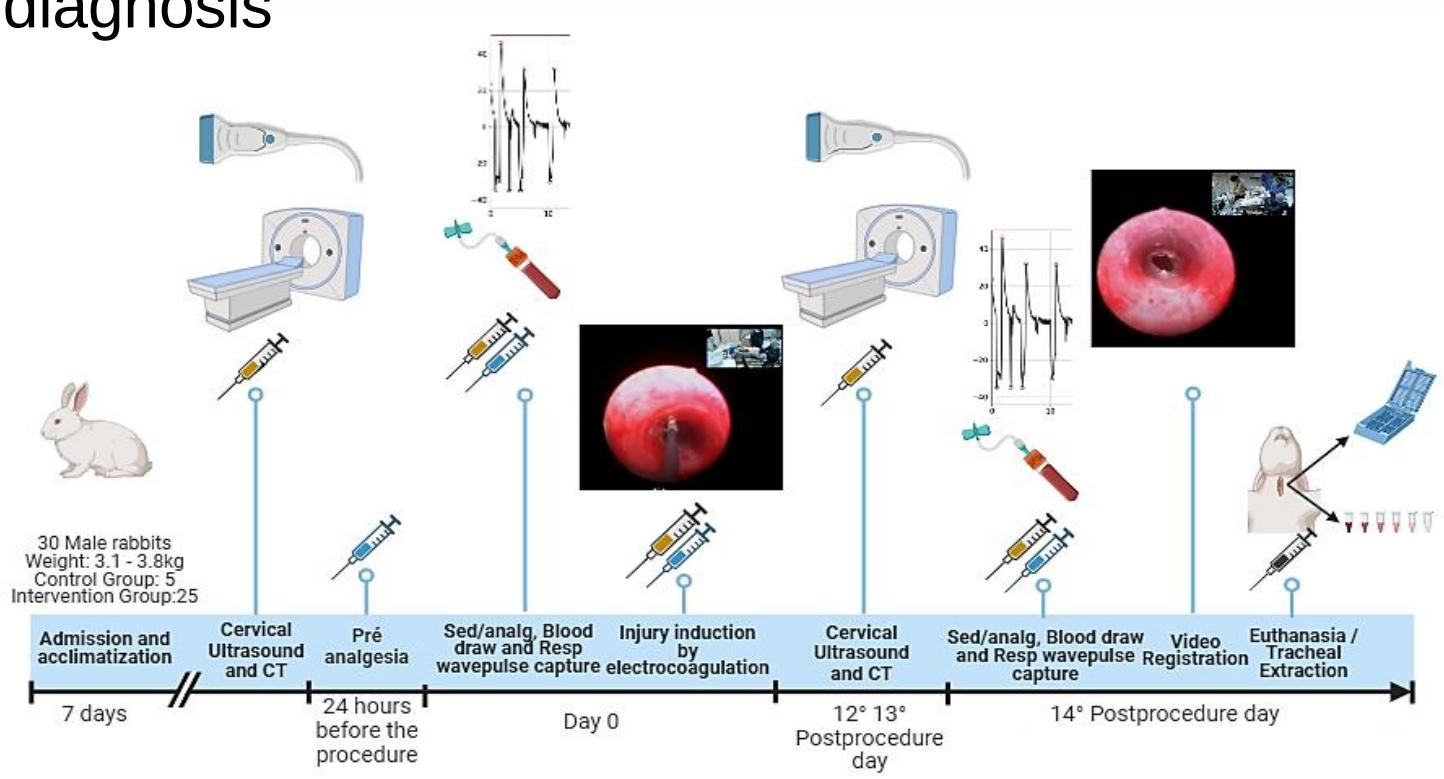

PhD - Heitor Correia da Silva
Post-Graduate Program in Thoracic and Cardiovascular Surgery

Complex Airway Reconstruction

Benign Disease

- **Research – Early detection of tracheal stenosis**
  - Non-invasive diagnostic methods (rabbit model)
    - Early diagnosis

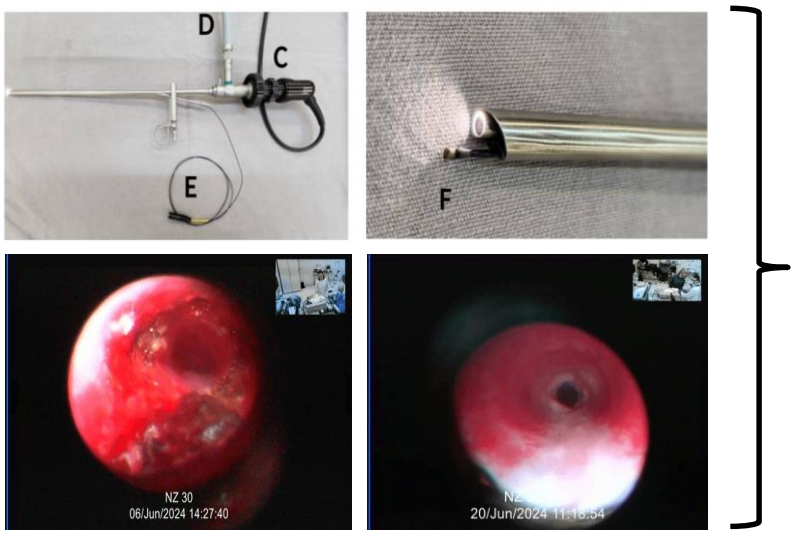

Induction of Stenosis
(1st day)

Stenosis
(14th day)

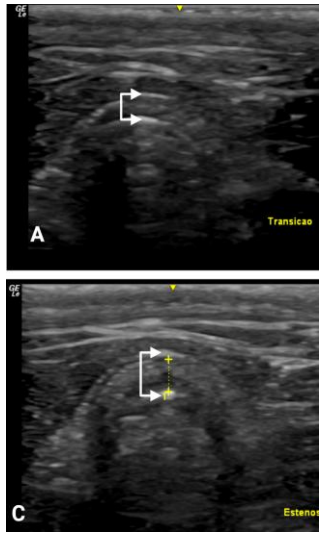

Ultrasonography
(14th day)

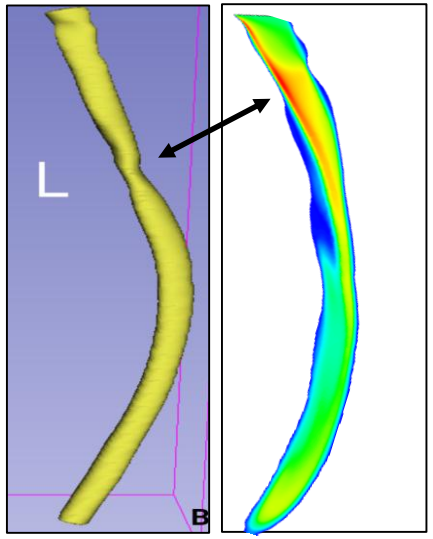

Tracheal CT scan + CFD*
(14th day)

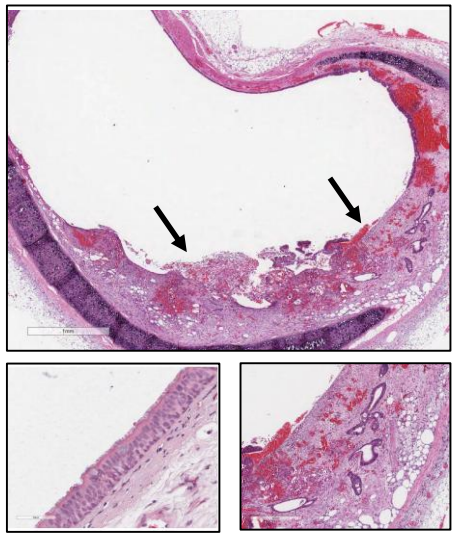

Histopatology
(14th day)

TGF-β1
IL-1
IL-6
IL-8
IL-10

Inflammation markers
(1st and 14th day)

(*) Computational Fluid Dynamics

PhD - Heitor Correia da Silva
Post-Graduate Program in Thoracic and Cardiovascular Surgery

Complex Airway Reconstruction

Benign Disease

- **Research – Early detection of tracheal stenosis**
  - Non-invasive diagnostic methods (rabbit model)
    - Cytokines - **TGF-β1**

- Plasma (Day 0 vs. Day 14)

Groups	n	Mean ± SEM	Median (Q_1 – Q_3)	*p*
- Control				
- Plasma				
D0	7	733 ± 398	682 (548 – 1.063)	*0,310*
D14	7	827 ± 410	972 (687 – 1.097)	
- Intervention				
- Plasma				
D0	26	716 ± 350	806 (591 – 955)	*0,001*
D14	26	988 ± 261	999 (861 – 1.107)	

- Tracheal homogenate (with vs. without stenosis)

Groups	n	Mean ± SEM	Median (Q_1 – Q_3)	*p*
- Control				
- Homogenato Traqueal				
With stenosis	3	118,6 ± 104,8	156,7 (– – –)	–
Without stenosis	3	118,3 ± 103,7	161,6 (– – –)	
- Intervention				
- Tracheal homogenate				
With stenosis	11	500,8 ± 299,1	467,8 (316,1 – 591,8)	*0,008*
Without stenosis	11	166,3 ± 109,3	183,6 (59,9 – 222,6)	

Future >> Blockers / Regenerative medicine

(e.g. pirfenidone; stromal fraction)

PhD - Heitor Correia da Silva
Post-Graduate Program in Thoracic and Cardiovascular Surgery

Complex Airway Reconstruction

Benign Disease

- ***Conclusions***
  - *Brasil (SP) high prevalence of iatrogenic tracheal stenosis.*

Complex Airway Reconstruction

Benign Disease

- ***Conclusions***
  - *Brasil (SP) high prevalence of iatrogenic tracheal stenosis.*
    - *High number of tracheostomies & complex stenoses (laryngotracheal).*

Complex Airway Reconstruction

Benign Disease

- ***Conclusions***
  - *Brasil (SP) high prevalence of iatrogenic tracheal stenosis.*
    - *High number of tracheostomies & complex stenoses (laryngotracheal).*
  - *Individualize complex reconstructions according to severity.*

Complex Airway Reconstruction

Benign Disease

- ***Conclusions***
  - *Brasil (SP) high prevalence of iatrogenic tracheal stenosis.*
    - *High number of tracheostomies & complex stenoses (laryngotracheal).*
  - *Individualize complex reconstructions according to severity.*
  - *Early diagnosis and treatment may lead to less complex cases.*

Complex Airway Reconstruction

Benign Disease

- **Conclusions**
  - *Brasil (SP) high prevalence of iatrogenic tracheal stenosis.*
    - *High number of tracheostomies & complex stenoses (laryngotracheal).*
  - *Individualize complex reconstructions according to severity.*
  - *Early diagnosis and treatment may lead to less complex cases.*
  - *High volume centers are better prepared to treat complex cases.*

Complex Airway Reconstruction

Benign Disease

- ***Conclusions***
  - *Brasil (SP) high prevalence of iatrogenic tracheal stenosis.*
    - *High number of tracheostomies & complex stenoses (laryngotracheal).*
  - *Individualize complex reconstructions according to severity.*
  - *Early diagnosis and treatment may lead to less complex cases.*
  - *High volume centers are better prepared to treat complex cases.*
  - *Translational research is essential to address complex problems.*

Complex Airway Reconstruction

Benign Disease

- **Tibute – Airway surgery contributors**



Ronald H.R. Belsey
1910-2007
Frenchay Hospital
Bristol, UK



Mikhail Perelman
1924-2013
Russian Inst. Phtysiopnemology
Moscow, Russia



Hermes C. Grillo
1926-2006
MGH
Boston, US



Frederick G. Pearson
1926-2016
Toronto General Hospital
Toronto, Canada



Louis Couraud
1929-2016
University Bordeaux II
Bordeaux, France



Joel D. Cooper
1939-current
University of Pennsylvania
Philadelphia, US



George A. Patterson
1949-current
Washington University
St. Louis, US



Walter Klepetko
1955-current
Medical University of Vienna
Vienna, Austria



Vicente Forte
1937-2008
UNIFESP-SP
Sao Paulo, Brazil



Luiz Felippe Judice
1937-current
UFF-RJ
Niteroi, Brazil



Jose J.P. Camargo
1946-current
UFCSPA-RS
Porto Alegre, Brazil



Helio Minamoto
1955-current
InCor-HCFMUSP
Sao Paulo, Brazil

Complex Airway Reconstruction

Benign Disease

- **Division of Thoracic Surgery (InCor-HCFMUSP)**
  - Trachea and Airway Surgery Group
    - 4 Surgeons
      - Residents (Thoracic)
      - Fellows (Tracheal)
      - Post-graduates (PhD) *
      - 3 Outpatient clinics/week (2 on-site ; 1 *TeleTrachea*)
        - » 2.000 patients / yr


Helio Minamoto PhD


Paulo Cardoso PhD


Benoit Bibas PhD


Pedro Ciaralo MD

350 - 400 surgical procedures / yr
≈ 35-40 tracheal resections / yr
≈ 180 bronchoscopies / yr
150 - 200 prostheses / yr

(*) Post-Graduate Program in Thoracic and Cardiovascular Surgery
Faculty of Medicine of the University of Sao Paulo, Brazil

Complex Airway Reconstruction

Benign Disease



Instituto do Coracao (InCor-HCFMUSP), Hospital das Clinicas)
Faculty of Medicine of the University of Sao Paulo
Sao Paulo, Brazil

cardosop@gmail.com