Doctors of Thoracic Surgery®

Complex Chest Wall Resection

Elliot Wakeam, MD MPH

Associate Professor of Thoracic Surgery
Division of Thoracic Surgery · Toronto General Hospital
University Health Network · University of Toronto

UHN Toronto General Toronto Western Princess Margaret Toronto Rehab
COURAGE LIVES HERE

Doctors of Thoracic Surgery

Learning Objectives

- Scenarios for chest wall resection/reconstruction – no data!
- What is complex? Review operative management of several complex scenarios including
- Emerging Options for Reconstruction
  - Titanium sternum
  - 3D printing
  - Allografts
- What we will not talk about
  - Pancoast tumors
  - Spine resection
  - Not a lot about flaps/plastic surgery

Doctors of Thoracic Surgery

What is ‘complex’?

- Denotes risk – specifically, respiratory
- Reconstruction?
- How big is too big?

  (in other words: how much chest wall does a patient actually need?)

- How do associated structures involved in resection alter the risk?

Doctors of Thoracic Surgery®

What is complex?

1 Very Large Defects

> 5 contiguous ribs
> 200 cm² full-thickness
Anterior / lateral location

2 Clavicle & Thoracic Inlet

Clavicle resection
SC joint disruption
Subclavian vessel proximity
Brachial plexus

3 Thoracoabdominal Extension

Crossing the costal margin
Diaphragm involvement
Abdominal wall continuity

4 Very Posterior – Spinal involvement

Transverse process
Vertebral body

5 Total Sternectomy

Complete manubrium + body
Rigid reconstruction imperative
Respiratory impact of asynchronous chest wall motion

6 Primary Infected CW Lesion

Fungating / ulcerating tumor
Osteoradionecrosis
Chronic osteomyelitis

7 Infected Prior Reconstruction

Failed prosthesis / mesh
Post-sternotomy deep wound
Re-do after prior CW surgery

UHN Toronto General Toronto Western Princess Margaret Toronto Rehab
COURAGE LIVES HERE

Doctors of Thoracic Surgery

Very Large Defects



64F with fungating breast cancer

UHN Toronto General Toronto Western Princess Margaret Toronto Rehab
COURAGE LIVES HERE

Doctors of Thoracic Surgery

Very Large Defects:

Resection & Reconstruction Principles

Definition: ≥ 5 contiguous ribs OR ≥ 200 cm²
full-thickness defect, particularly anterolateral

Does this mandate a rigid recon?

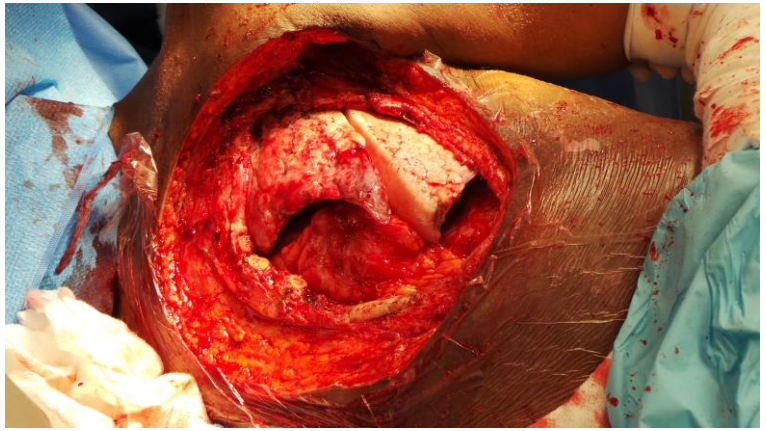

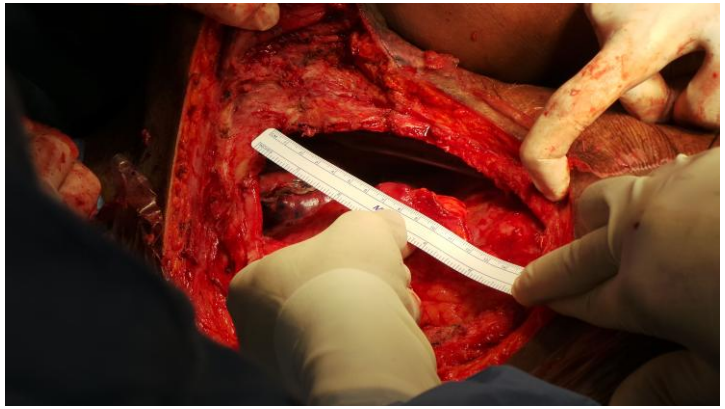

UHN Toronto General Toronto Western Princess Margaret Toronto Rehab
COURAGE LIVES HERE

Reconstruction

Reconstruction threshold: > 5 cm diameter OR > 3 anterior / > 4 posterior ribs

Anterolateral defects sometimes require rigid or semi-rigid stabilization

Goretex mesh 1mm thickness

Titanium rib-bridge systems (STRATOS, ThoRIB from Neurofrance)

Polypropylene mesh: widely used; adequate for moderate defects with good soft tissue coverage

Titanium mesh

Biological mesh (Permacol, Strattice): infected / irradiated fields

MMA sandwich mesh

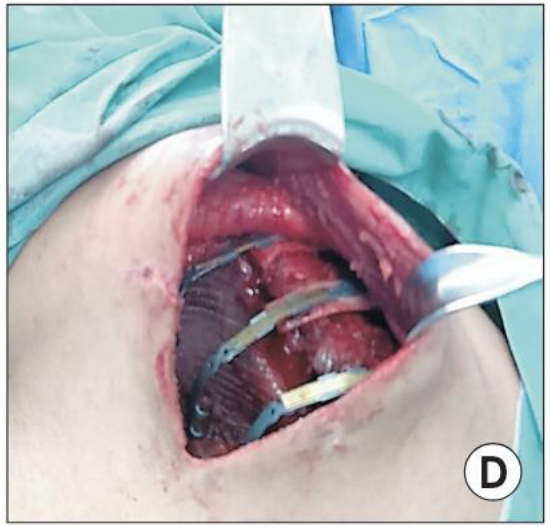

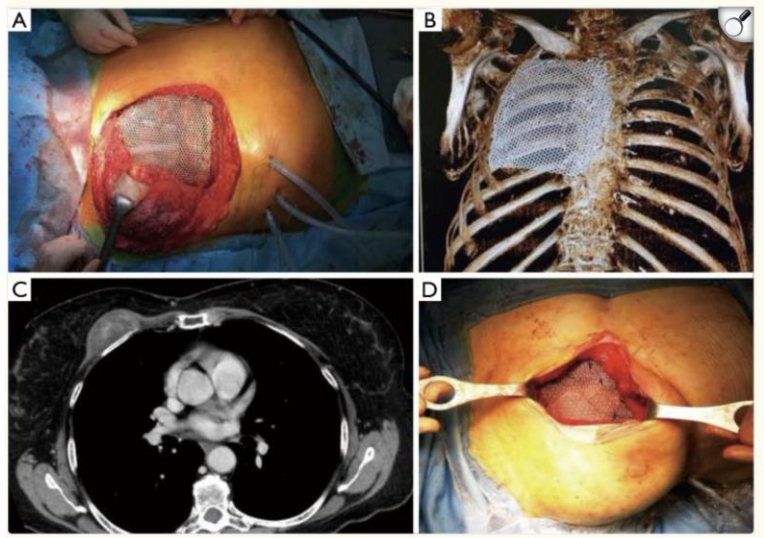



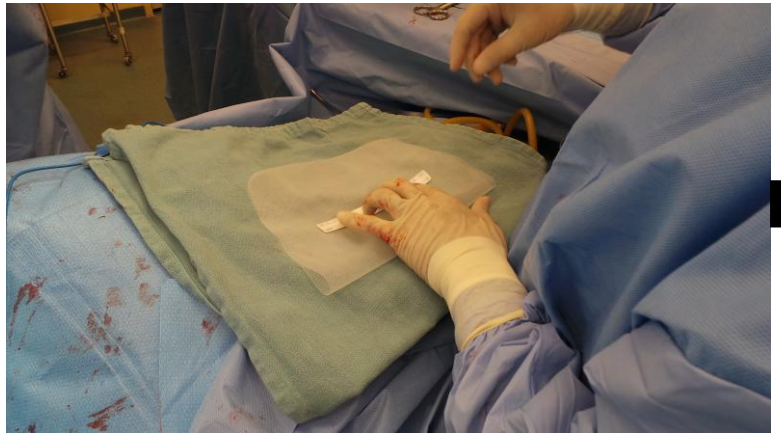

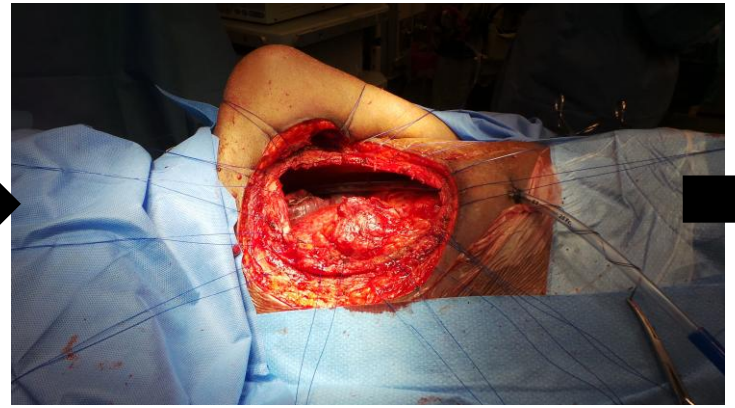







UHN Toronto General Toronto Western Princess Margaret Toronto Rehab
COURAGE LIVES HERE

Doctors of Thoracic Surgery

But you can also use goretex….





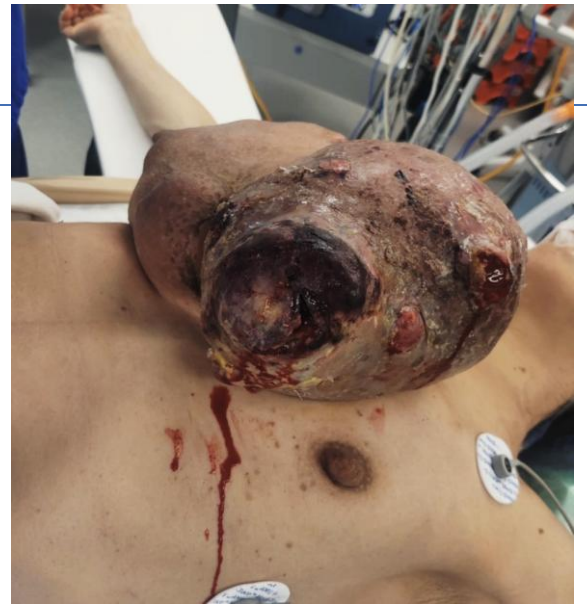





Depends on location, patient, surgeon…but in high risk of respiratory issues rigid is *probably* better/safer

UHN Toronto General Toronto Western Princess Margaret Toronto Rehab
COURAGE LIVES HERE

Doctors of Thoracic Surgery

Summary: Large Defects

- Recon is somewhat “dealers choice”: **it depends!**
- Goretex and MMA are workhorses
- Titanium ribs +/- goretex
- Choice depends on the patient as much as the defect

UHN Toronto General Toronto Western Princess Margaret Toronto Rehab
COURAGE LIVES HERE

Category 2: Thoracic Inlet

Clavicle resection · Sternoclavicular joint · subclavian vessels · brachial plexus

Doctors of Thoracic Surgery

Clavicle & Thoracic Inlet: Approach & Technique

- **Planning**
  - Multi-d team – vascular, plastics, peripheral nerve
  - Nerve, artery and vein – all resectable/reconstructible
  - Brachial plexus – limits to resection, can be reconstructed
  - When do you need a forequarter plus chest wall resection?







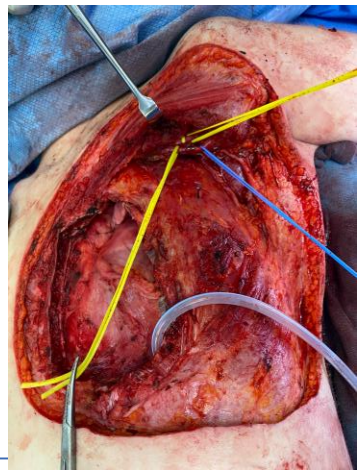

UHN Toronto General Toronto Western Princess Margaret Toronto Rehab
COURAGE LIVES HERE

Doctors of Thoracic Surgery

Nerve Grafting of C5-6 Roots of the Brachial Plexus Using Sural Nerve Cable Grafting





Courtesy Dr Heather Baltzer, UHN

UHN Toronto General Toronto Western Princess Margaret Toronto Rehab
COURAGE LIVES HERE

Doctors of Thoracic Surgery

Sometimes you will need to do a forequarter amputation

27M with MPNST of the brachial plexus with chest wall invasion, growth on radiation



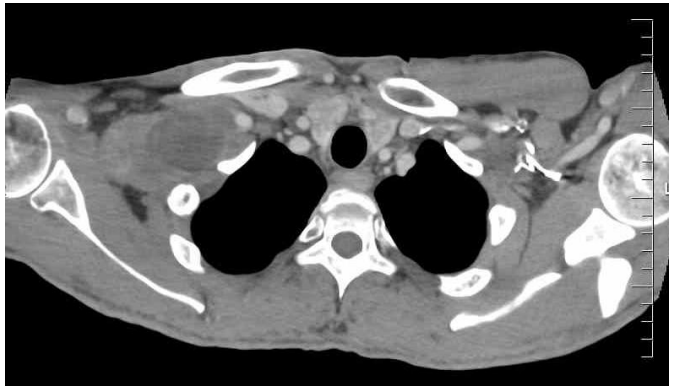



UHN Toronto General Toronto Western Princess Margaret Toronto Rehab
COURAGE LIVES HERE

Doctors of Thoracic Surgery

Reconstructing the dome/cupola of the chest

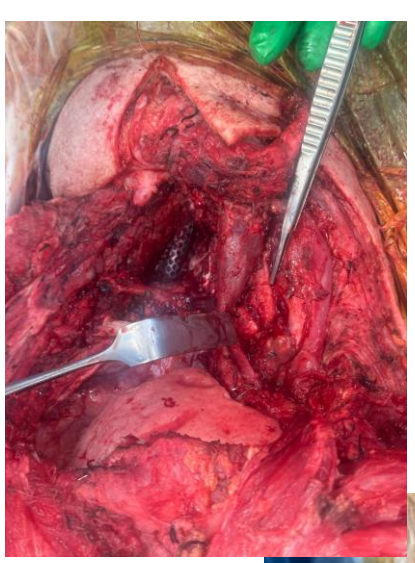



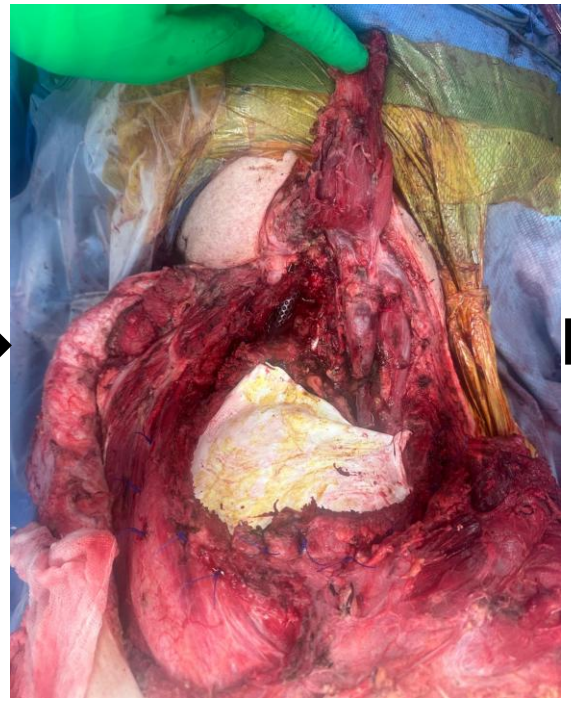







UHN Toronto General Toronto Western Princess Margaret Toronto Rehab

COURAGE LIVES HERE

Summary: Thoracic Inlet

- Vascular dissection with or without reconstruction
- Chest wall resection gives you fantastic access to the vessels+plexus
- Brachial plexus – can be reconstructed
- Cupola/dome doesn’t provide much respiratory function – gore-tex sufficient

Category 3: Thoracoabdominal Extension

Crossing the costal margin · Diaphragm · Abdominal wall

Doctors of Thoracic Surgery®

Thoracoabdominal Extension: Resection & Reconstruction

Resection Principles
Tumors crossing the costal margin (ribs 7–10) involve the diaphragm and often the abdominal wall (external oblique, internal oblique, transversus)
En-bloc diaphragm resection: peripheral resection down to central tendon; maintain phrenic nerve supply when feasible
Combined thoracoabdominal incision for dual access to chest and abdomen

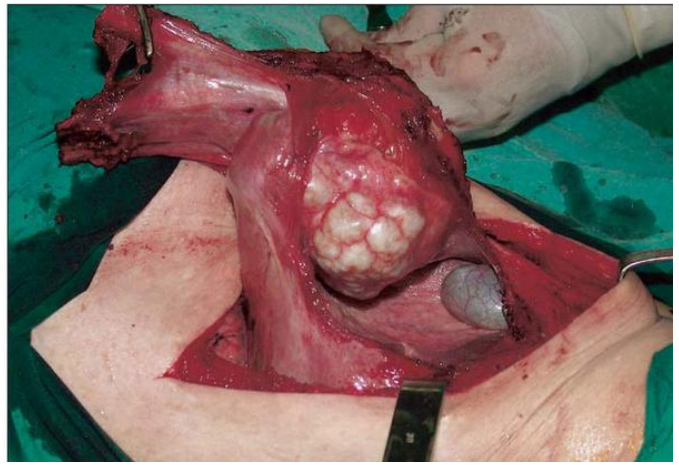

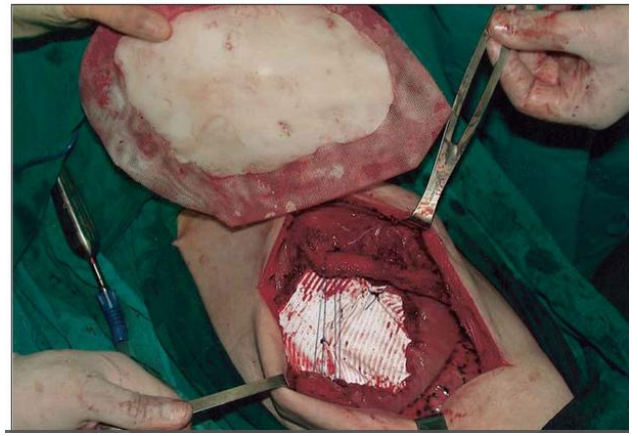



UHN Toronto General Toronto Western Princess Margaret Toronto Rehab
COURAGE LIVES HERE

Doctors of Thoracic Surgery

Reconstruction Strategy
Diaphragm reconstruction: direct suture (defects < 3–4 cm) vs PTFE / Gore-Tex patch (larger, airtight + watertight required)
'Phrenoplasty': peripheral diaphragm detachment → anchor to upper rib margin, converting thoracic defect to abdominal
Abdominal wall reconstruction: mesh (component separation for large defects)
Risks: diaphragm palsy, dehiscence, atrophy, herniation

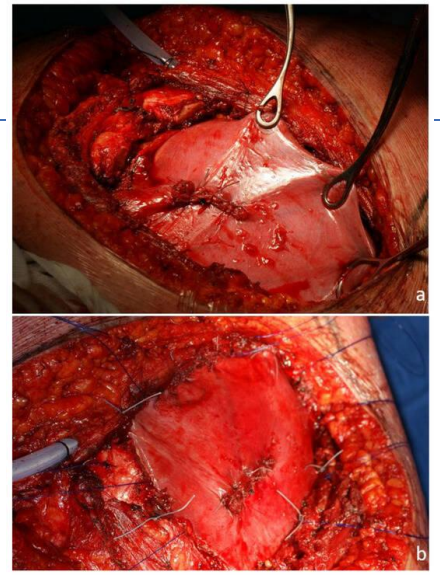

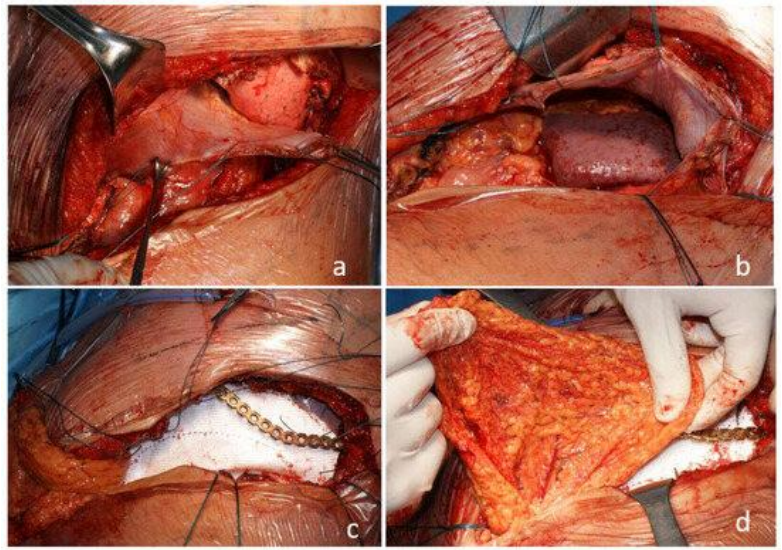

Phrenoplasty Techniques for the Reconstruction of Basal Chest Wall Defects

by Francesco Puma [1], Silvia Ceccarelli [1], Alberto Melis [1], Domenico Pourmolkara [1], Eleonora Coviello [1], Riccardo Amatucci [1], Niccolò Daddi [2] and Jacopo Vannucci [3,*]

UHN Toronto General Toronto Western Princess Margaret Toronto Rehab
COURAGE LIVES HERE

Doctors of Thoracic Surgery®

If you cant plasty it…double mesh…











eral
ern
garet
ab

Doctors of Thoracic Surgery®

Summary: Thoracoabdominal Extension

Diaphragm Reconstruction

Phrenoplasty is my preference where possible

Never close under tension — pull-through failure leads to late diaphragmatic hernia

Double-mesh technique for large defects: separate thoracic and abdominal meshes

Phrenic nerve integrity

Positioning & Exposure

True lateral decubitus limits abdominal access — semi-lateral (30–45°) preferred for dual-field exposure

UHN Toronto General Toronto Western Princess Margaret Toronto Rehab
COURAGE LIVES HERE

Category 4: Primary Infected CW Lesion

Fungating tumor · Osteoradionecrosis · Osteomyelitis

Doctors of Thoracic Surgery

Infected Chest Wall Lesions: Etiology & Resection Principles



UHN Toronto General Toronto Western Princess Margaret Toronto Rehab
COURAGE LIVES HERE

Doctors of Thoracic Surgery

Infected Chest Wall Lesions

Wound Preparation & Timing

Pre-op wound optimization: NPWT to reduce bacterial load before definitive closure

Staged approach (debridement → NPWT → reconstruction) safer than immediate closure over infected bone

Reconstruction in a Contaminated Field

Synthetic mesh is risky — absorbable, biological mesh (Permacol, Strattice) or allograft preferred

Vascularized muscle flap essential: obliterates dead space, delivers blood supply, resists infection

Palliative chest wall surgery is ok!

Ann Surg 2018: QOL data poor — only 8 studies, 1 with validated instrument; nothing prospective

Modern CW surgery less morbid than perceived —acceptable morbidity even in palliative cases

UHN Toronto General Toronto Western Princess Margaret Toronto Rehab
COURAGE LIVES HERE

Doctors of Thoracic Surgery







Vicryl mesh





Gore-tex mesh

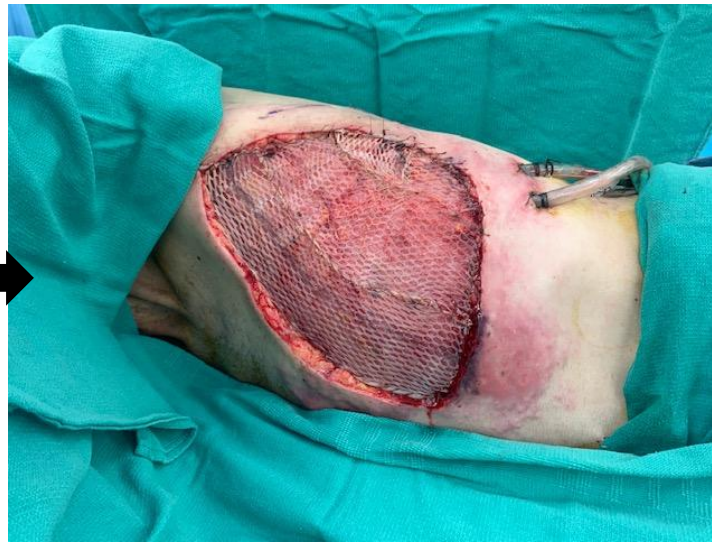

UHN Toronto General Toronto Western Princess Margaret Toronto Rehab

COURAGE LIVES HERE

Category 5: Total Sternectomy

Complete manubrium + body · Mediastinal exposure · Rigid reconstruction

Doctors of Thoracic Surgery

Total Sternectomy: Technique & Reconstruction

Indications & Resection

Primary sternal tumors (near-100% malignant): chondrosarcoma most common; osteosarcoma, Ewing, plasmacytoma

Secondary: breast cancer sternal mets (most common); thymic or mediastinal invasion; radionecrosis

Total sternectomy: entire manubrium + body ± clavicular heads; bilateral costal cartilage divisions from caudal to cranial

Internal mammary arteries: ligate bilaterally or preserve as recipient vessels for free flap



BCC skin with sternal invasion

UHN Toronto General Toronto Western Princess Margaret Toronto Rehab
COURAGE LIVES HERE

Doctors of Thoracic Surgery

Reconstruction: Rigid Imperative

Total sternectomy mandates rigid skeletal reconstruction — soft tissue alone insufficient

Titanium plates / custom 3D-printed titanium: excellent rigidity; biocompatible; no graft resorption

MMA sandwich (polypropylene + methyl methacrylate): effective; ~10–20% wound infection at 90 days

Allografts provide the rigidity with advantage of biological material

Pectoralis major bilateral advancement: first-line soft tissue coverage (6–8 of 8 sternal series)

LD flap: if pectoralis unavailable or irradiated; bilateral LD possible for large defects



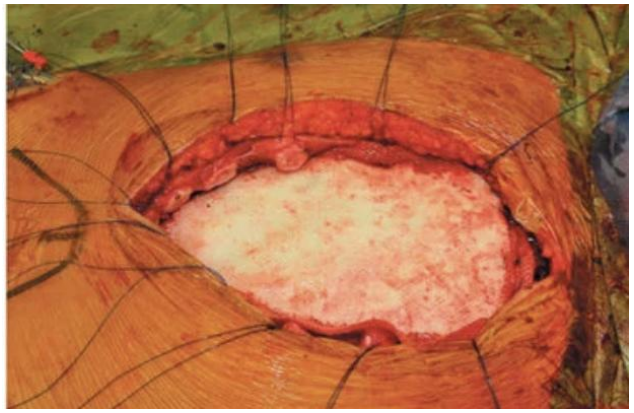

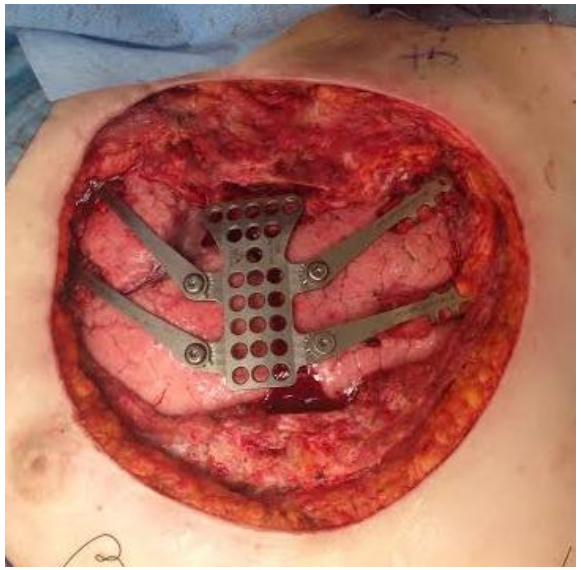

Doctors of Thoracic Surgery

Case 5: Total Sternectomy

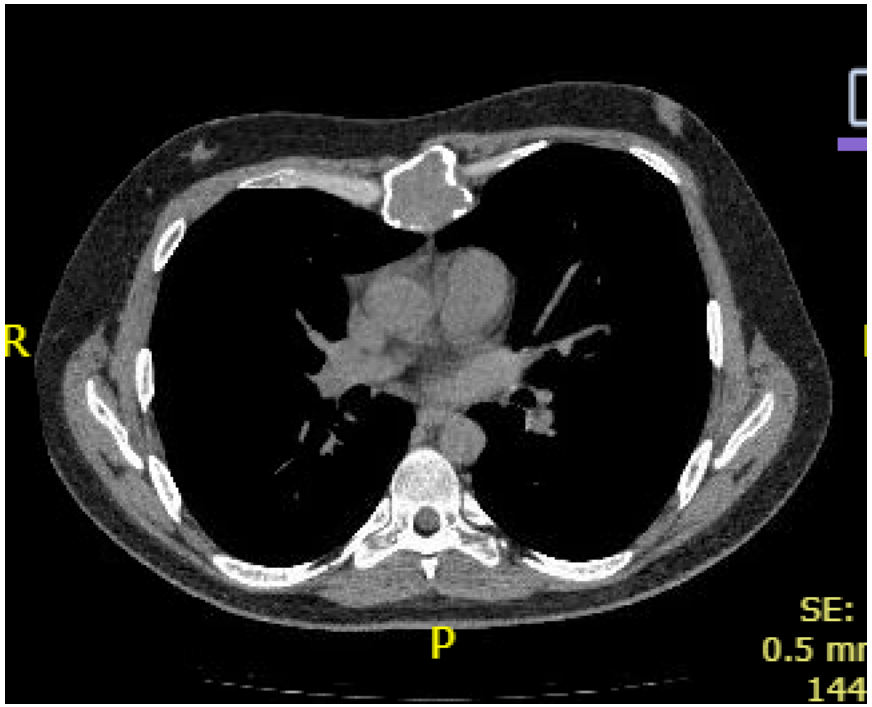



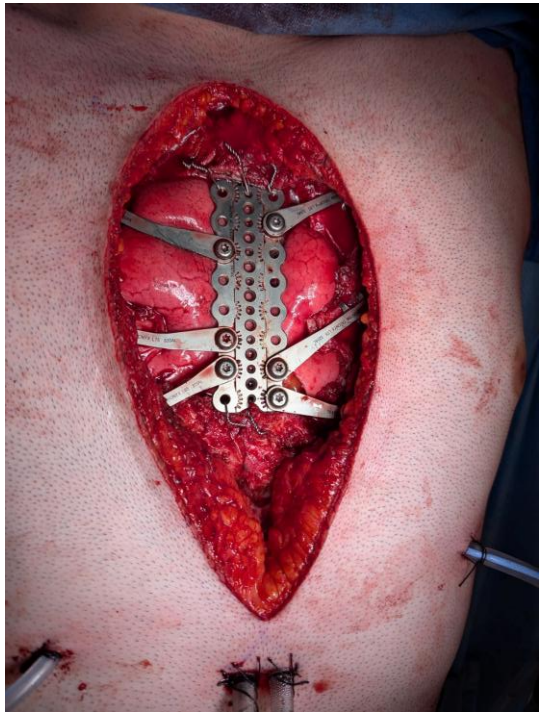

31M with giant cell tumor, tx with denosumab x ~6 months

Trionyx from Neurofrance









Sternochondral Allografting: Rationale & Biology

Why Allograft?

Prosthetic limitations: infection requiring removal in 10% of synthetic cases; fracture, migration, erosion risk; no true tissue integration

Allograft advantages: integration, biological

Multiple sizes available — adjust intraoperatively

Maintaining structural integrity of native bone scaffold cartilage portion provides flexibility + load-bearing - more physiologic than rigid plate?

Easily shaped to the defect – superior cosmetics and ?function





Doctors of Thoracic Surgery

Annals of Thoracic Surgery, 2021

Table 5. Postoperative Results

Variable	Patients	Tumor (n = 28)	Nonneoplastic (n = 30)	*P*
Median intensive care unit time, d	3 (IQR, 1-9.5) Range, 1-36	1 (IQR, 1-2) Range, 1-18	5 (IQR, 2-13) Range, 1-36	.001
Median ventilation time, h	8 (IQR, 4.7-20.7) Range, 1-312	3 (IQR, 2-4) Range, 1-5	13 (IQR, 7-96) Range, 4-312	.002
Median hospital stay, d	11 (IQR, 8-18)	9 (IQR, 7-16) Range, 6-61	16 (IQR, 9-21) Range, 3-37	.03
Postoperative morbidity	18 (31%)	4 (14%)	14 (47%)	.01
Pneumonia	4 (7%)	…	4 (13%)	
Pleural effusion	3 (5%)	1 (4%)	2 (7%)	
Wound dehiscence	6 (10%)	1 (4%)	5 (17%)	
Chest wall seroma	2 (3%)	1 (4%)	1 (3%)	
Muscle flap hematoma	2 (3%)	…	2 (7%)	
Pneumothorax	4 (7%)	…	4 (13%)	
Sepsis	1 (2%)	1 (4%)	…	
Melena/gastric ulcer	1 (2%)	…	1 (3%)	
Renal failure/hemodialysis	1 (2%)	…	1 (3%)	
Early reoperation	6 (10%)	1 (4%)	5 (17%)	.03
Wound soft tissue resuture	4 (7%)	1 (4%)	3 (10%)	
- Bleeding	1 (2%)	…	1 (3%)	
Implantation failure after trauma	1 (2%)	…	1 (3%)	
In-hospital mortality causes of death	3 (5%)	1 (4%)	2 (7%)	.6
Pneumonia/sepsis	1	…	1 (3%)	
Disseminated intravascular coagulation/pulmonary embolism	1	1 (4%)	…	
Multiorgan failure	1	…	1 (3%)	

IQR, interquartile range

Indications and Results of Sternal Allograft Transplantation: Learning From a Worldwide Experience

Check for updates

Andrea Dell'Amore, MD, Martin Kalab, MD, Archibald Sandford Miller III, MD, Giampiero Dolci, MD, Valeria Liparulo, MD, Farahnaz Sadegh Beigee, MD, Lorenzo Rosso, MD, Pia Ferrigno, MD, Alessandro Pangoni, MD, Marco Schiavon, MD, Tommaso Bottio, MD, Francesco Puma, MD, Vladimir Lonsky, MD, and Federico Rea, MD

Thoracic Surgery Unit, Department of Cardiac, Thoracic, and Vascular Sciences, University of Padova, Padova, Italy; Department of Cardiac Surgery, University Hospital, Olmouc, Czech Republic; Department of Plastic Surgery, Oklahoma State University, Center for Health Sciences, Tulsa, Oklahoma; Department of Cardiothoracic Surgery, Policlinico S. Orsola-Malpighi, Bologna, Italy; General Thoracic Surgery Unit, University of Perugia, Perugia, Italy; Department of Thoracic Surgery, University Medical Sciences Tehran, Tehran, Iran; and Thoracic Surgery and Lung Transplant Unit, Ospedale Maggiore Policlinico, University of Milan, Milan, Italy

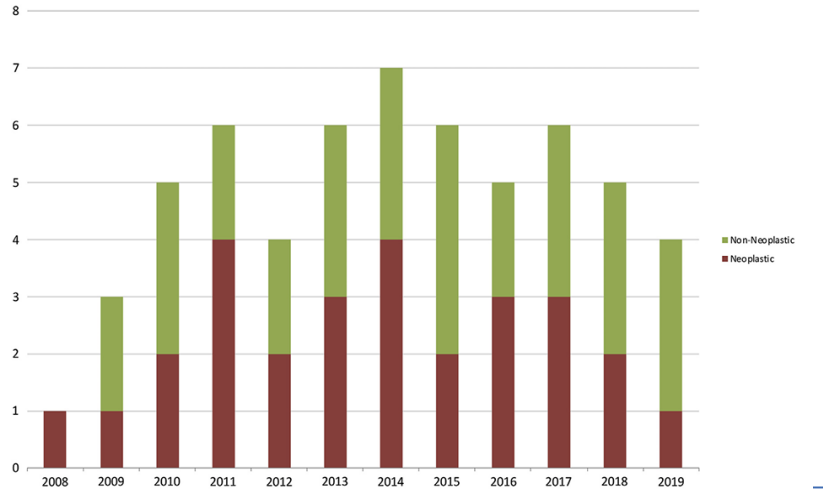

UHN Toronto General Toronto Western Princess Margaret Toronto Rehab
COURAGE LIVES HERE

Doctors of Thoracic Surgery®

Sternochondral Allografting: Outcomes

N=58	31%	84.6%	0%
largest multicenter series (Dell'Amore 2020)	30-day morbidity (multicenter series)	complication-free (Italian series N=14)	infection / rejection of allograft in all series

Key Outcome Data

Dell'Amore 2020 (N=58): 30-day mortality 5%; morbidity 31% (respiratory + wound); no respiratory deficiency from inadequate mechanics; graft integrated on bone scintigraphy in all survivors

Italian series N=14 (Marulli 2014): 84.6% complication-free; no infection or rejection of graft; 7 alive disease-free at follow-up; no flail chest

Allograft vs prosthesis: no increased respiratory failure; avoids prosthetic removal for infection (0% vs 9% synthetic)

Median hospital stay: 11 days (range 6–31); comparable to prosthetic reconstruction

Doctors of Thoracic Surgery

Sternochondral Allografting: Technique

Graft Selection & Preparation

- Select allograft size to match defect on preoperative CT;
- Cadaveric sternochondral block includes manubrium, sternal body, bilateral costal cartilages (ribs 1–7)
- Trim and shape graft on back table
- Graft thawed to room temperature before implantation
- Blood type and HLA matched

Fixation

- Transverse titanium plates + screws
- Provides initial stability while integration occurs
- Wires/sutures at costal cartilage junctions
- Supplemental rigid fixation is always added

Soft Tissue Coverage

- All allografts must be covered with vascularized soft tissue





UHN Toronto General Toronto Western Princess Margaret Toronto Rehab
COURAGE LIVES HERE

Doctors of Thoracic Surgery

Initial presentation

- 55F with biopsy proven low grade chondroid neoplasm, likely chondrosarcoma
- **Initial CT chest** – 6.5 x 2.7 cm sternal lesion





UHN Toronto General Toronto Western Princess Margaret Toronto Rehab
COURAGE LIVES HERE

Doctors of Thoracic Surgery

Intra-operative

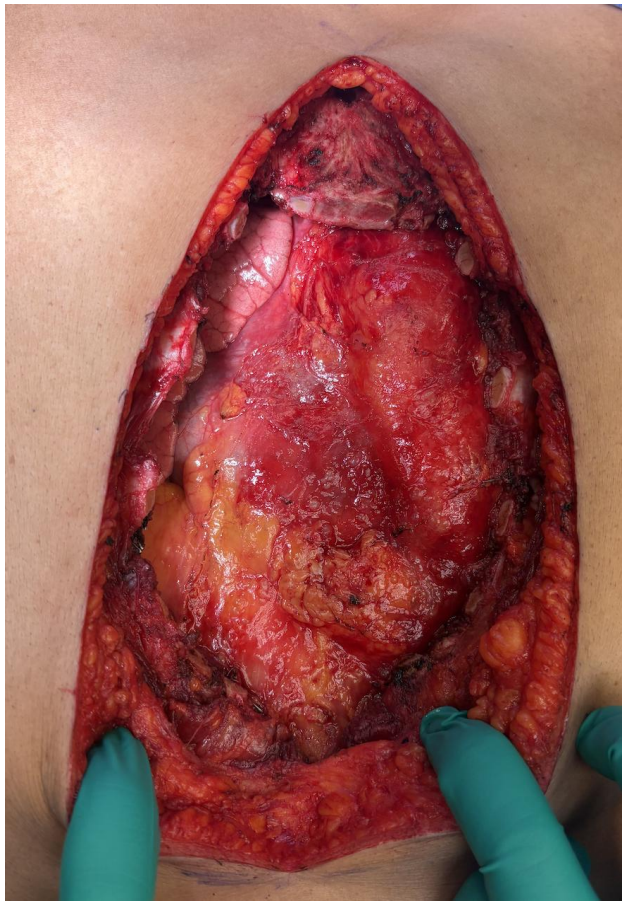





UHN Toronto General Toronto Western Princess Margaret Toronto Rehab

COURAGE LIVES HERE

Doctors of Thoracic Surgery

Final Product





UHN Toronto General Toronto Western Princess Margaret Toronto Rehab
COURAGE LIVES HERE

Doctors of Thoracic Surgery

What if you need rigidity, wide coverage, but also infection resistance?



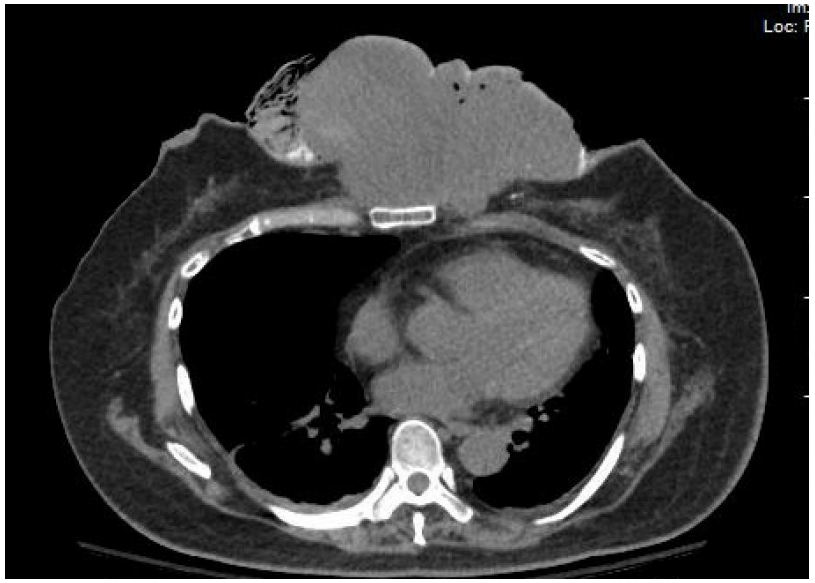

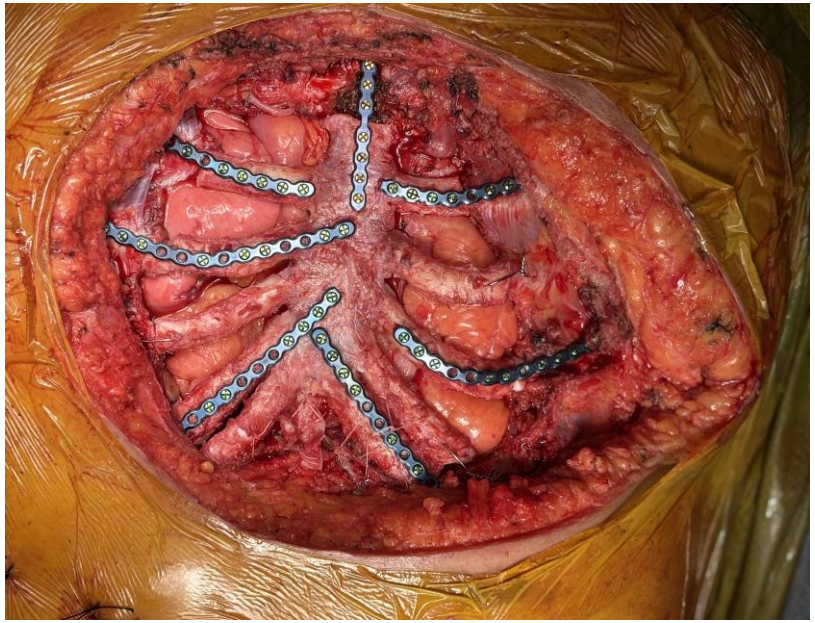

Recurrent TNBC with multi-resistant pseudomonas, bleeding s/p embolization for life threatening bleed

UHN Toronto General Toronto Western Princess Margaret Toronto Rehab
COURAGE LIVES HERE

Doctors of Thoracic Surgery

TGH Allograft Experience

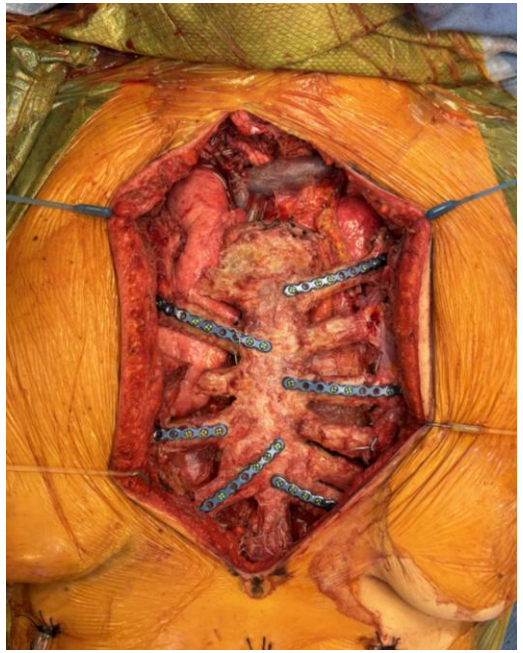

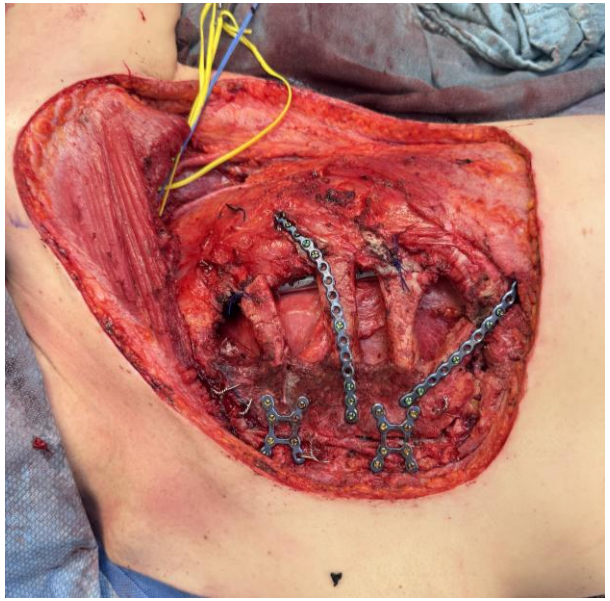


7 cases
Manubrium, hemi sternum, total sternum
Almost all infected or large sternal resections

No infections
1 graft failure
1 return to OR
No other complications
2 w/DSA – no clinical consequences

All cases now enrolled onto the SAFE-Sternum Registry

UHN Toronto General Toronto Western Princess Margaret Toronto Rehab
COURAGE LIVES HERE

Doctors of Thoracic Surgery®

Key Take-Home Points

1. Complexity is anatomically defined — large defect, clavicle/inlet, thoracoabdominal, brachial plexus involvement, and total sternectomy each demand distinct planning
2. Reconstruction options – gore-tex is work horse when no rigidity is required
3. Total sternectomy mandates rigid skeletal reconstruction
4. Sternochondral allografting offers true tissue integration, lower infection/rejection in published series, and physiologic flexibility
5. Respiratory complications remain the leading cause of death — reconstruction adequacy but also eval of the patient is critical

UHN Toronto General Toronto Western Princess Margaret Toronto Rehab
COURAGE LIVES HERE

Doctors of Thoracic Surgery

Division of Thoracic Surgery, Toronto General Hospital







UHN Toronto General Toronto Western Princess Margaret Toronto Rehab
COURAGE LIVES HERE