Doctors of Thoracic Surgery

Management of Tracheoesophageal Fistula

Jonathan Yeung, MD, PhD, FRCSC
Associate Professor, Departments of Surgery and Medical Biophysics
University of Toronto

UHN

Tracheoesophageal Fistulas

- Pathologic communication between airway and esophagus

Doctors of Thoracic Surgery

Tracheoesophageal Fistulas

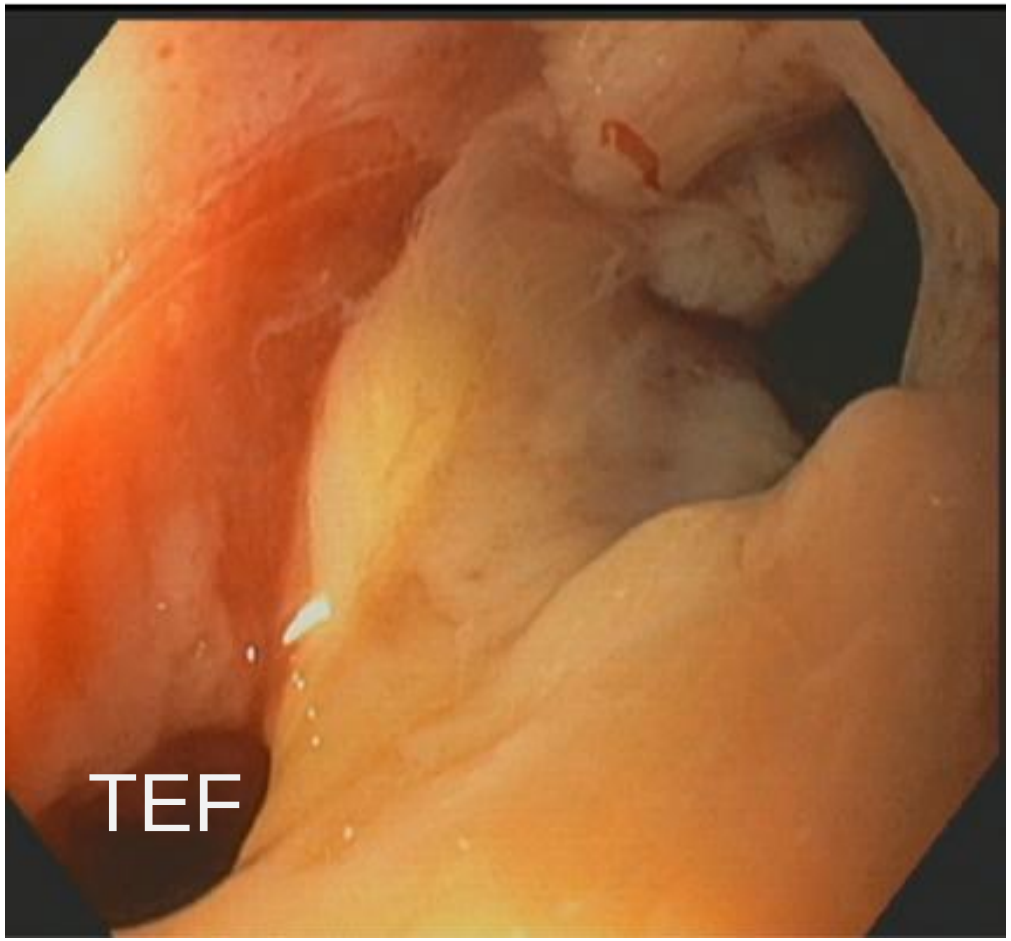

- UGH

UHN

Tracheoesophageal Fistulas

1. Congenital TEF
    - Usually pediatric, often associated with esophageal atresia.

2. Acquired benign TEF
    - Common causes: prolonged intubation/tracheostomy cuff injury, caustic injury, infection, trauma.

3. Postoperative TEF / airway-gastric conduit fistula
    - After esophagectomy, airway ischemia, anastomotic leak, radiation, infection, or tumor recurrence

4. Malignant TEF
    - Usually esophageal cancer, lung cancer, or mediastinal malignancy

Malignant TEF

- Fatal complication of malignancy
  - Pulmonary soilage, sepsis, death
- Radiation and chemo ineffective
- Palliation
  - Esophageal +/- airway stenting to reduce soilage

Doctors of Thoracic Surgery

Diagnosis

- Symptoms
  - Persistent Cough – initially dry
  - Postprandial Cough (Ono's sign)
  - Pneumonia: persistent or recurrent, same lobe
  - Purulent sputum
  - Ingested material in sputum
  - Fever/sepsis
  - Weight loss

UHN

Diagnostic workup

Bronchoscopy

- Airway location
- Size
- Distance from vocal cords/carina
- Airway inflammation or necrosis
- Need for stenting or airway control

Gastroscopy

- Esophageal opening
- Tumor, stricture, stent erosion
- Conduit viability after esophagectomy
- Feasibility of endoscopic closure or stenting

CT

- Defines leak/fistula tract
- Pneumonia/abscess/empyema
- Tumor?
- Mediastinal sepsis?

Doctors of Thoracic Surgery

Diagnostic workup

Bronchoscopy

- Airway location
- Size
- Distance from vocal cords/carina
- Airway inflammation or necrosis
- Need for stenting or airway control

Gastroscopy

- Esophageal opening
- Tumor, stricture, stent erosion
- Conduit viability after esophagectomy
- Feasibility of endoscopic closure or stenting

CT

- Defines leak/fistula tract
- Pneumonia/abscess/empyema
- Tumor?
- Mediastinal sepsis?

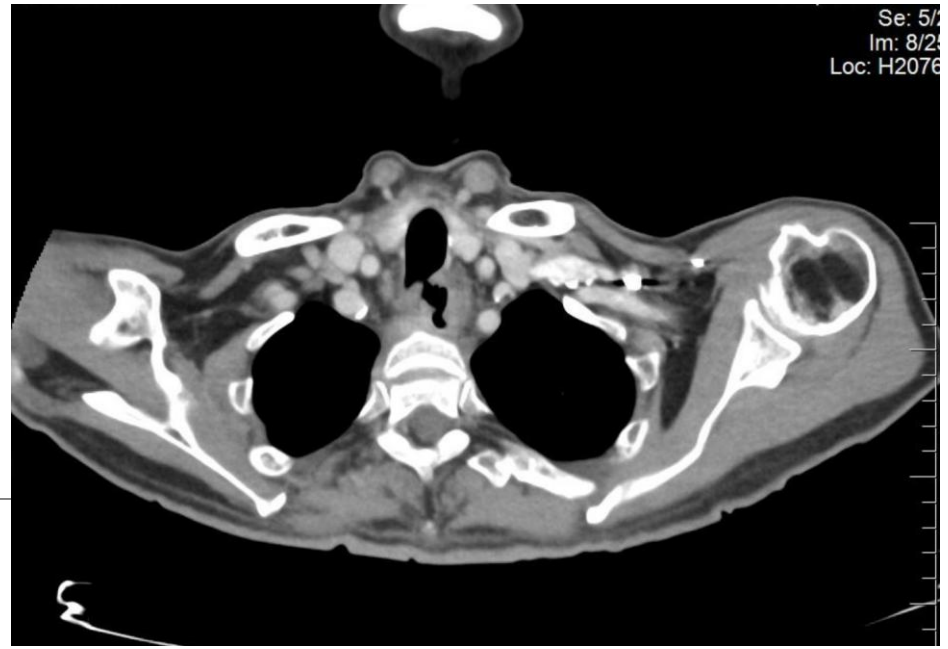

Doctors of Thoracic Surgery

Diagnostic workup

Bronchoscopy



Gastroscopy



UHN

Doctors of Thoracic Surgery

Principles of Management

- Stop pulmonary soilage
- Drain sepsis (source control)

- Respiratory support
- Nutritional support

- Antibiotics (broad spectrum, oral anaerobes, fungus)

- **Priority is to save the patient's life not the repair**
  - Resist the urge to do a repair in a septic/ARDS patient
  - Let the tissues heal/inflammation settle
  - Make it elective

UHN

Stop pulmonary soilage

- Stents
  - Usually metallic
  - Esophagus, bronchus, or both

Doctors of Thoracic Surgery

SEMS in LMB: hole not fully covered



But sufficient for stabilization!

UHN

Doctors of Thoracic Surgery

SEMS in LMB: hole not fully covered



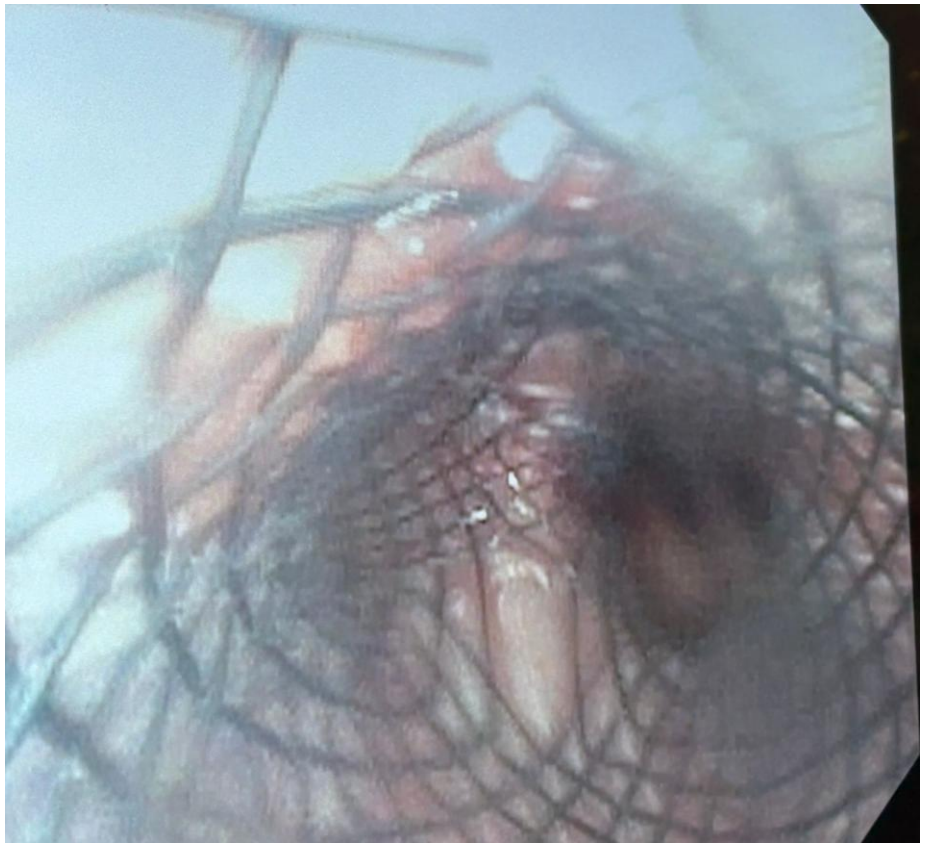

But sufficient for stabilization!

UHN

Doctors of Thoracic Surgery

Stents can slip, especially for high TEF



?Tracheal stent
?Tracheostomy

UHN

Minimally invasive palliative treatment of malignant tracheoesophageal fistula using cardiac septal occluder

Lin Teng[1] · Fei Zhou[1] · Xiaoqi Xiong[2] · Haoyu Zhang[2] · Linchen Qiao[2] · Zaiqiang Zhang[1] · Qin Qin[1] · Xinyu Song[2]

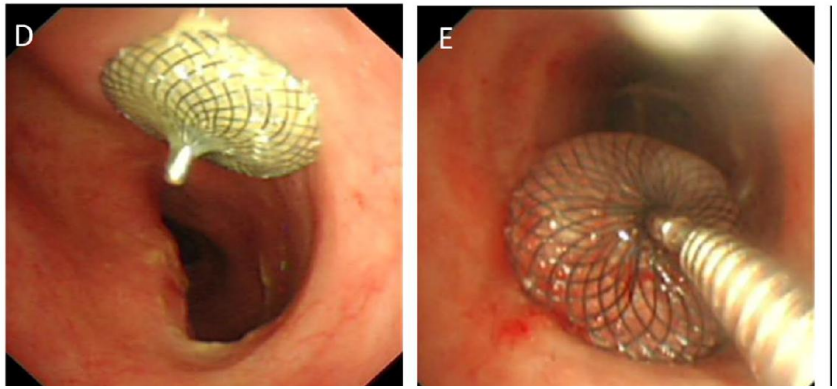



Teng et al.
2024 Langenbeck

Table 2 Selection of the occlude and post-operative follow up at 3-months

Patient number	occluder size(mm)	Endothelialization of the occluder	Sepsis Or lung infection	Complications	Nasal Feeding	Weight(kg)	Sur-vival
1	VSD(9)	completely	improve	None	NO	58	Yes
2	VSD(13)	completely	improve	None	NO	50	Yes
3	ASD(16)	partial	improve	None	NO	70	Yes
4	VSD(12)	completely	improve	None	NO	59	Yes
5	VSD(9)	completely	improve	None	NO	62	Yes
6	VSD(11)	completely	improve	None	NO	65	Yes
7	VSD(13)	completely	improve	None	NO	54	Yes
8	ASD(14)	partial	improve	None	NO	66	Yes

Successful Closure of a Benign Refractory Tracheoesophageal Fistula Using an Over-the-Scope Clip after Failed Esophageal Stent Placement and Surgical Management

Nonthalee Pausawasdi[1], Chotirot Angkurawaranon[1], Tanyaporn Chantarojanasiri[1], Arunchai Chang[1], Wanchai Wongkornrat[2], Somchai Leelakusolvong[1] and Asada Methasate[1,3]

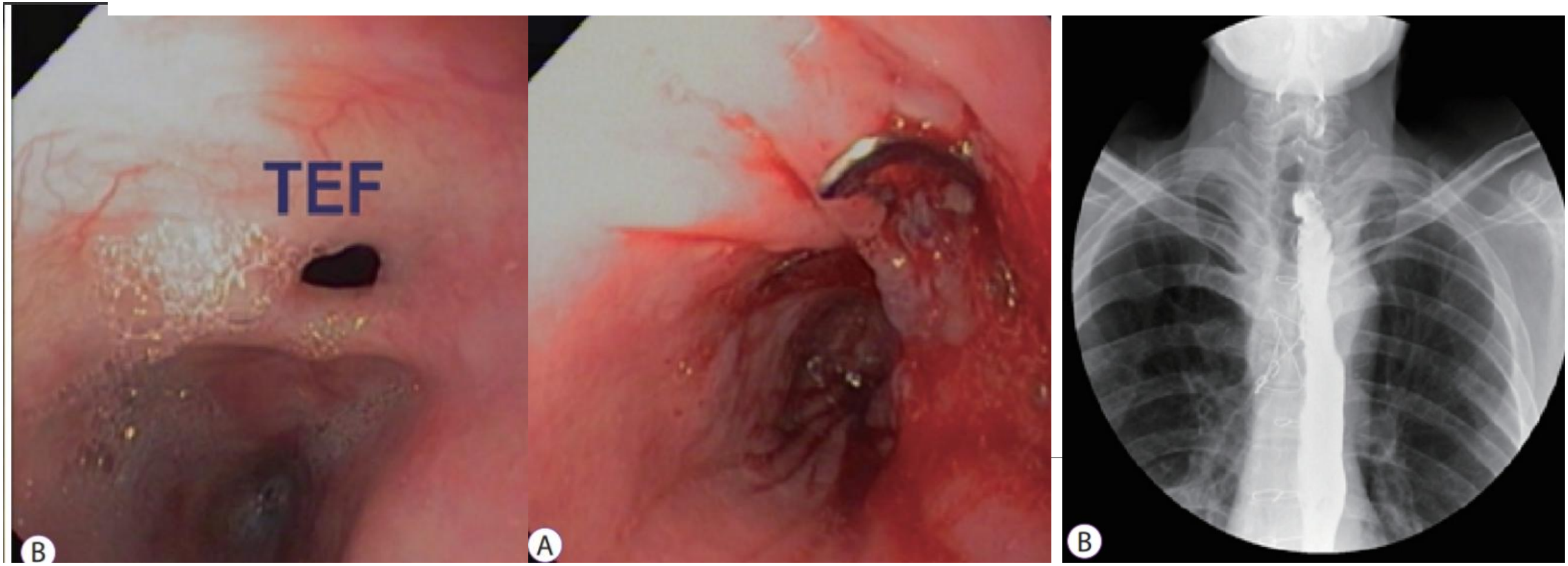

Surgical Treatment of Nonmalignant Tracheoesophageal Fistula: A Thirty-Five Year Experience

Ashok Muniappan, MD, John C. Wain, MD, Cameron D. Wright, MD, Dean M. Donahue, MD, Henning Gaissert, MD, Michael Lanuti, MD, and Douglas J. Mathisen, MD

Division of Thoracic Surgery, Massachusetts General Hospital, Boston, Massachusetts

- N=38
  - Post intubation injury 47%, trauma 17%, laryngectomy 17%, post-esophagectomy 11%
- Tracheal Repairs
  - Resection and reconstruction of trachea or laryngotrachea 53%
  - Membranous tracheal repair 41%
  - Repair over T-tube 5%
- Esophageal Repairs
  - 2 layer 78%, 1 layer 15%, end-to-end 3%, full thickness skin graft 3%
- Outcomes
  - 94% closure, 83% oral intake, 71% breathing without appliance

Principles of Management

- Stop pulmonary soilage
- Drain sepsis (source control)

- Respiratory support
- Nutritional support

- Antibiotics (broad spectrum, oral anaerobes, fungus)

- **Priority is to save the patient's life not the repair**
  - Resist the urge to do a repair in a septic/ARDS patient
  - Let the tissues heal/inflammation settle
  - Make it elective

- Usually – separate esophagus from airway, resection of epithelialized fistula, closure, and vascularized tissue interposition

Doctors of Thoracic Surgery

Case Presentation

- 58yo M SCC esophagus, McKeown esophagectomy
- 13mo after discharge

- ER consult 9pm
  - Odynophagia, hypotension, hypoxia
  - Bad pneumonia
  - CT shows fistula



UHN

Doctors of Thoracic Surgery

Case #1

- OR 0100h
- Fiberoptic intubation
- OGD, Bronch, Biopsy
- Very sick
  - FiO2 90%
  - 3 pressors
- Rapid **source control**
  - NG drainage
  - Balloon over hole
- To ICU

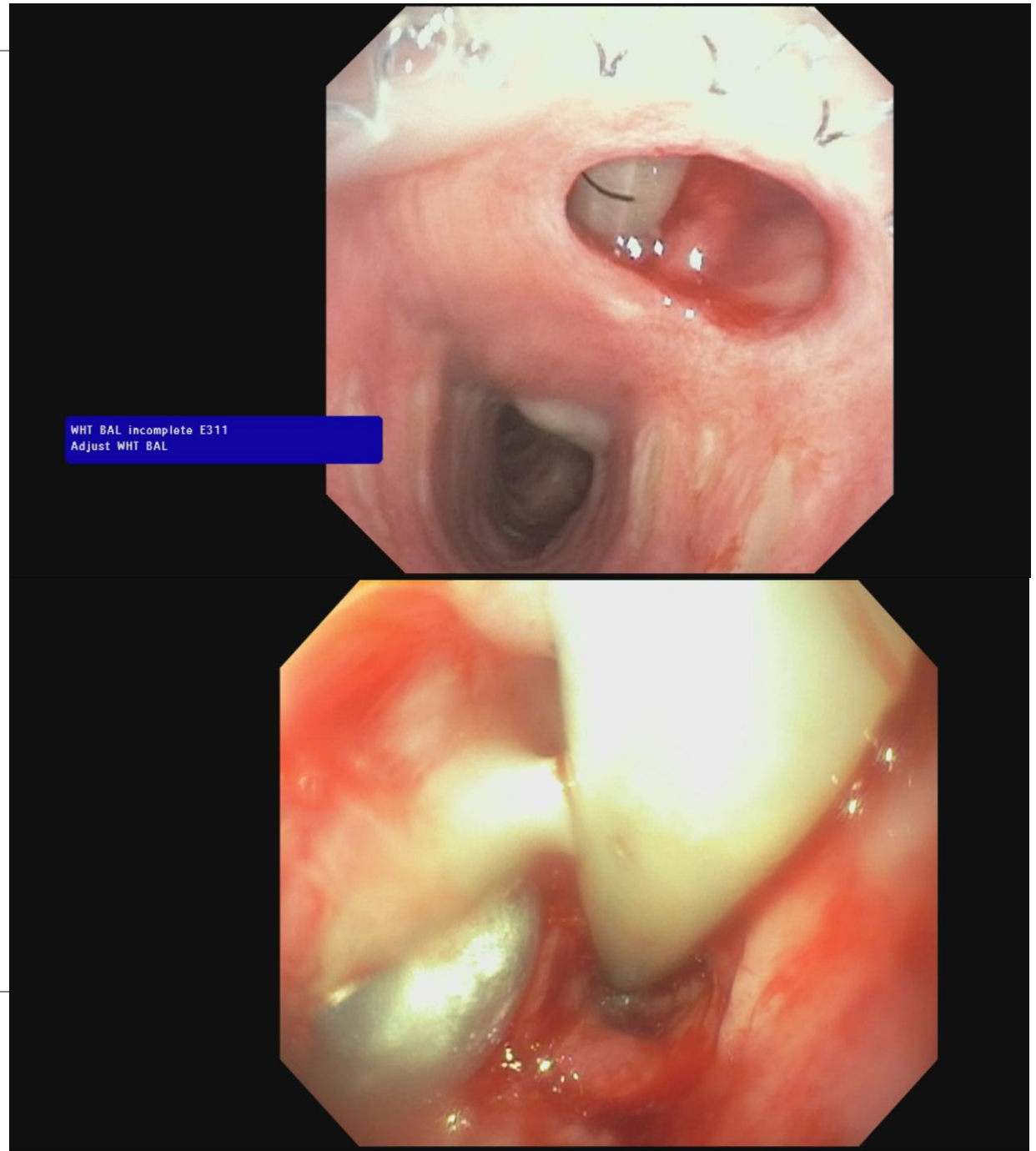

Case #1

- POD4
  - FiO2=0.5, off pressors
  - Rigid bronch
    - 16x40 fully covered tracheal stent
  - Open feeding jej

Case #1

- 5 more weeks in ICU
  - Source control adequate
    - Daily -> twice weekly bronchoscopy
- Definitive treatment
  - Borderline lung function – unlikely to tolerate cross-field ventilation
    - VV-ECMO
  - Tracheal resection
  - Interposition with thymus

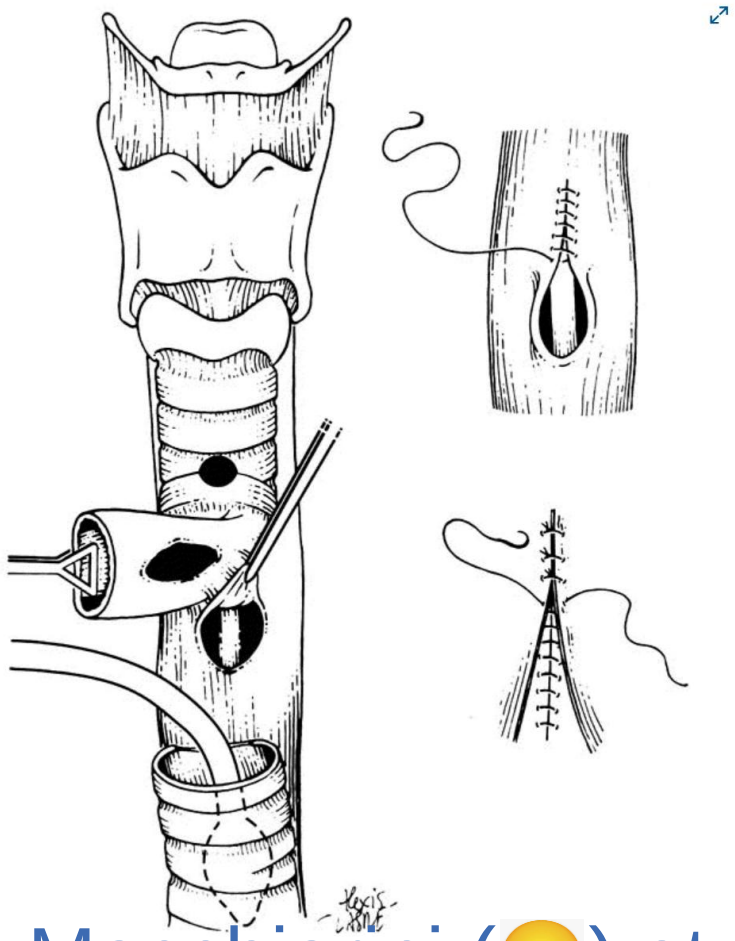

Macchiarini (😬) et al 2000

Doctors of Thoracic Surgery



UHN

Doctors of Thoracic Surgery



UHN

Doctors of Thoracic Surgery

Post-repair

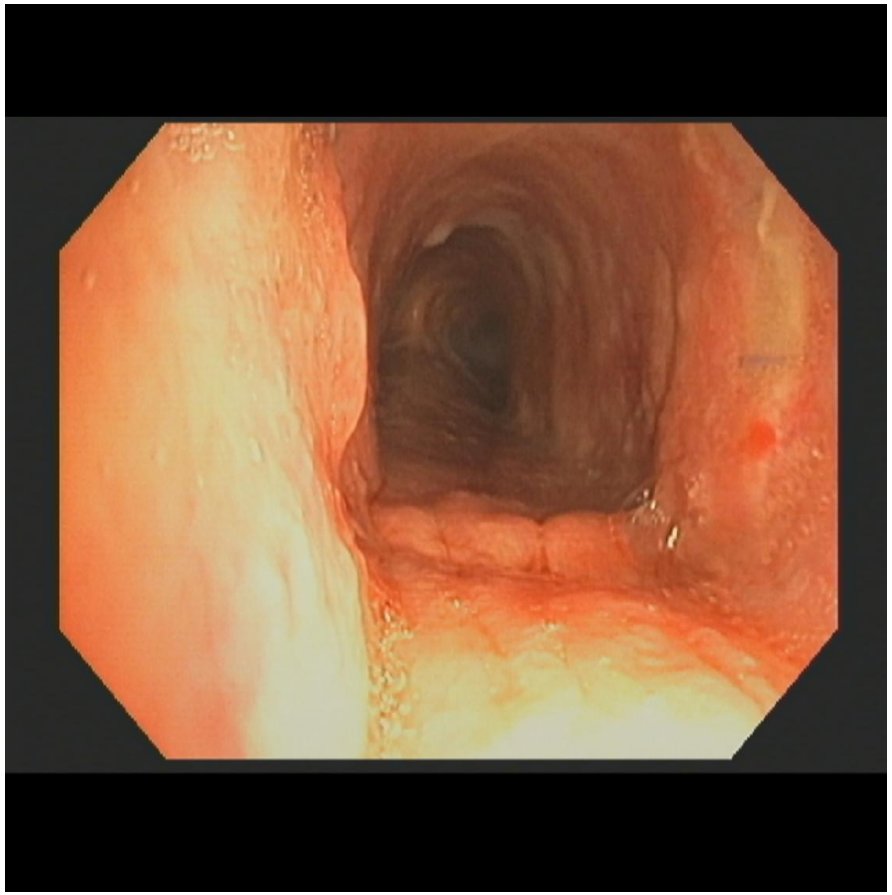

UHN

Doctors of Thoracic Surgery

Post-Esophagectomy Tracheoesophageal Fistula

- Etiology
  - Anastomotic leak
  - Anastomotic leak
  - Anastomotic leak

  - Intraoperative airway injury: energy devices
  - Esophageal dilation

  - Location: distal trachea, proximal LMB, RMB

  - Pathophysiology: undrained sepsis

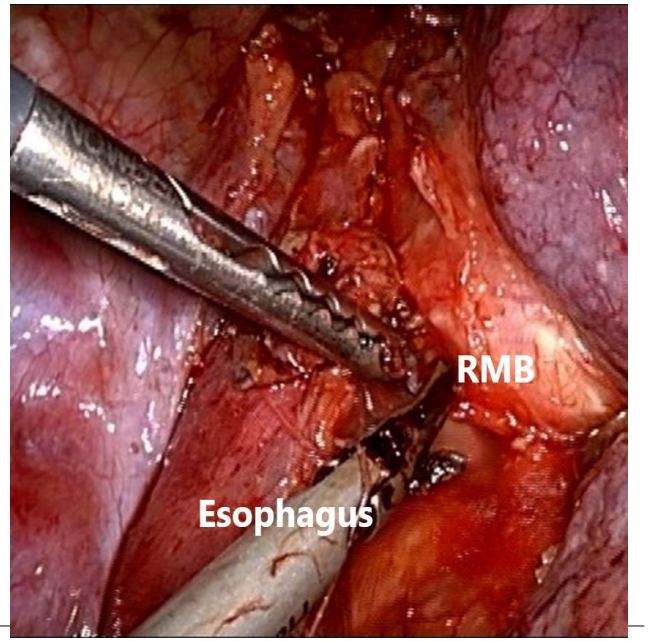

UHN

Doctors of Thoracic Surgery

Anastomotic Leak → TEF

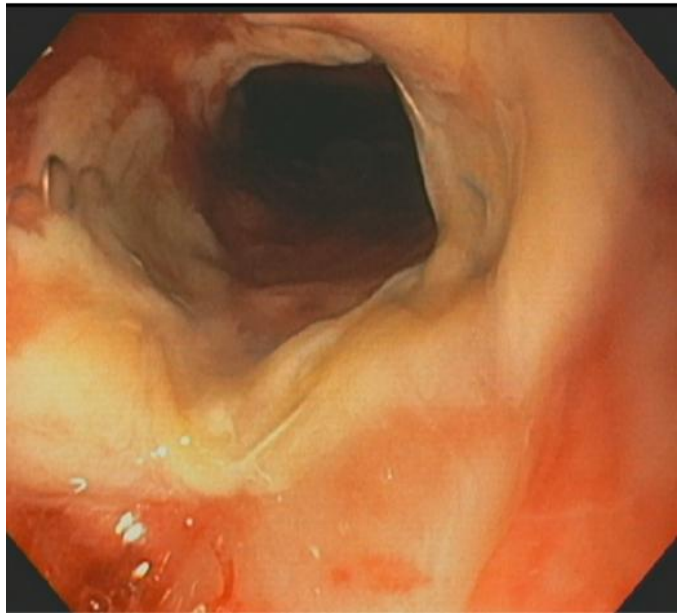

←?

Day 4

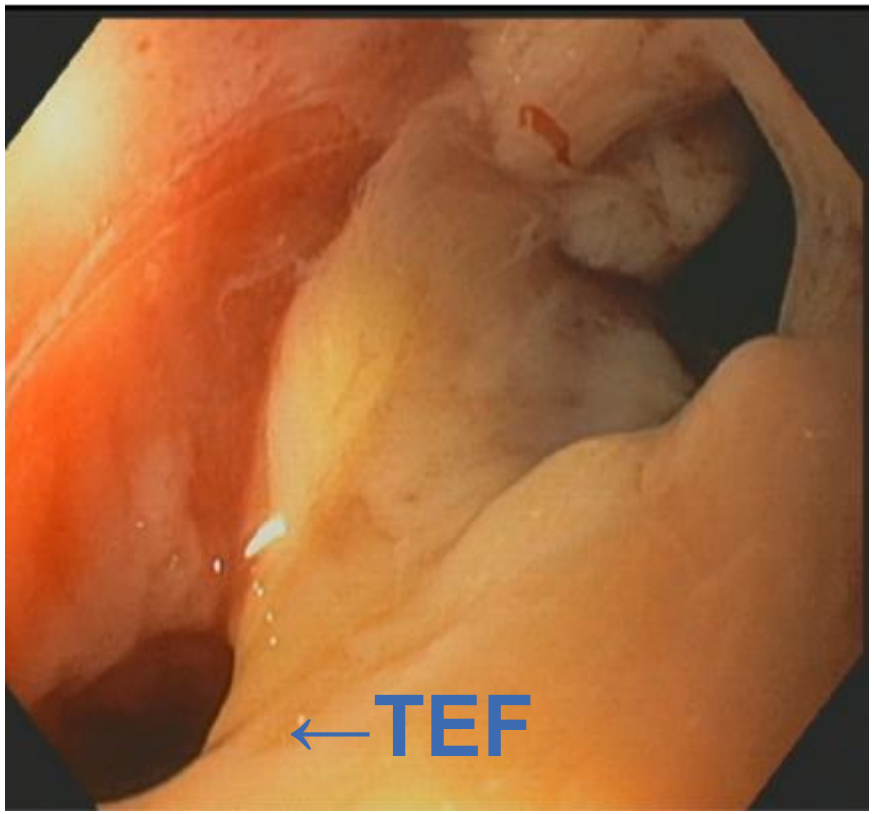

Day 7

UHN

Doctors of Thoracic Surgery

Contributing factors

- Nutrition
- Pre-op radiation
- Sepsis
- ? Lymphadenectomy with devascularization of airway

UHN

Doctors of Thoracic Surgery

Investigations

- High degree of suspicion
- Clues:
  - CXR: Hydropneumothorax – where does the air come from?
  - CXR: persistent pulmonary infiltrates
  - CT Chest: to assess for undrained collections, mediastinal air
- Bronchoscopy to identify fistula

UHN

Doctors of Thoracic Surgery

Not just secretions!





UHN

Doctors of Thoracic Surgery

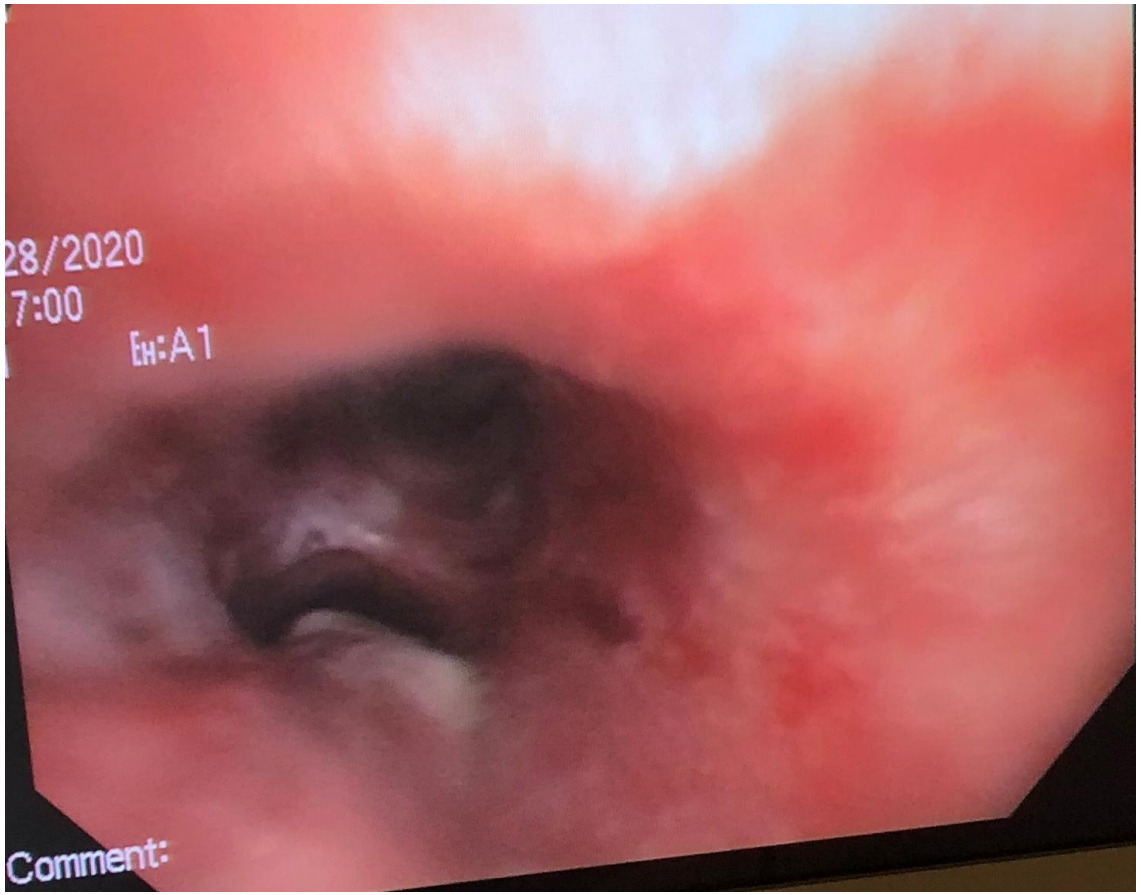

UHN

Doctors of Thoracic Surgery

Principles of Management

- Stop pulmonary soilage (control sepsis)
  - Stent esophagus
    - Ease of placement, conscious sedation
    - Conduit is big (incomplete seal, ongoing leak)
  - Stent airway
    - Metal stents – migrate easily
    - May need Y-stent for distal trachea
    - Interferes with ET tube
  - Distal ET tube/double lumen
    - Difficult to place for distal holes, precludes toilet
  - Divert esophagus: cervical esophagostomy, take down of conduit
    - Too sick?
    - What to do about hole in airway?
  - NG tube
    - Doesn’t capture everything

UHN

Case example

- 81yo man, CABG, colectomy
- Open Ivor Lewis esophagectomy
  - POD 14 leak into pleural space, **stented**
  - POD 21 ongoing leak, **another stent**
  - POD 45 right mainstem defect
  - Feeding J in place
  - Transferred for management

Doctors
of Thoracic
Surgery

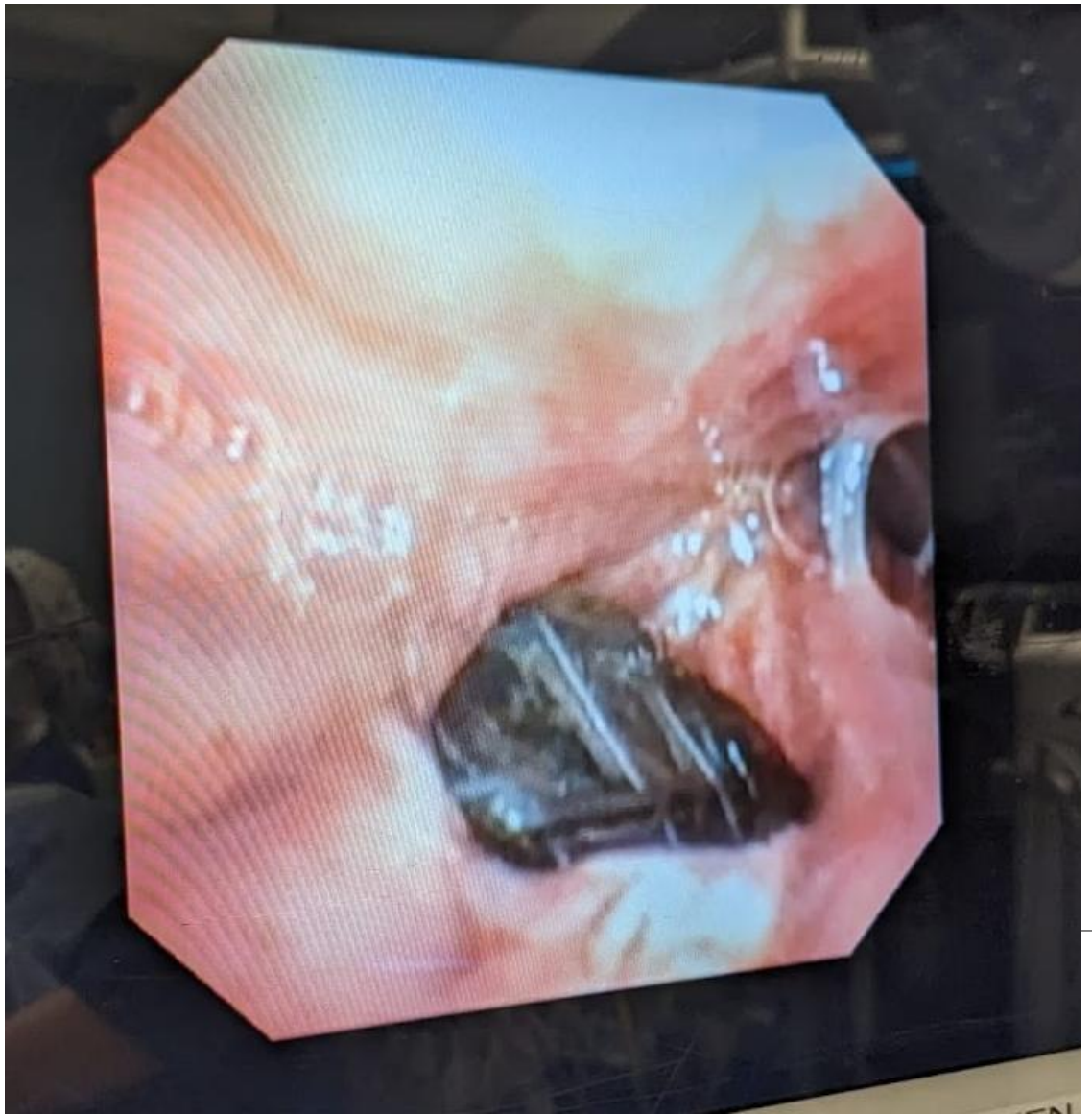



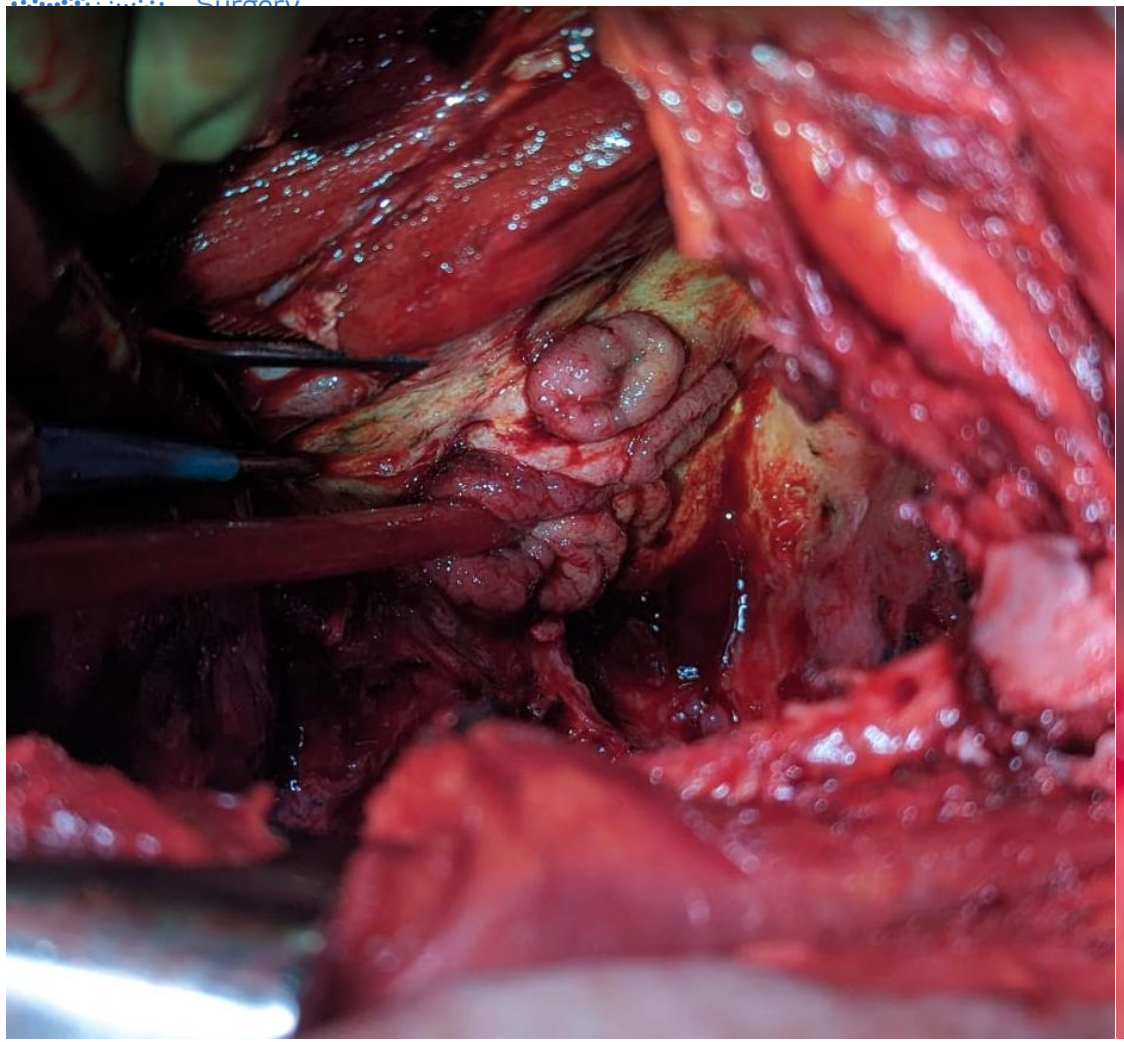

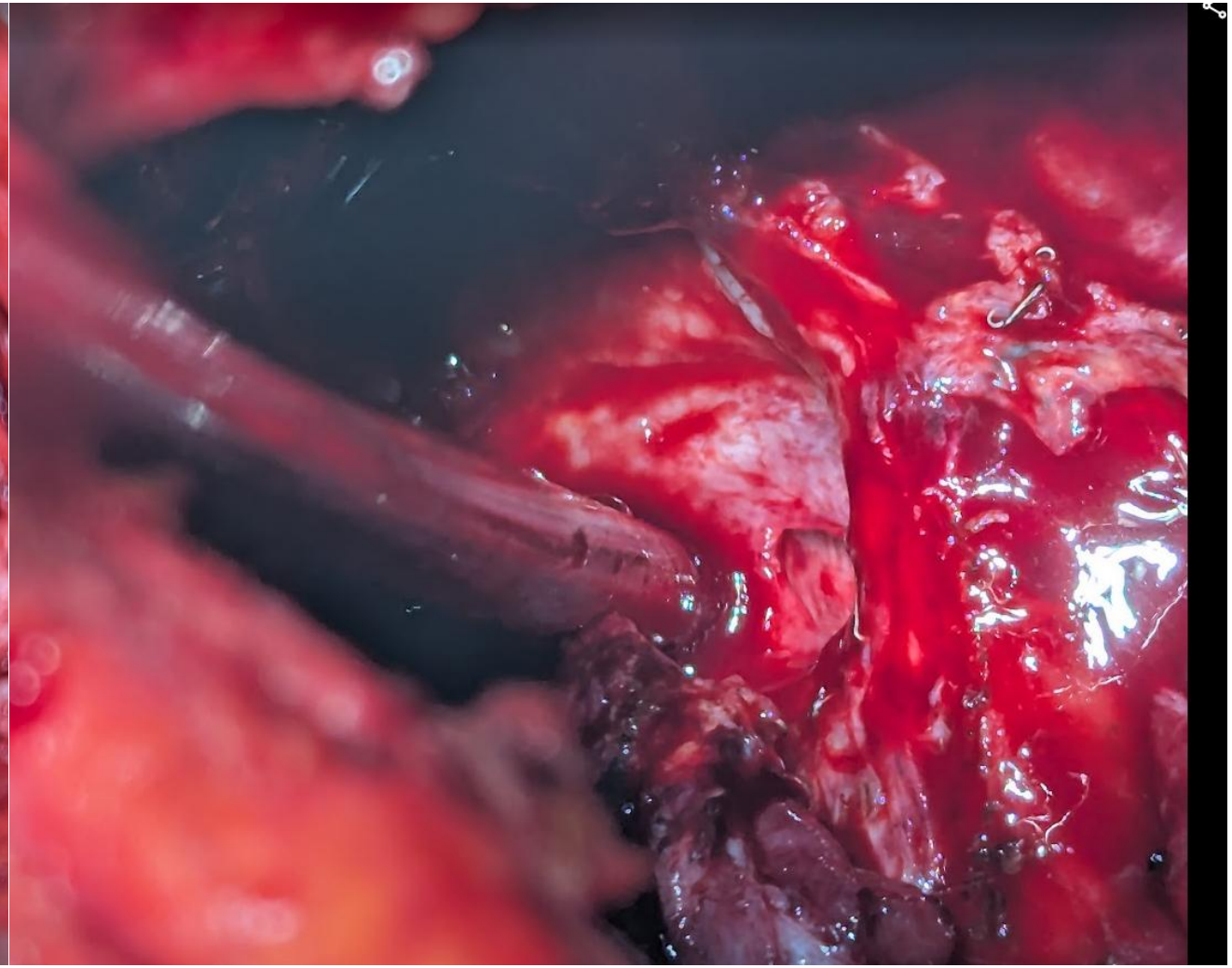

Doctors of Thoracic Surgery





UHN

Doctors of Thoracic Surgery

Case example

- Spit fistula
- Intercostal muscle flap
- Need for positive pressure ventilation post-op

UHN

Doctors of Thoracic Surgery

Case example

- POD 4
  - New bubbling from chest tube
  - Sepsis, persistent fistula
  - Death POD 8



Doctors of Thoracic Surgery

Principles of Management

- Stop pulmonary soilage (control sepsis)
  - Stent esophagus
    - OK, but waited too long
- Divert esophagus: cervical esophagostomy, take down of conduit
  - Divert once stable
- Hole in airway
  - No great flaps (latissimus cut, serratus won't reach)
- Positive Pressure Ventilation
- 80

UHN

Multidisciplinary management of a complex case of postesophagectomy tracheoesophageal fistula

Aitua C. Salami, MD, MPH,[a] Ilitch Diaz-Gutierrez, MD,[b] Amit Bhargava, MD, MHA,[b] Rafael Andrade, MD, MHA,[b] and Madhuri V. Rao, MD,[b] Dallas, Tex, and Minneapolis, Minn

- 62yo woman ILE
  - Leak and fistula

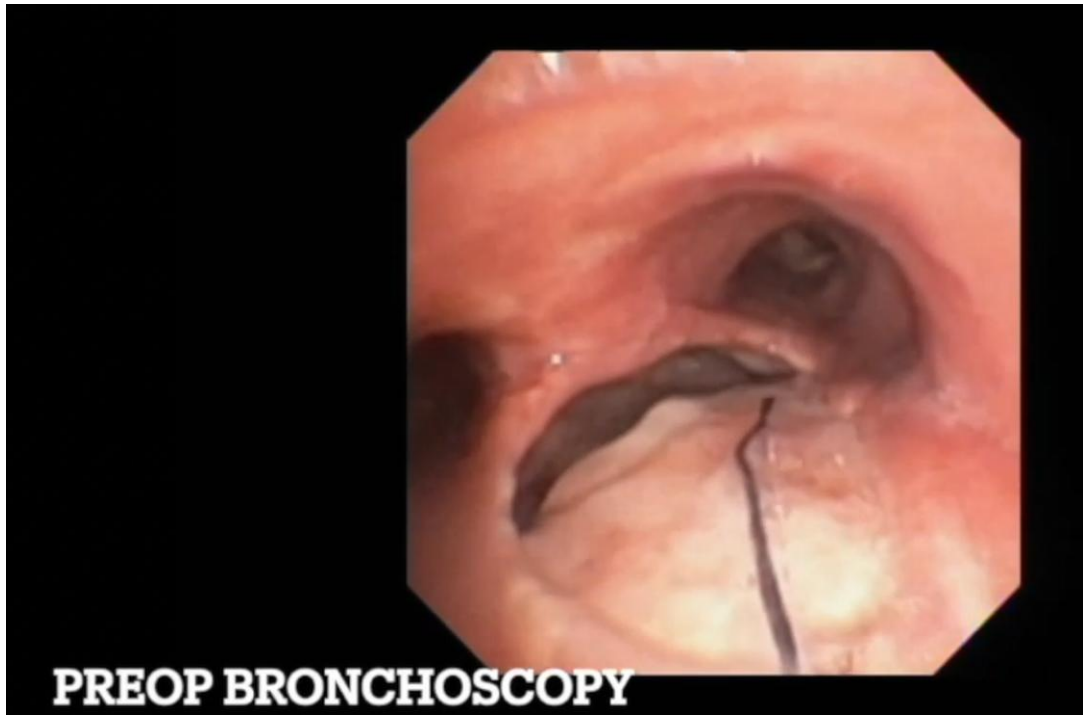

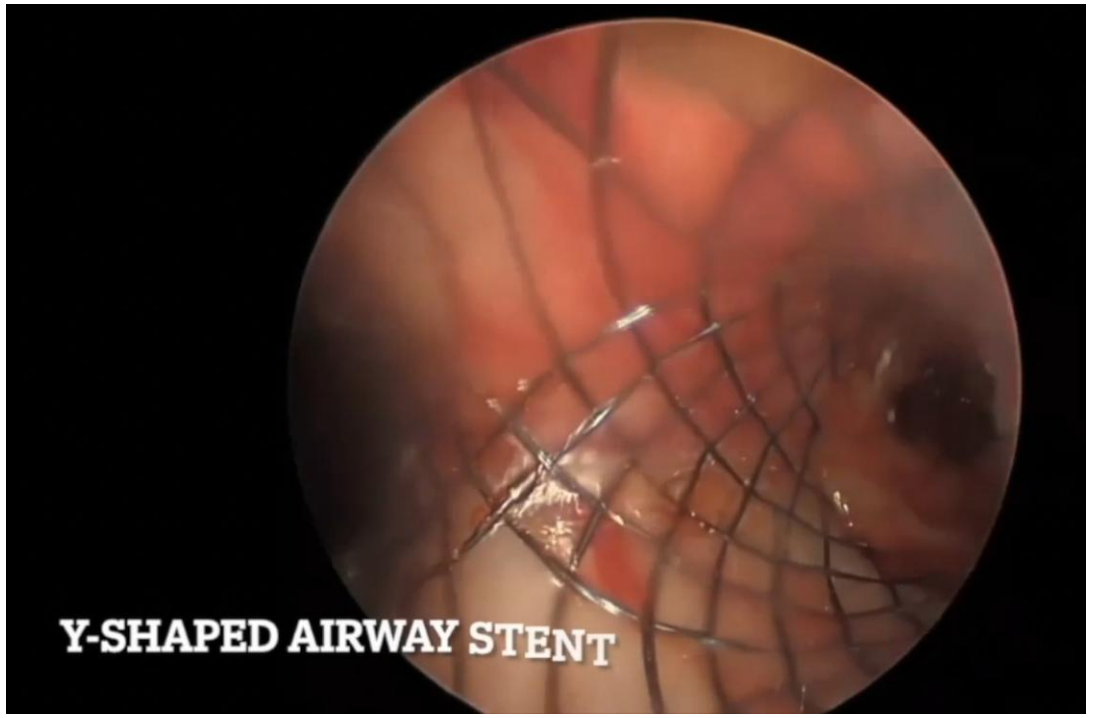

Salami et al

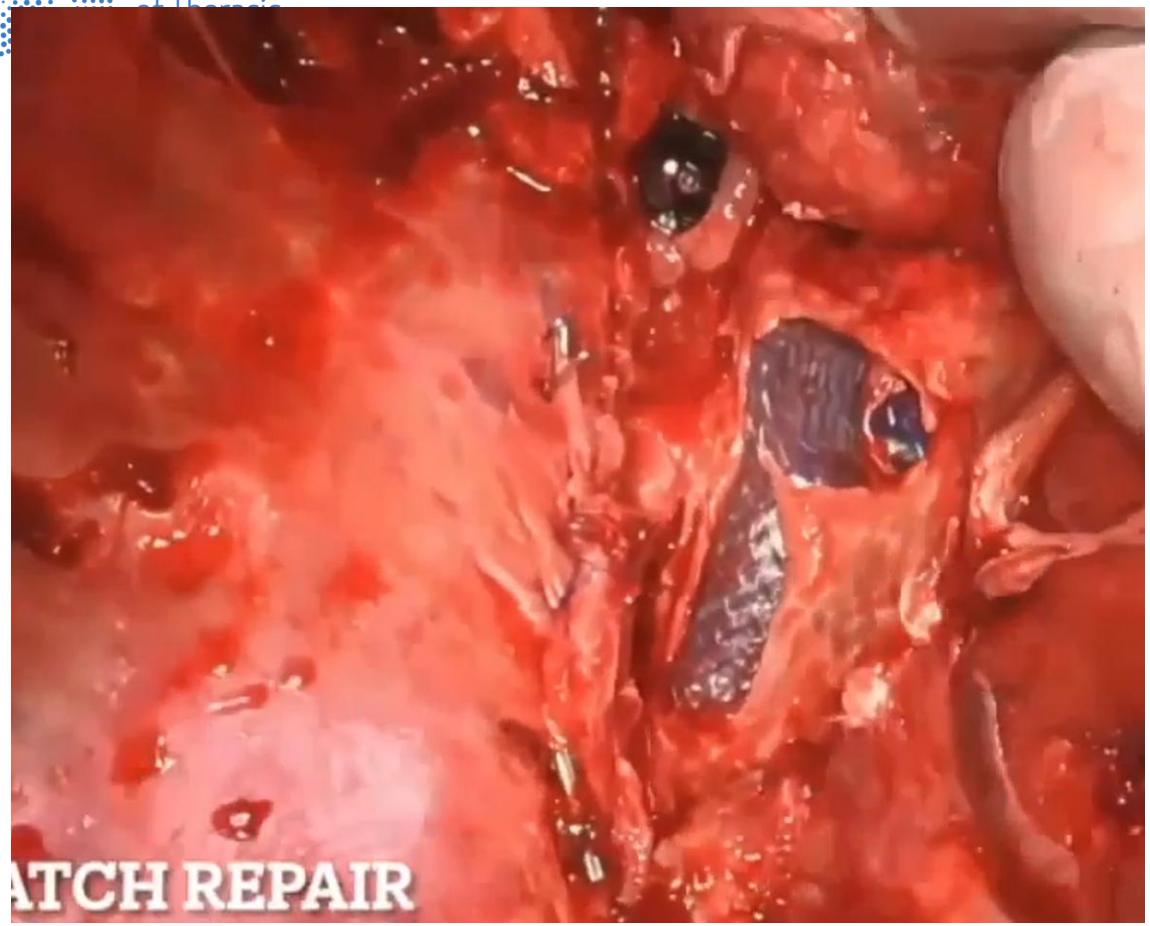

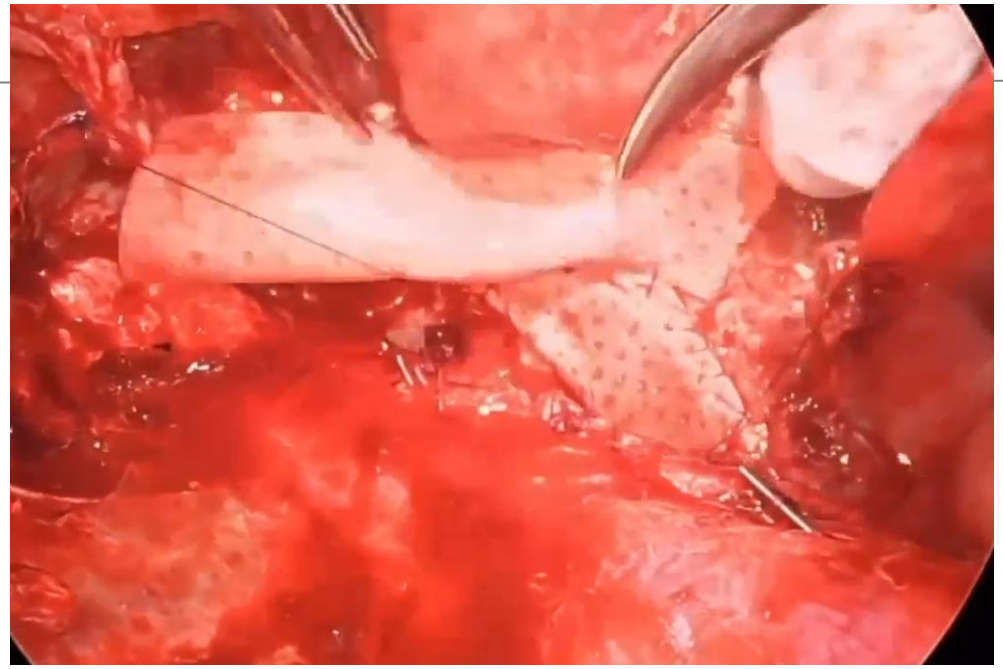

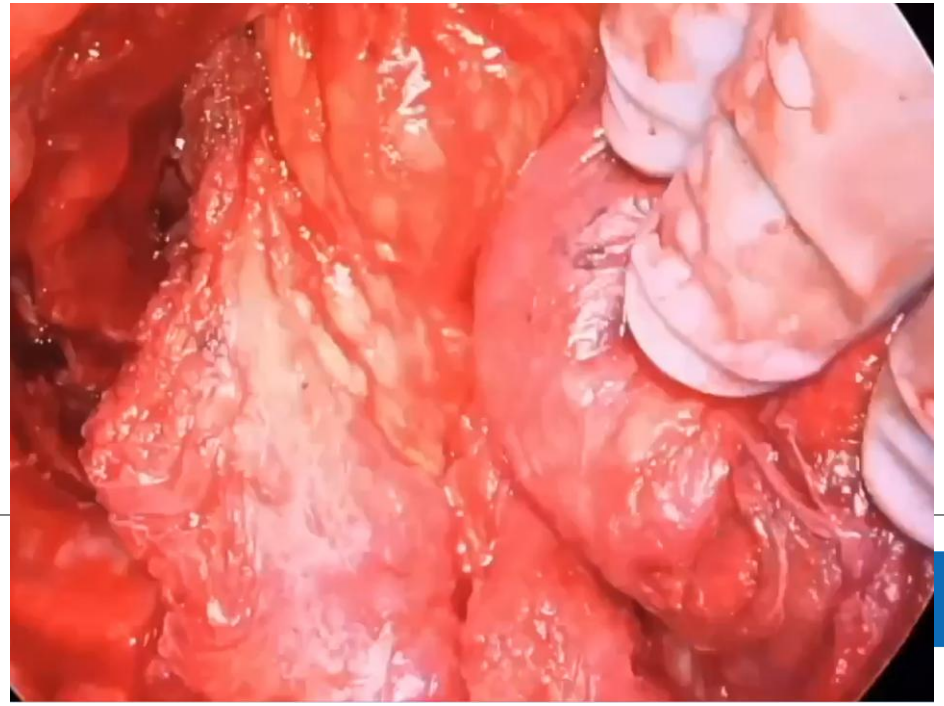

Salami et al

Doctors of Thoracic Surgery



UHN

The long segment TEF – Case example

- 40M
- SCC upper esophagus
- Brachytherapy and external beam – total 95G equivalent
- Large TEF, high esophageal stent
- Referred to TGH

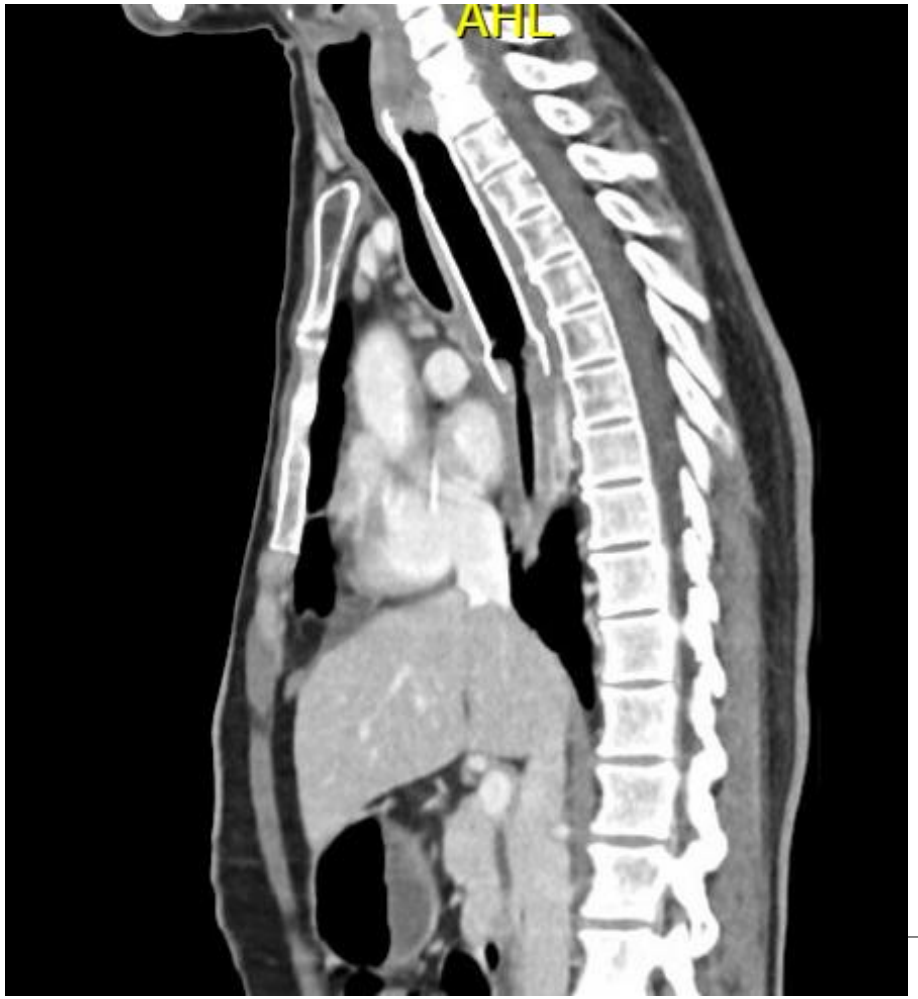
AHL

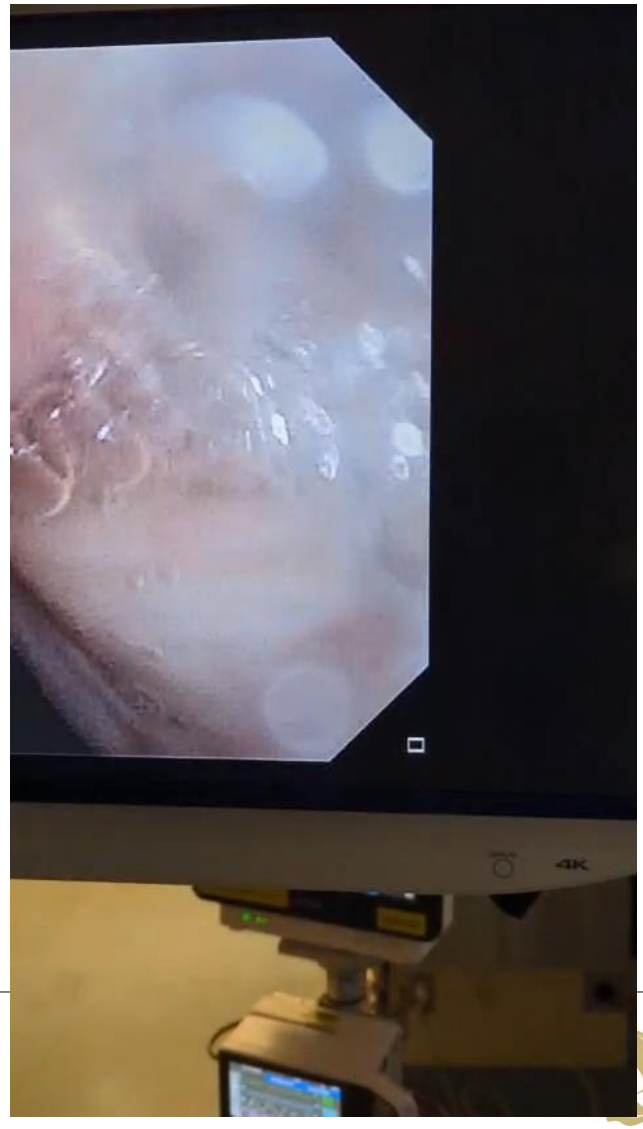

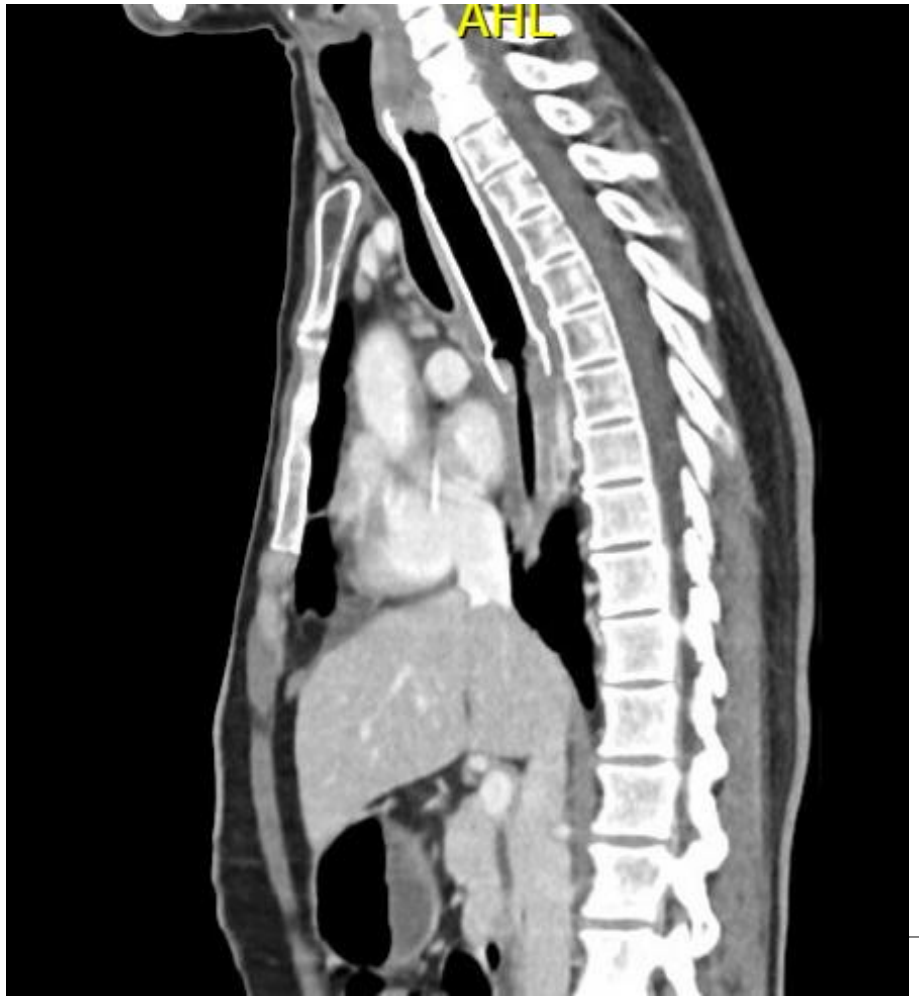

Occluded UES from stent
Rigid radiated esophagus
Rigid radiated trachea

Cannot do LPE
Cannot separate trachea from esophagus

Doctors of Thoracic Surgery

Repair Strategy – VV ECMO +

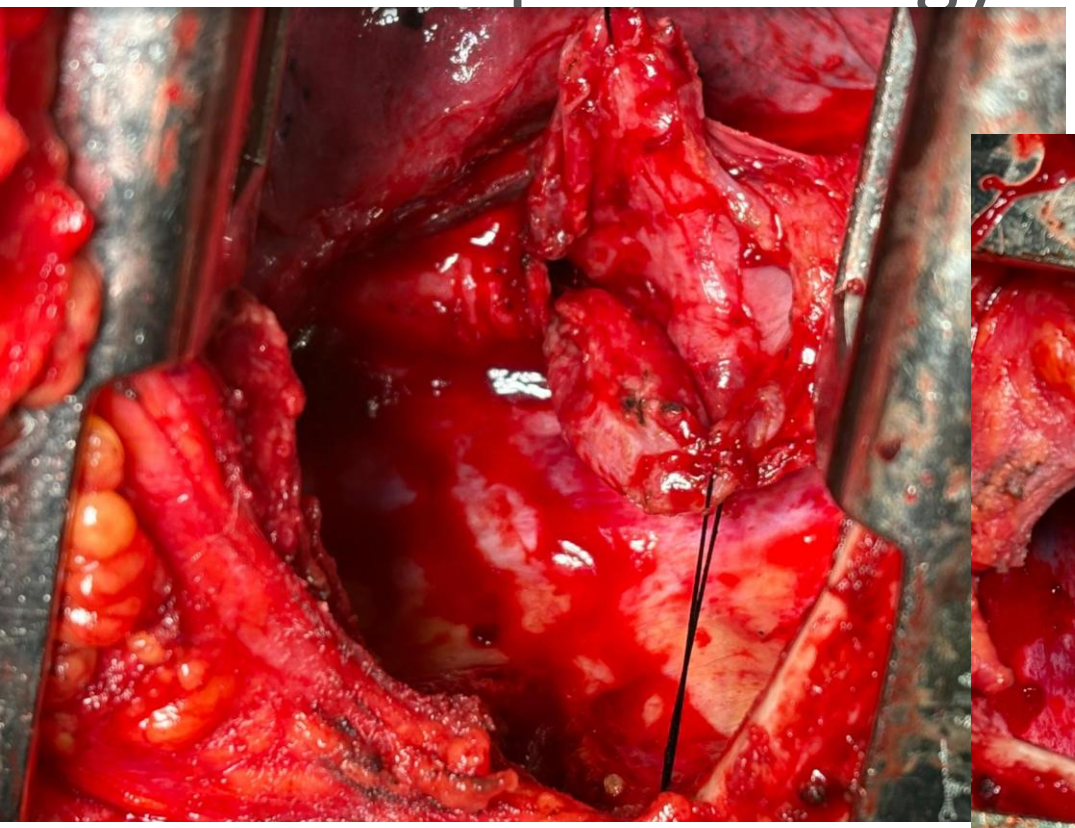

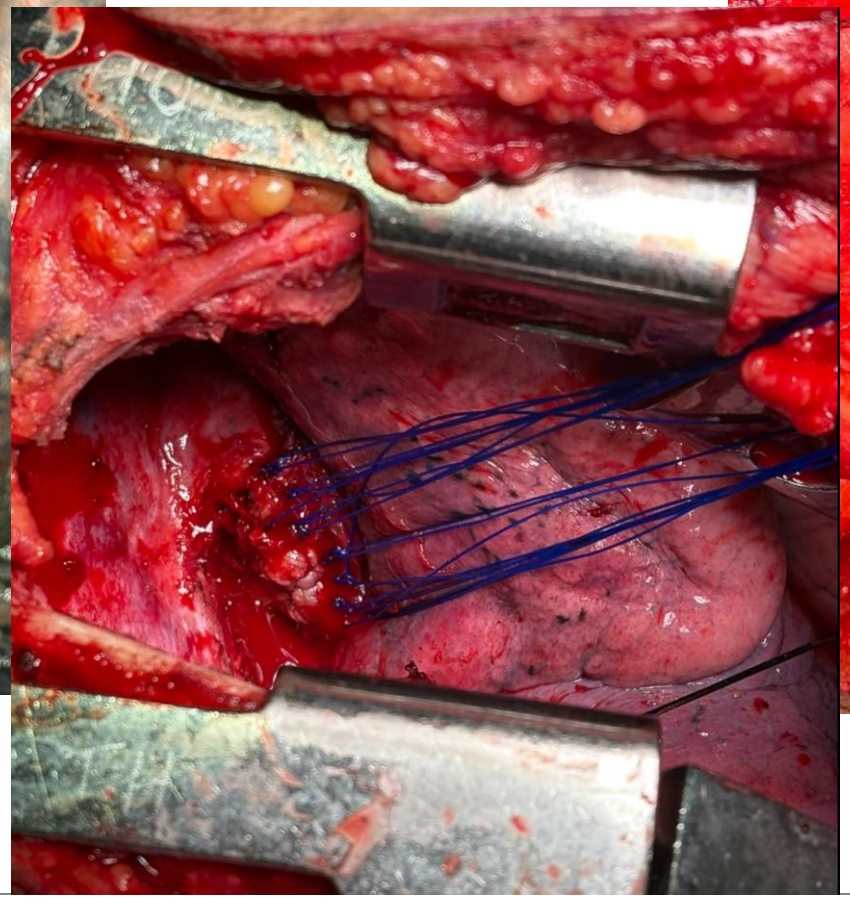

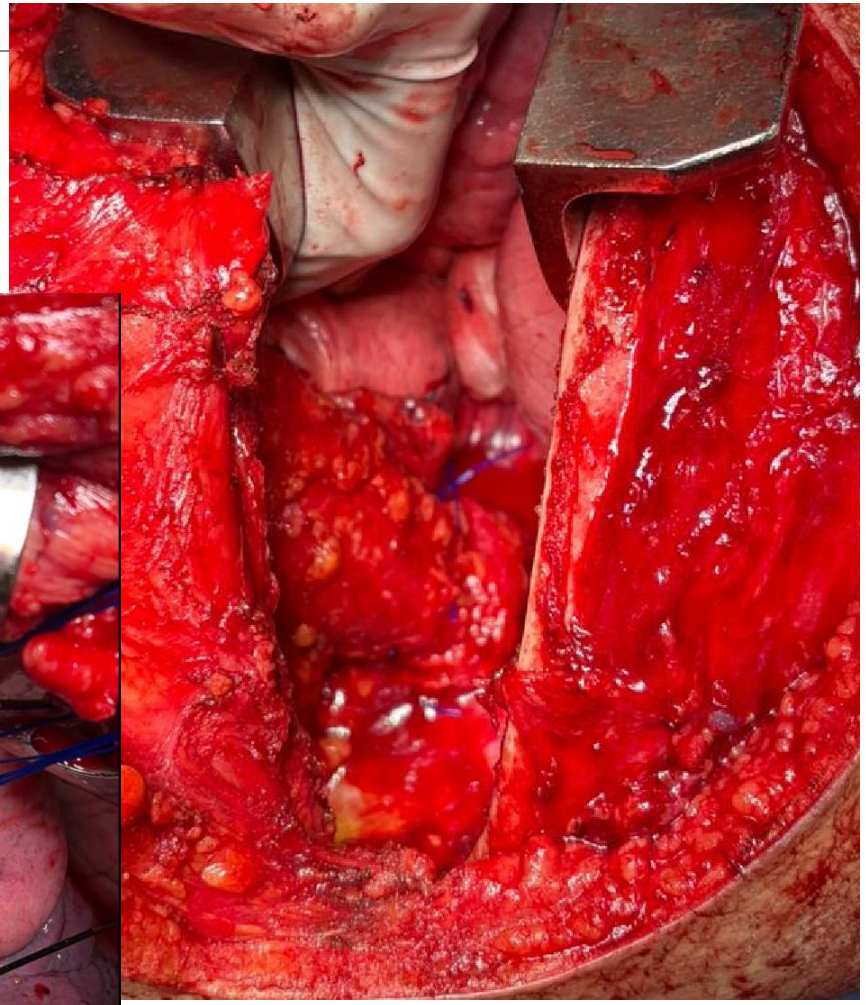

Avoid positive pressure

21 days on VV ECMO

UHN

Doctors of Thoracic Surgery

Free flap – neopharyngoesophageal junction (R. Gilbert)

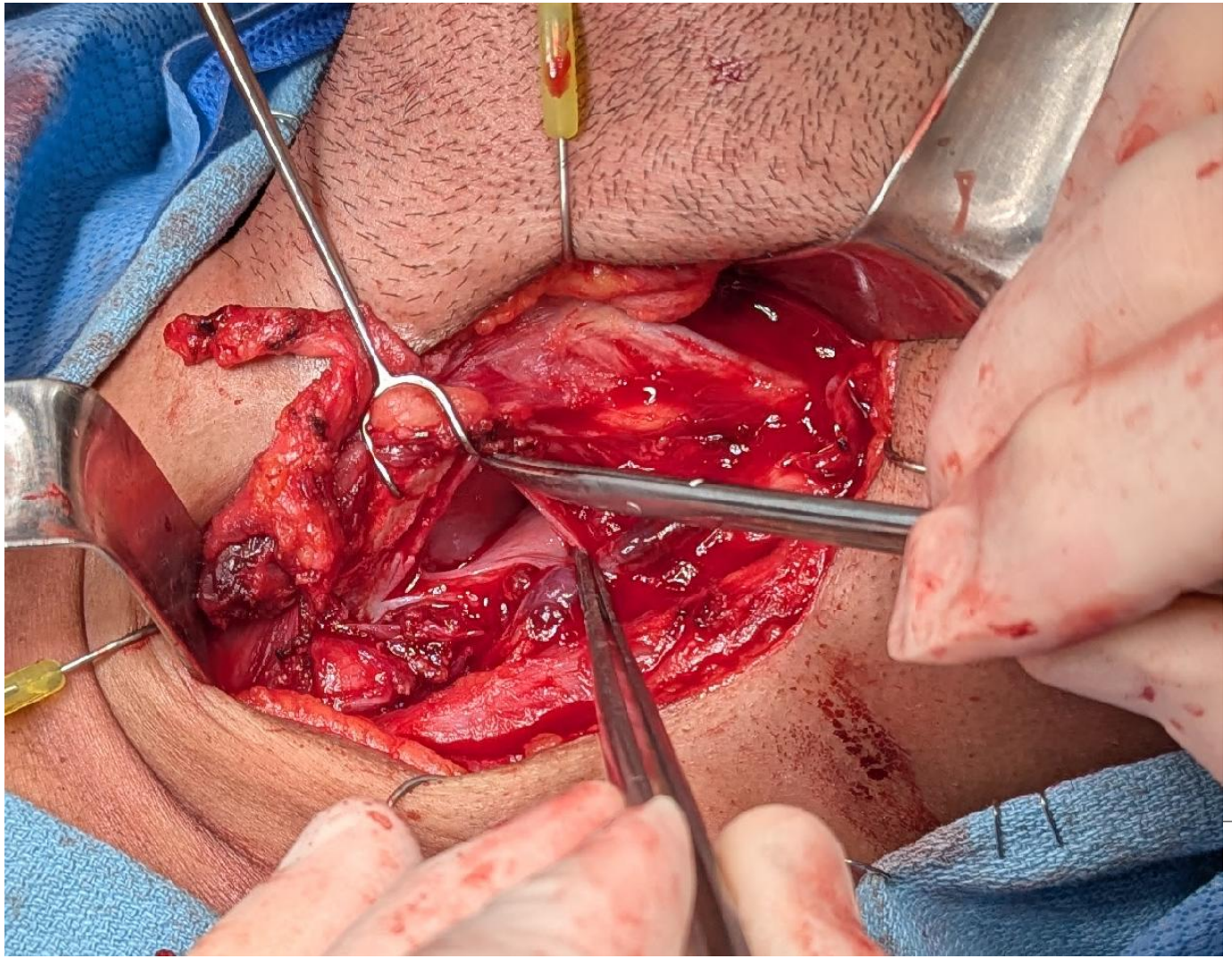

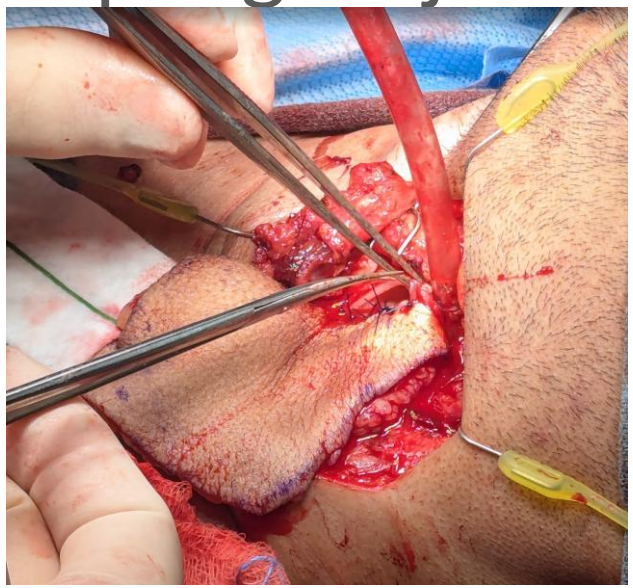

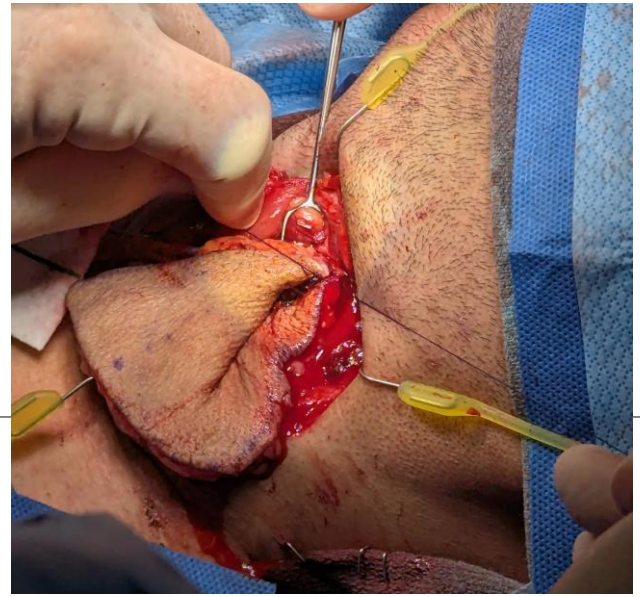

UHN

Doctors of Thoracic Surgery

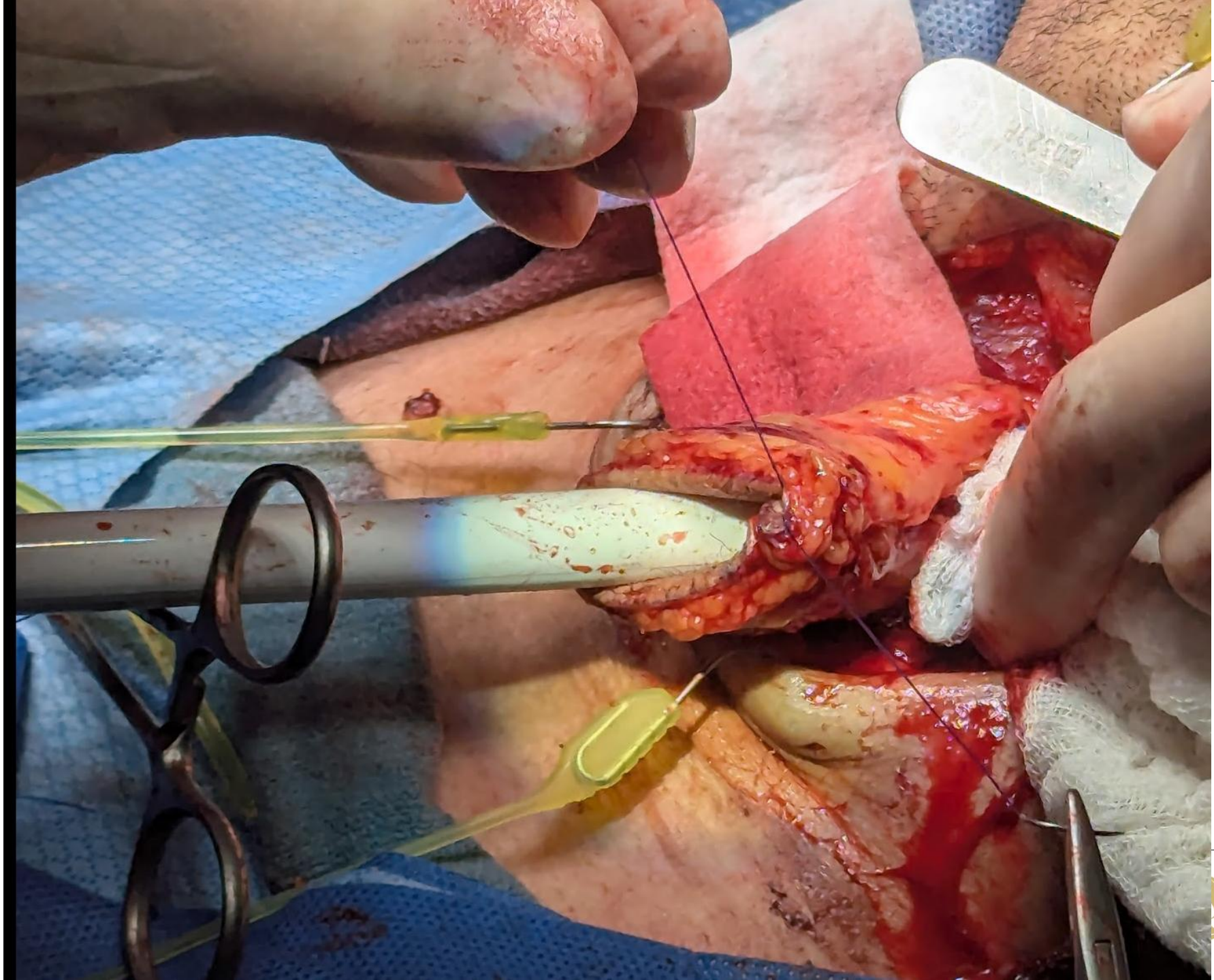

UHN

Doctors of Thoracic Surgery



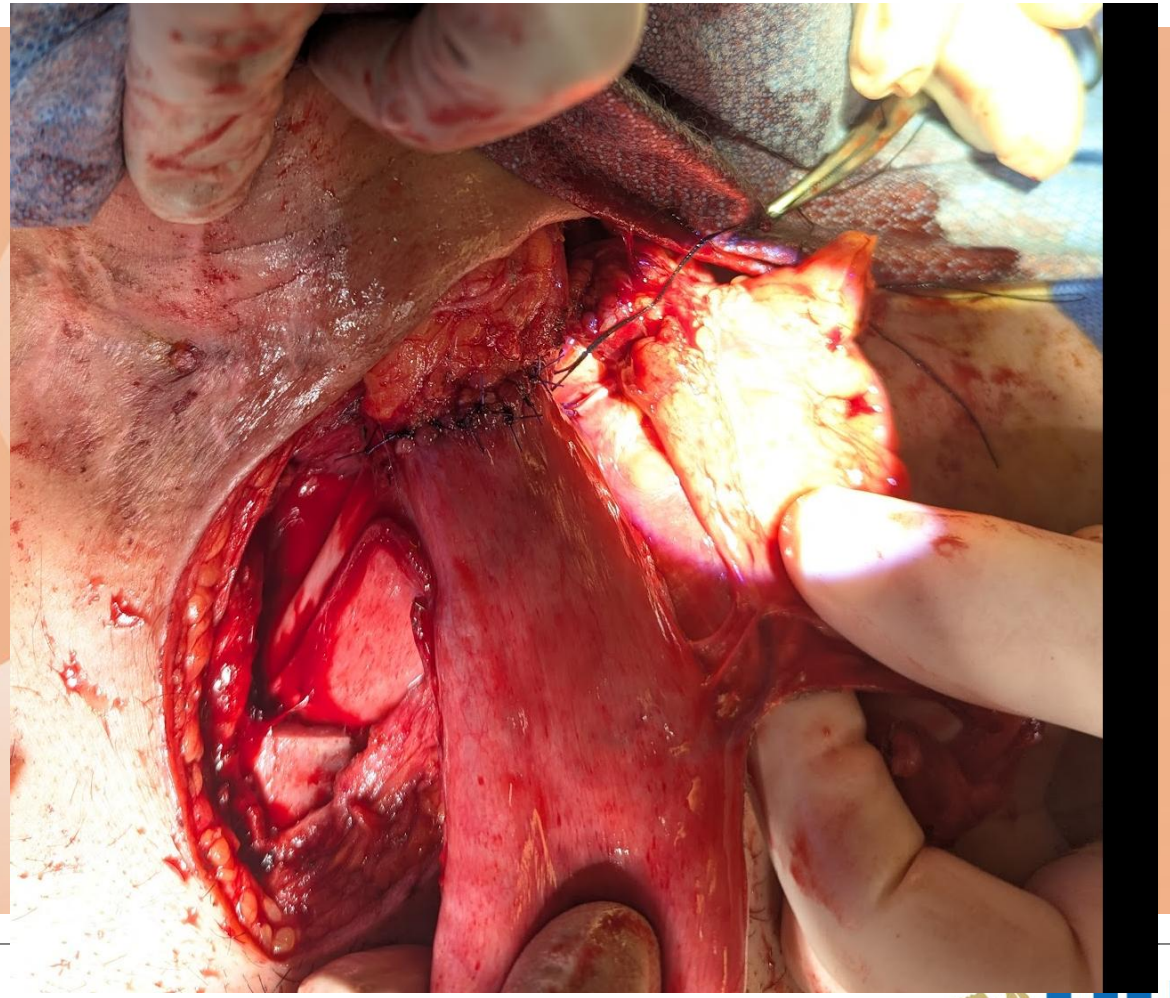

UHN

Doctors of Thoracic Surgery

Post-repair appearance



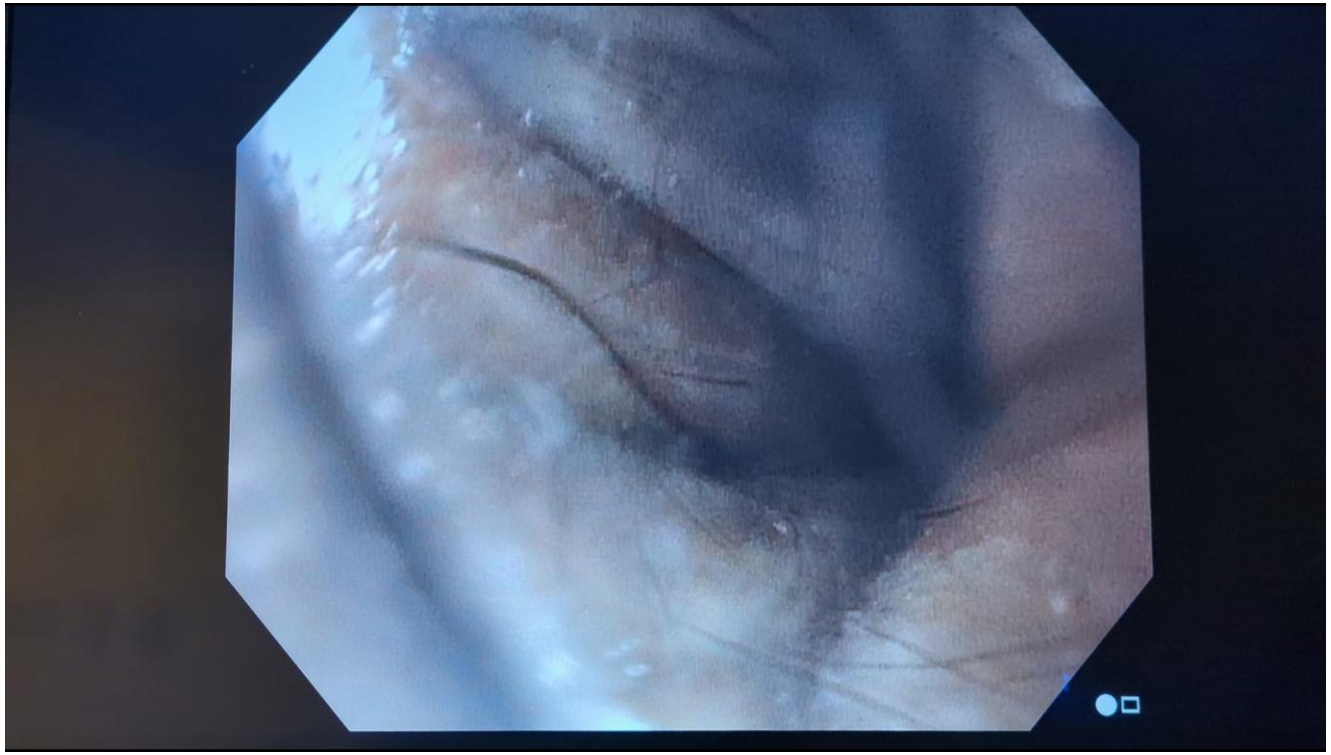

UHN

Salvage repair with esophagus-conduit segment in situ as a neo-posterior tracheal wall for multiple tracheoesophageal and trachea-conduit fistulas: a case report

Ying Jie Cui
Chungnam National University Hospital, Chungnam National University School of Medicine
Hyunjin Cho
irainy79@naver.com

In press

Chungnam National University Hospital, Chungnam National University School of Medicine

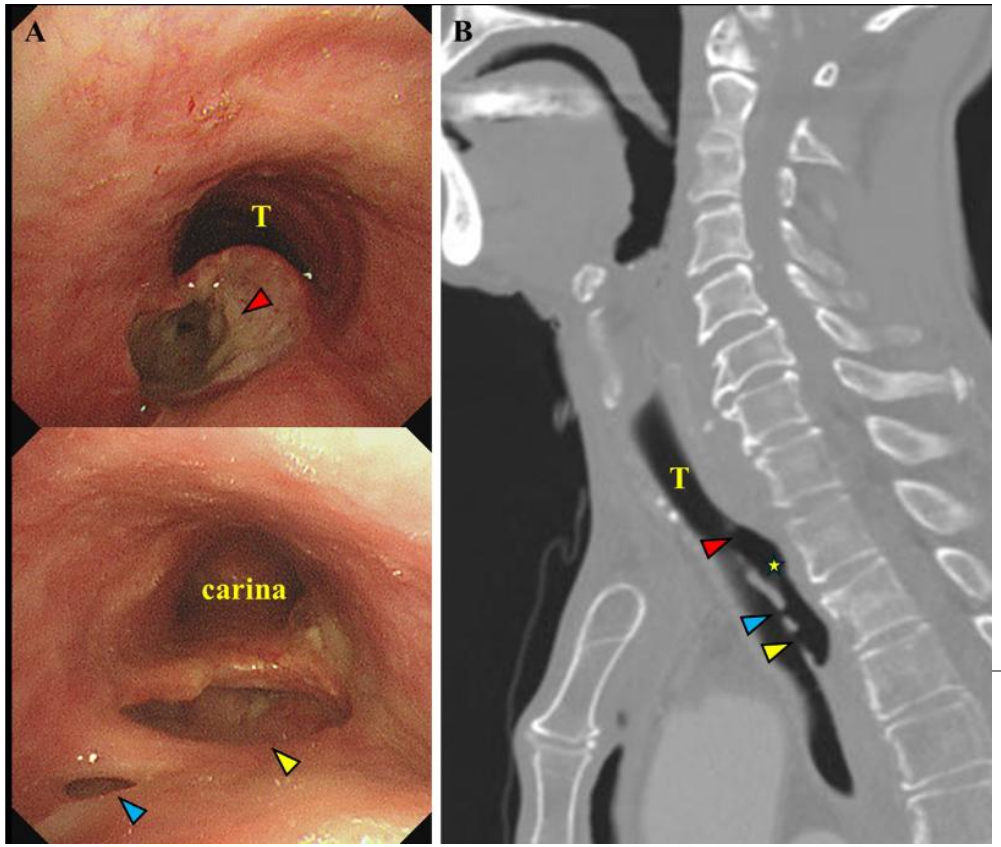

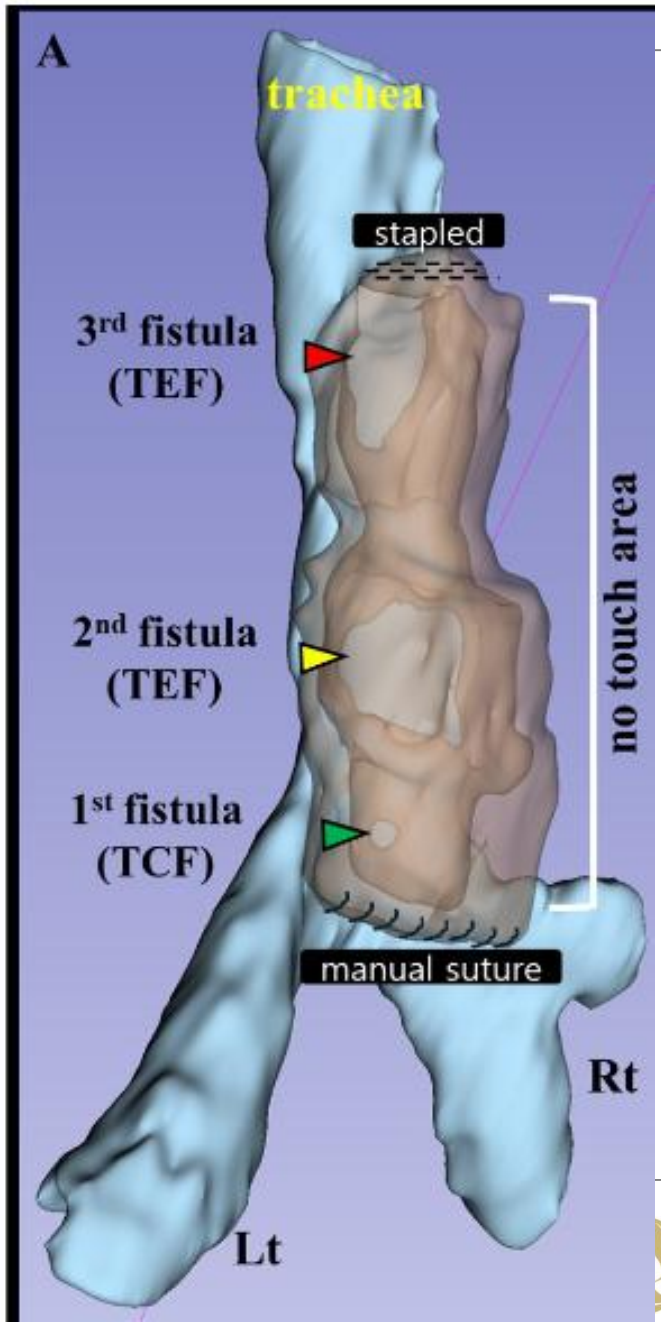

Summary

- Stick to principles
  - Many options – no one ideal strategy
  - Protect lungs from further injury
  - Control sepsis
  - Time for recovery
  - Taking down the conduit is not the worst thing
- Constant re-evaluation of course of action
- Early extubation and avoidance of positive-pressure ventilation
  - VV ECMO?
- Call a friend (or 5)