# Lobar Lung Transplantation for Advanced Lung Disease

**Masaaki Sato, MD, PhD**

**Department of Thoracic Surgery**

**The University of Tokyo Hospital**

2026.06.12. The 50th Annual Toronto Thoracic Surgery Refresher Course



Presented by the Division of Thoracic Surgery,
Department of Surgery, University of Toronto

Surgery
UNIVERSITY OF TORONTO

50th Annual

Toronto Thoracic Surgery Refresher Conference

June 12 - 13, 2026 | Windsor Arms Hotel, 18 St. Thomas Street

# Declaration of Conflict of Interest

# DISCLOSURE OF FINANCIAL SUPPORT

- This program has received financial support from [No External Support].
- This program has received in-kind support from [No External Support]
- Potential for conflict(s) of interest:
  - Masaaki Sato has received [No External Support ]

# FACULTY/PRESENTER DISCLOSURE

- Faculty: Masaaki Sato
- Relationships with financial sponsors:
  - Not Applicable

# 2003-2008 Univ of Toronto Institute of Medical Science(PhD)









# 2008-2011 Clinical Fellow (general thoracic, cardiac, lung Tx)





# The number of lung Transplantation in Japan

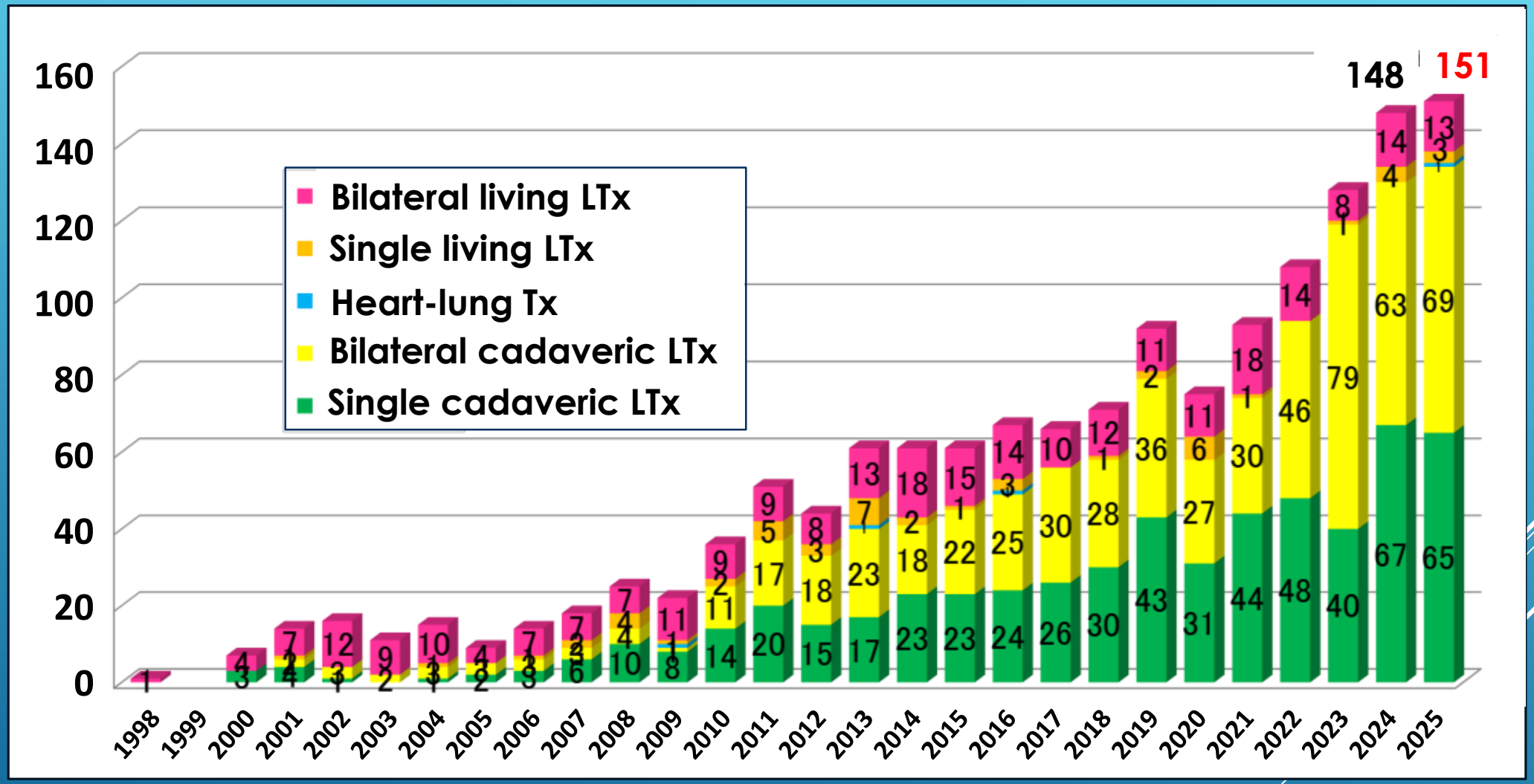

## Kyoto University (2011-2015)

## The University of Tokyo (2015-)







Prof. Hiroshi Date






Prof. Jun Nakajima

# The number of lung Transplantation in UTokyo

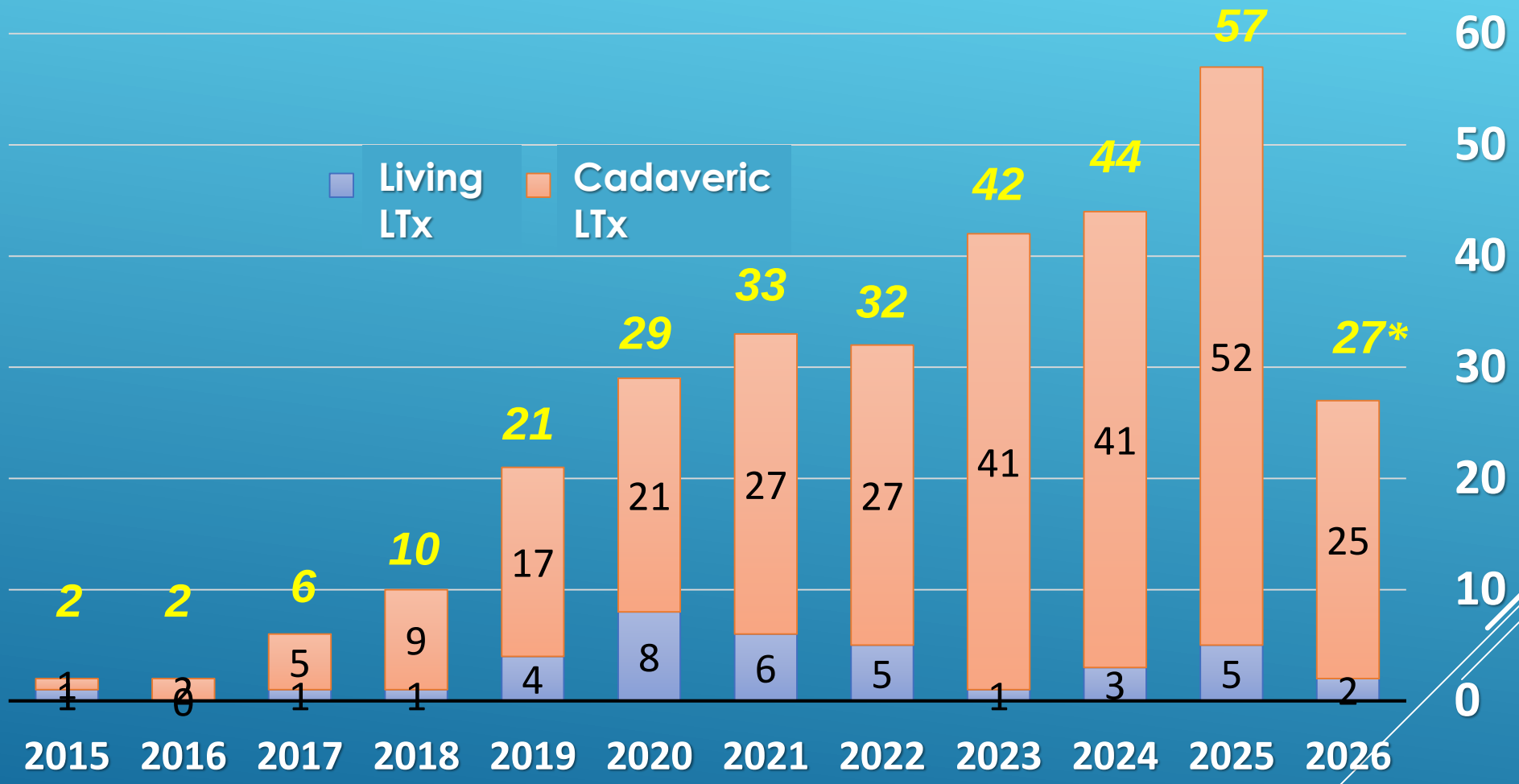


*As of June 4th, 2026

# Lobar Lung Transplantation for Advanced Lung Disease

- ✓Living-donor lobar lung transplantation in Japan
- ✓Application of lobar lung transplant to cadaveric lung transplantation
- ✓Application of lobar lung transplant techniques to auto-transplantation

# First living-related lobar lung transplant in 1990 in Southern California

## A 12-year CF patient received a right lower lobe graft donated by the mother

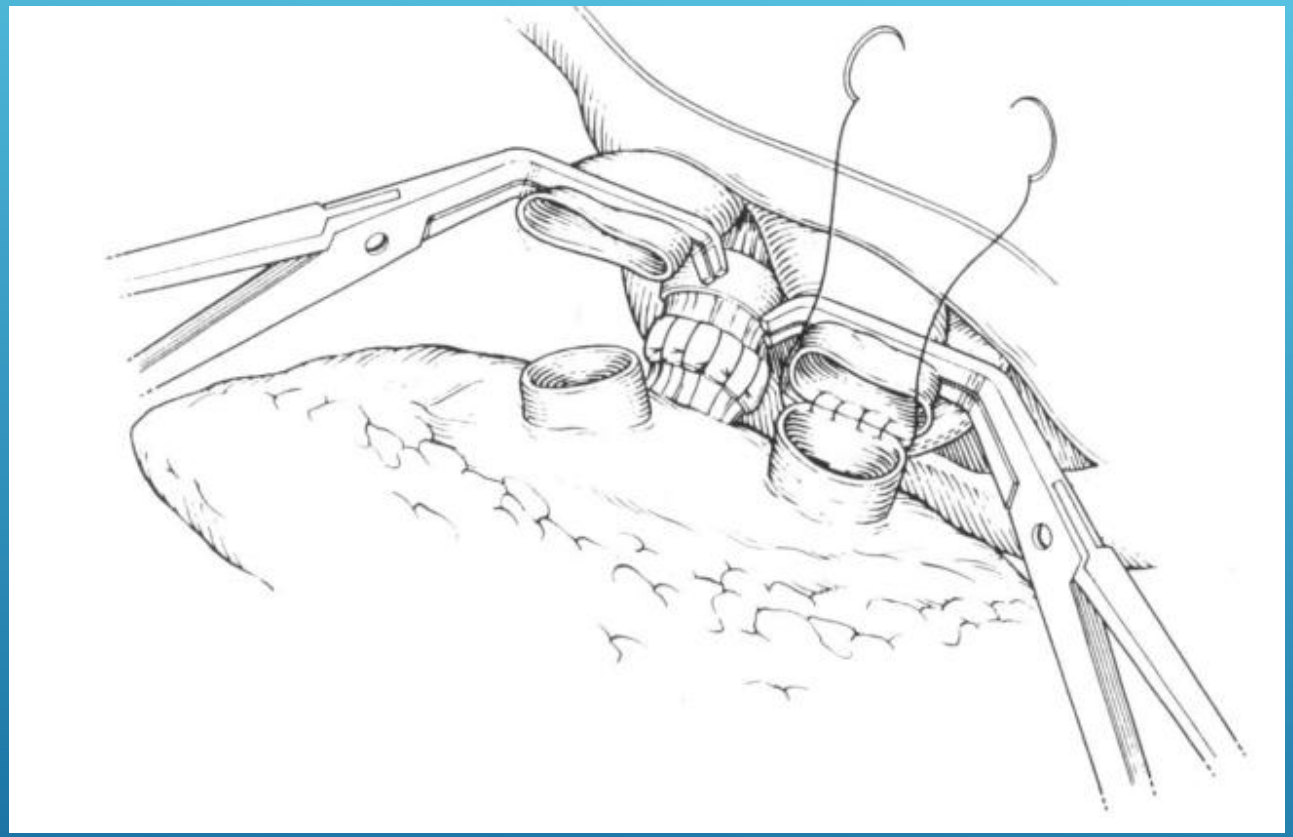

Starnes VA, Barr ML, Cohen RG. Lobar transplantation. Indications, technique, and outcome. J Thorac Cardiovasc Surg. 1994;108(3):403-10.

# First successful clinical lung transplantation in Japan: living bilateral lung transplant in Okayama by Date H and colleagues

- A ventilator-dependent 24-year-old woman with primary ciliary dyskinesia/bronchiectasis received bilateral living-donor lung transplantation
- Donors were her sister and mother
- The patient is still alive in 2026



Date H, Yamashita M, Nagahiro I, Aoe M, Andou A, Shimizu N. Living-donor lobar lung transplantation for primary ciliary dyskinesia. Ann Thorac Surg. 2001;71(6):2008-9.
Date H. JMA journal. 2025;7(2): 2025.

# Lung Transplantation in Japan

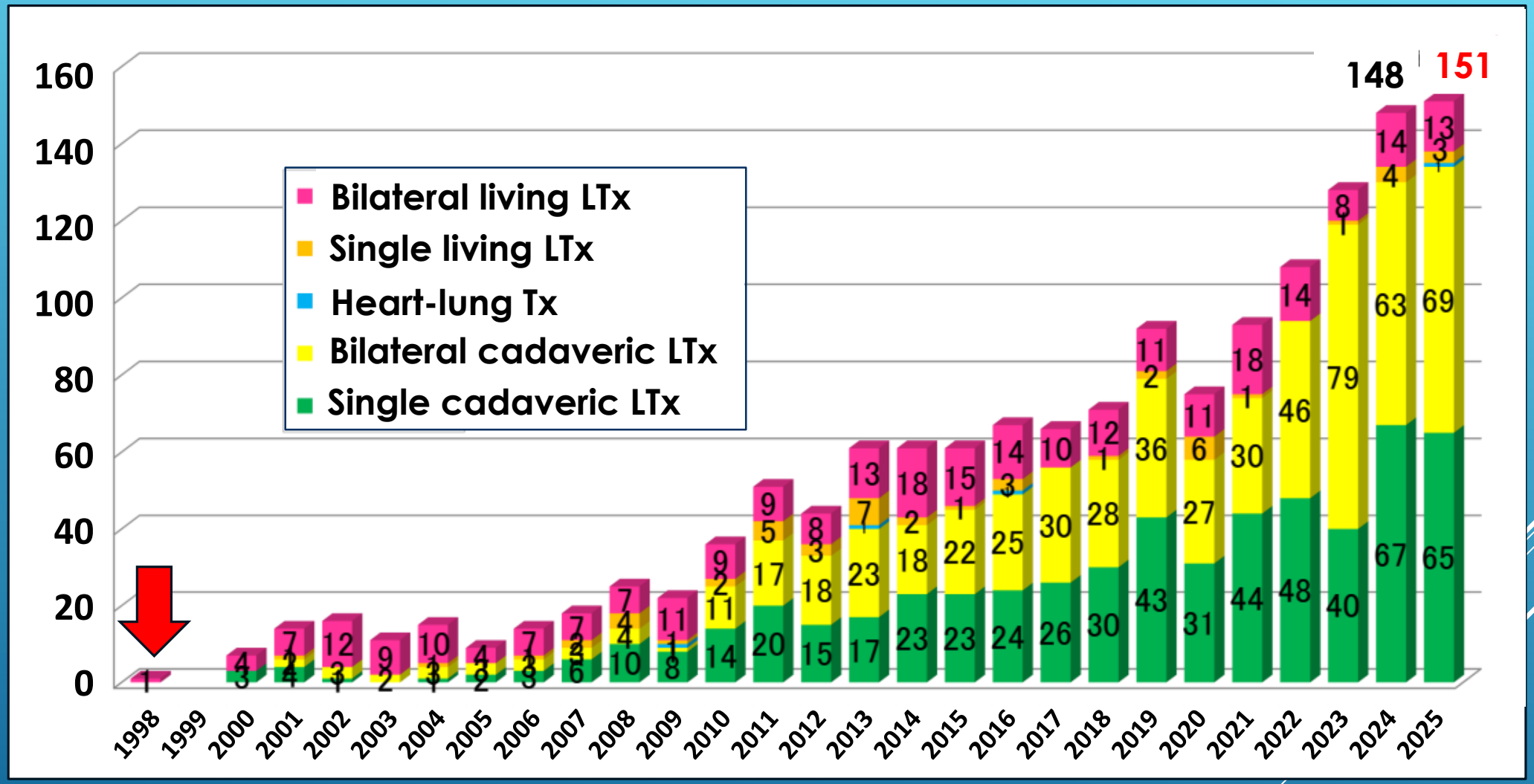

# Standard living-donor lobar lung transplantation

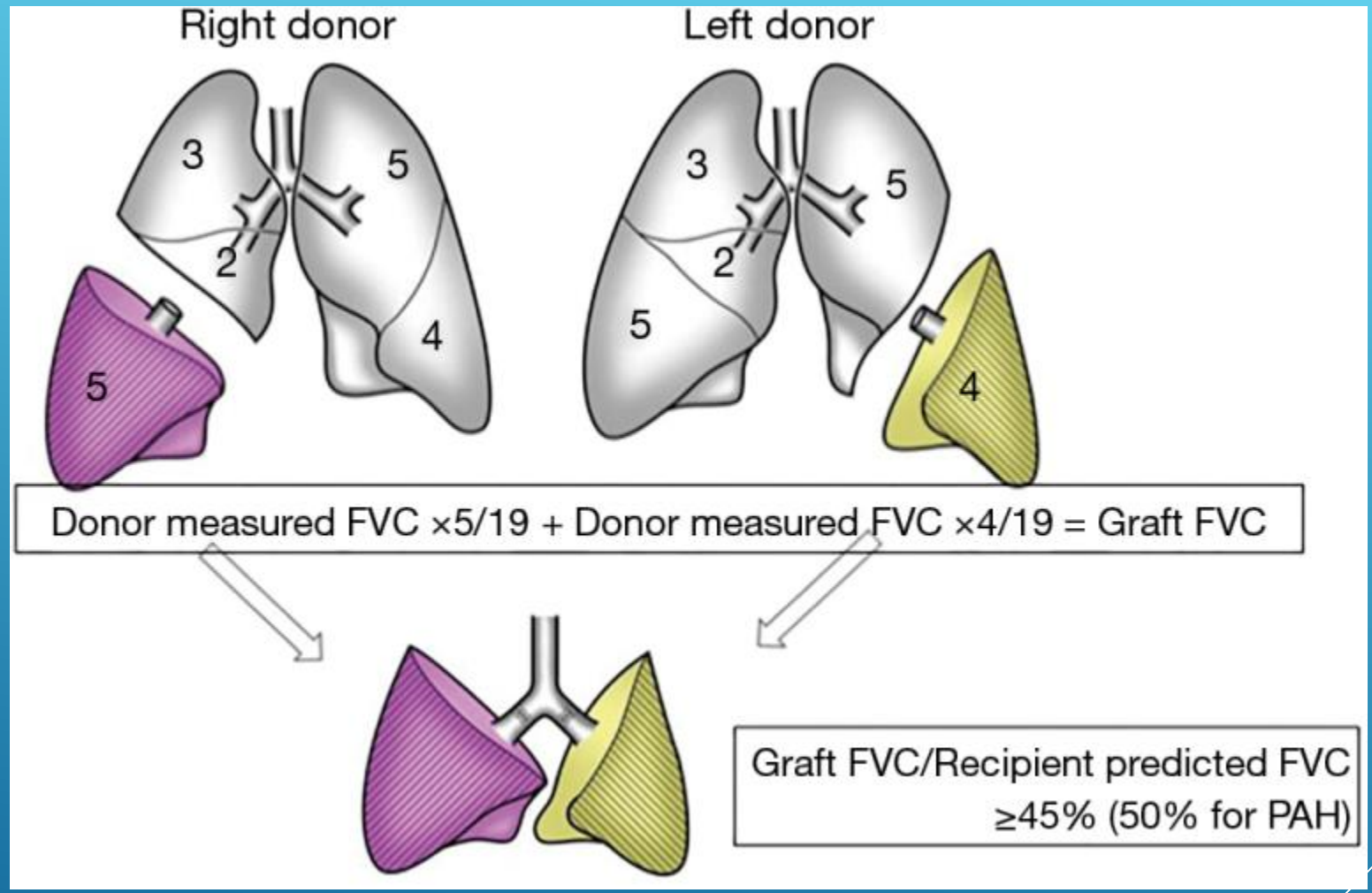


Nakajima D, Date H. Living-donor lobar lung transplantation. J Thorac Dis 2021;13(11):6594-6601

# Long-term outcomes of living-donor lobar lung transplantation (@Kyoto U)

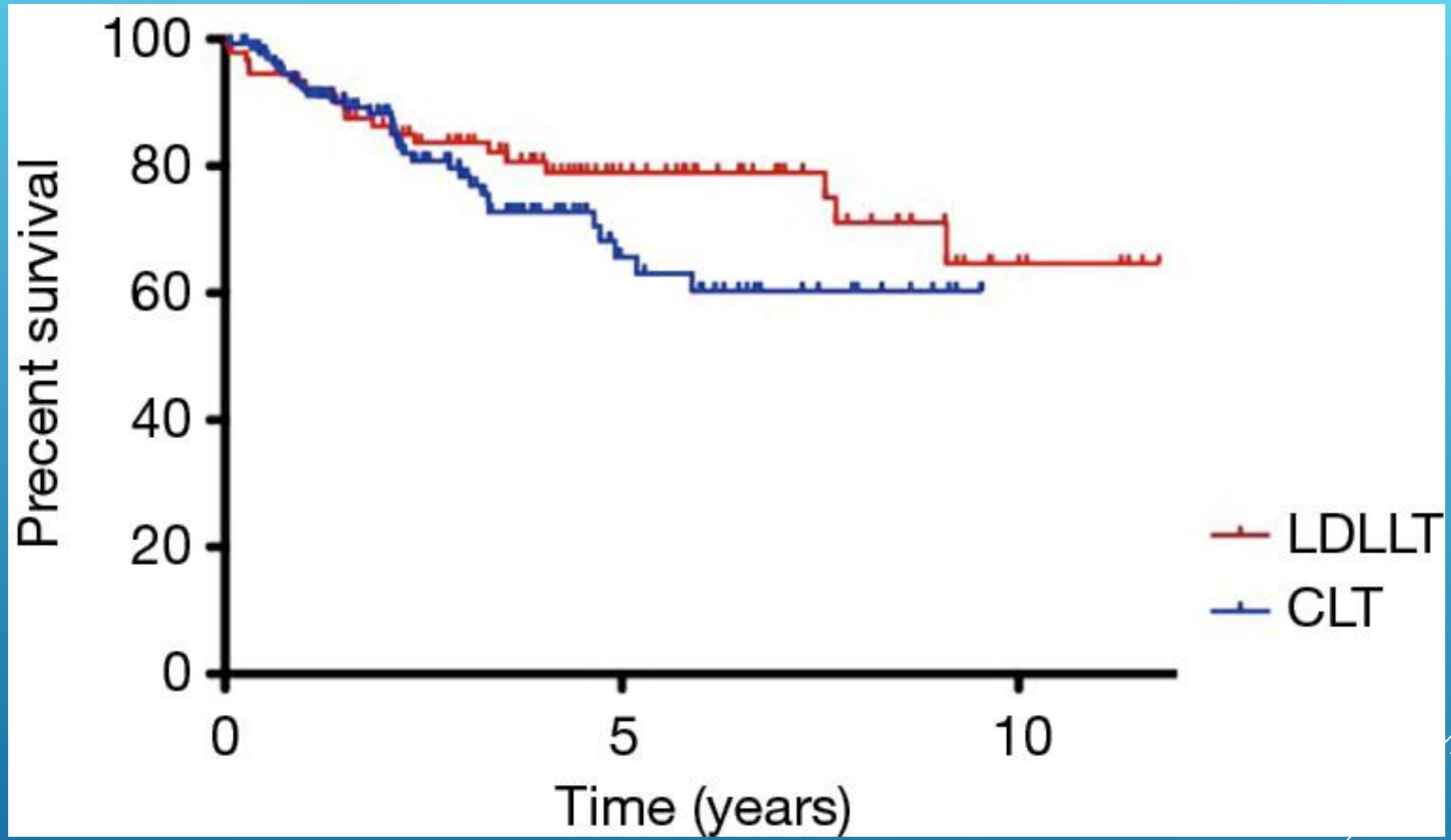


Nakajima D, Date H. Living-donor lobar lung transplantation. J Thorac Dis 2021;13(11):6594-6601

# Living lung transplantation in Japan has evolved in many ways

## Right-to-left inverted lobar Tx: overcoming undersized grafts.

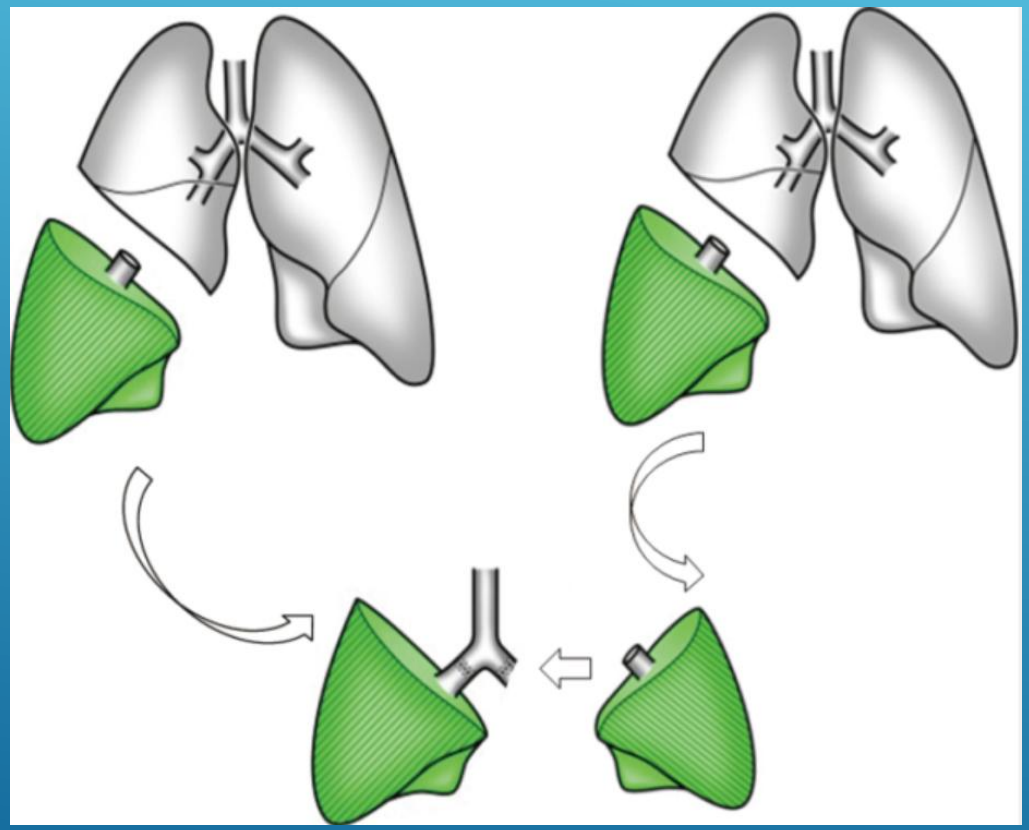

Date H. J Thorac Dis 2017

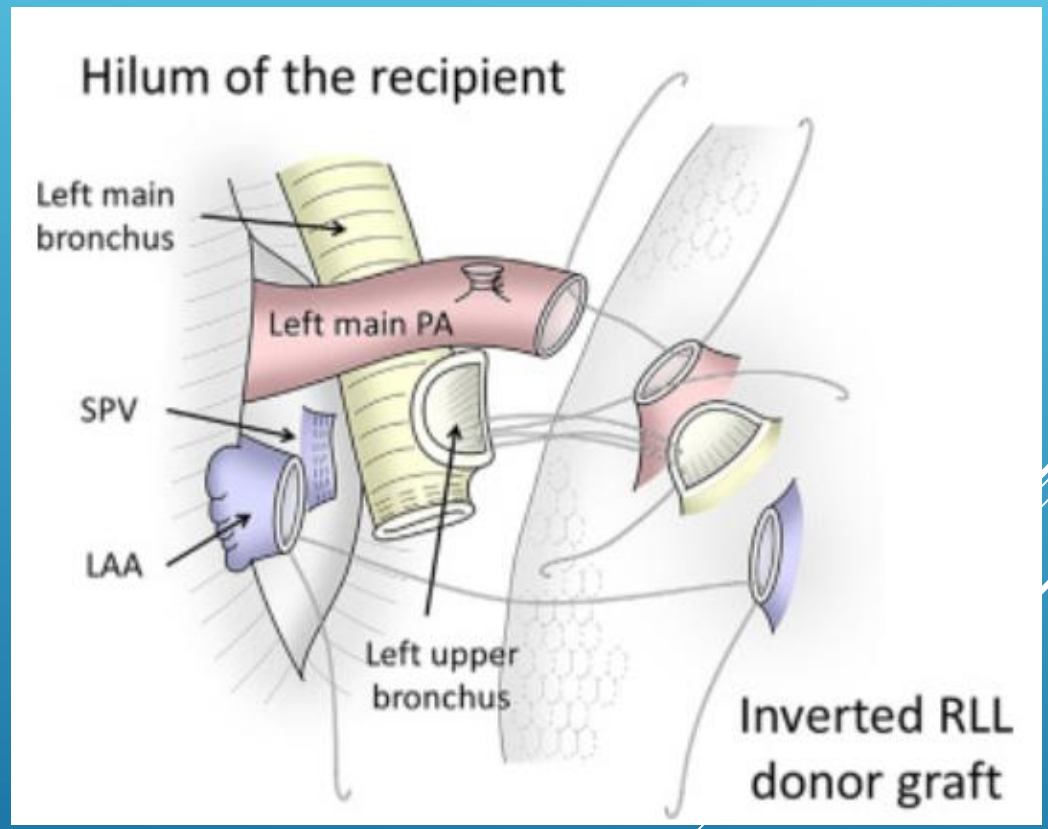


Chen F, et al. Am J Transplant 2015

# Living transplant evolved in Japan in a unique way….

**Native upper-lobe sparing lobar Tx**: overcoming undersized grafts.
Also probably improve respiration mechanics

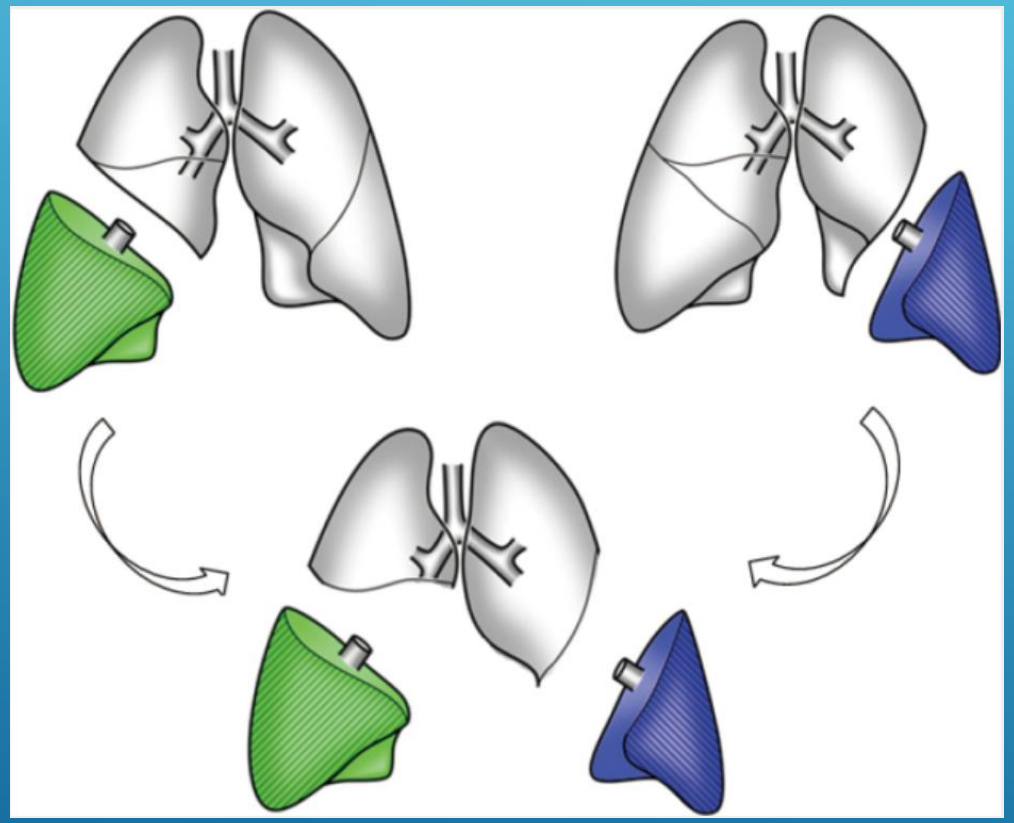

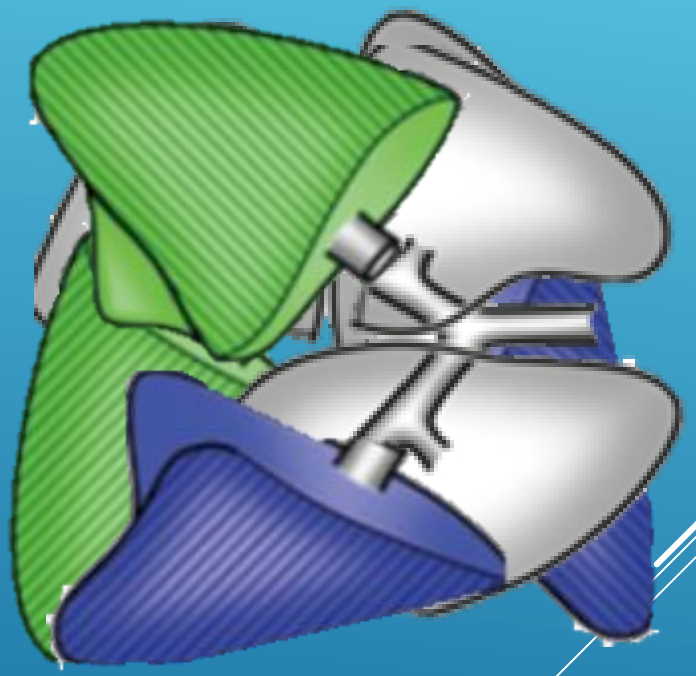

Date H. Living-related lung transplantation. J Thorac Dis 2017;9(9):3362-3371.

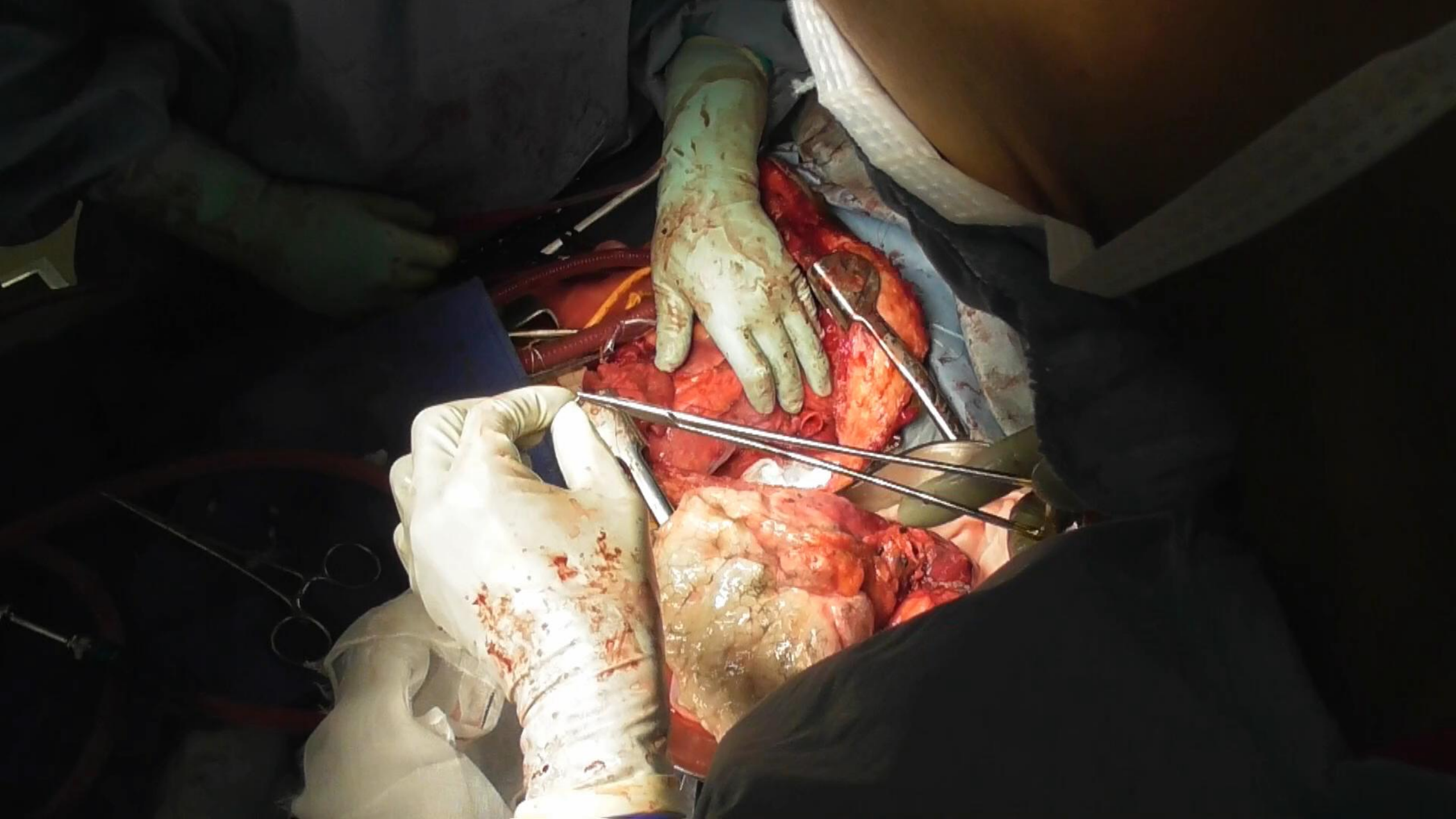

# A case of anomaly in right donor PV branching

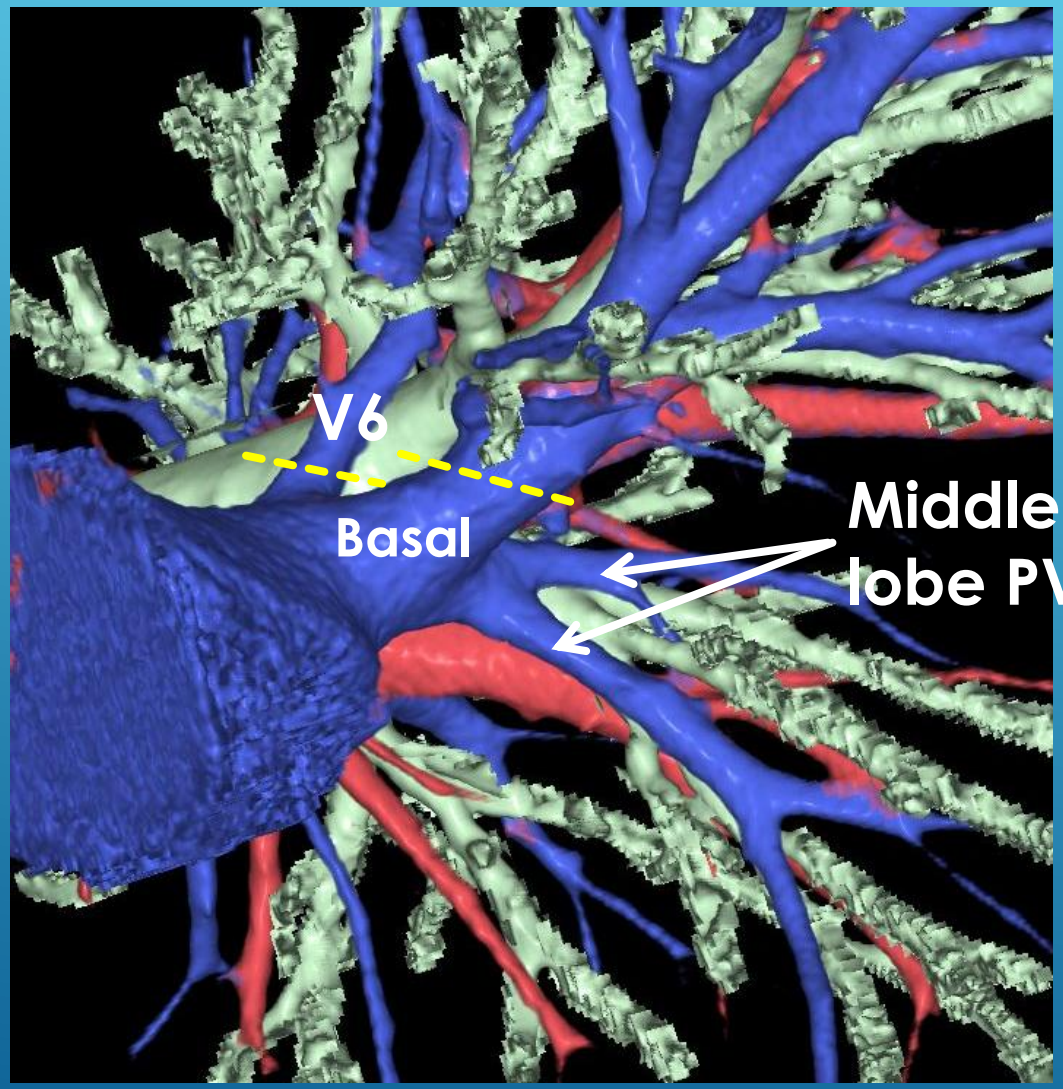


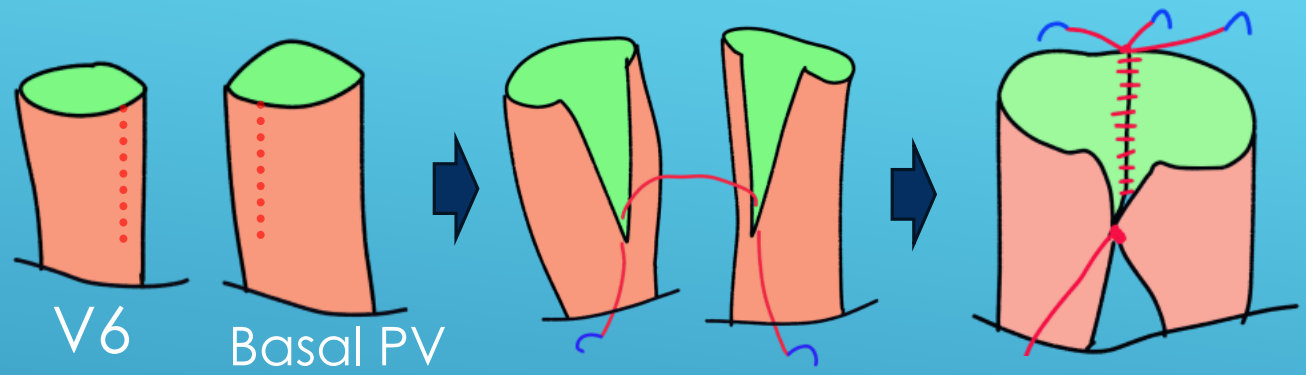


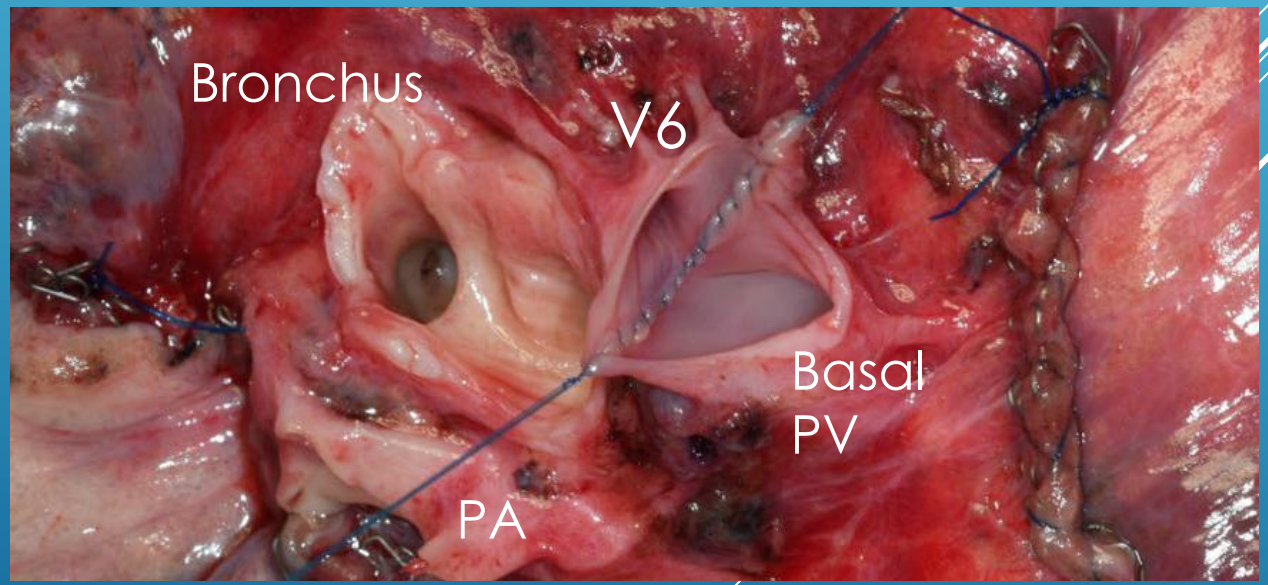

# Lobar Lung Transplantation for Advanced Lung Disease

- ✓Living-donor lobar lung transplantation in Japan
- ✓Application of lobar lung transplant to cadaveric lung transplantation
- ✓Application of lobar lung transplant techniques to auto-transplantation

# Cadaveric lobar lung transplantation

AATS consensus document in 2026

Statement 3.1. Lobar lung transplantation can be a viable option when donor-recipient size matching is appropriately assessed, and the surgical procedure is technically well-executed. (Class IIa, Level B-NR)

Chang S/Laurence C/Cypel M/Keshavjee S/Sato M/Hoetzenecker K. The American Association for Thoracic Surgery (AATS) 2026 Expert Consensus Document: Guidelines for donor/recipient size-matching in lung transplantation. J Thorac Cardiovasc Surg (in press)

# Cadaveric lobar lung transplantation can be used…

- To reduce/adjust graft volume

and/or

- To remove an unusable part of the graft

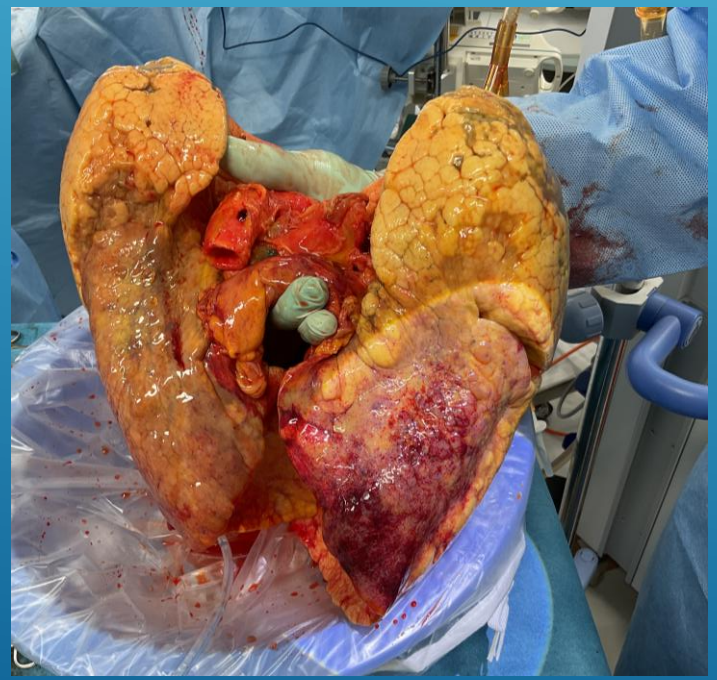



# Calculation of graft volume in lobar lung transplantation

Statement 3.3. Size matching in lobar lung transplantation should follow the same principles as whole lung transplantation, primarily based on pTLC. (Class IIa, B-NR)

Statement 3.4. In lobar lung transplantation, graft size should be calculated based on the number of lobar segments to be transplanted. (Class IIa, C-LD)

Donor pTLC: 3.5 L. Graft: the left whole lung + the right lower lobe.
Estimated graft volume would be:
3.5 L × [(18 – 5 segments on the right side)/18] = 2.53 L.

Chang S/Laurence C/Cypel M/Keshavjee S/Sato M/Hoetzenecker K. The American Association for Thoracic Surgery (AATS) 2026 Expert Consensus Document: Guidelines for donor/recipient size-matching in lung transplantation. J Thorac Cardiovasc Surg (in press)

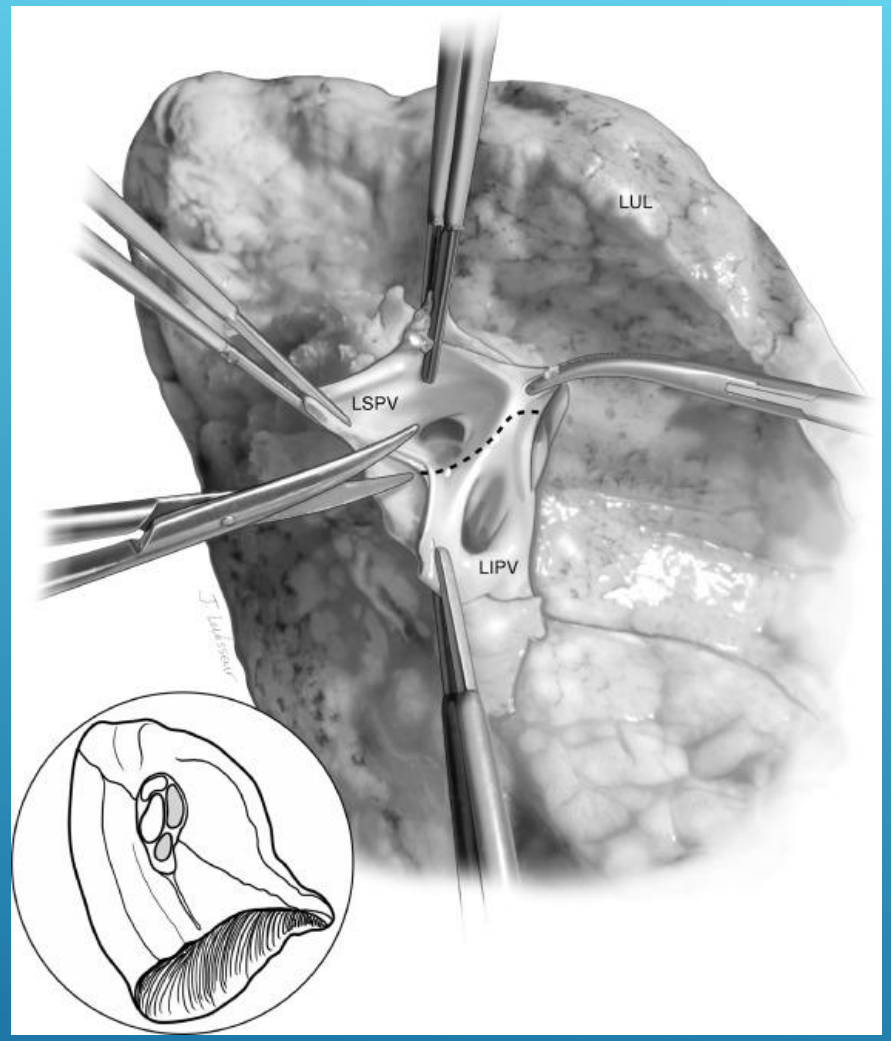


## Technical difference between cadaveric lobar vs. living lobar LTx

## Use of the whole or part of LA cuff

## Easier and much less concerning in stenosis/obstruction

Donahoe L, Cypel M. Lobar Lung Transplantation Operative Techniques in Thoracic and Cardiovascular Surgery, 2021; 26, 658-668

- Donor: 53 y.o. male,  178 cm, 97 kg
- 3 years ago: Bentall + CABG + total arch replacement  for acute aortic dissection (Stanford A)
- CPA (s/o coronary spasm) →hypoxic
- MRSA pneumonia

  (mainly bilateral lower lobes)

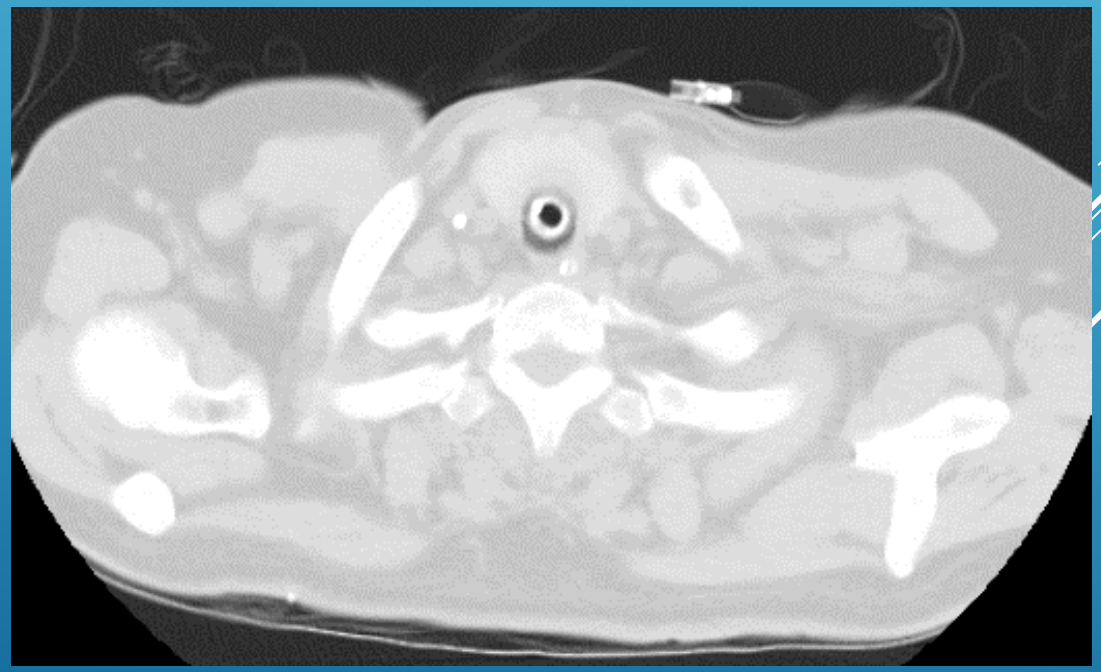

# A 14 y.o. girl with cystic fibrosis



- 133 cm, 25 kg
- Long hospitalization at a local hospital due to recurrent MRSA pneumonia
- Listed only a few months ago; no option of living Tx
- Bilateral lower lobes were totally unusable
- Right upper + middle lobes and left upper lobe were implanted

**Recipient pTLC: 3.11L**
**Donor pTLC = 5.96L → Graft pTLC = 5.96 x (3+2+4)/18 = 2.98L (96%!)**



# Excellent recovery after lobar transplantation

Before LTx

One month after LTx







# Lobar Lung Transplantation for Advanced Lung Disease

- ✓Living-donor lobar lung transplantation in Japan
- ✓Application of lobar lung transplant to cadaveric lung transplantation
- ✓**Application of lobar lung transplant techniques to auto-transplantation**

# 64 y.o. male cT2aN1M0 Squamous cell carcinoma

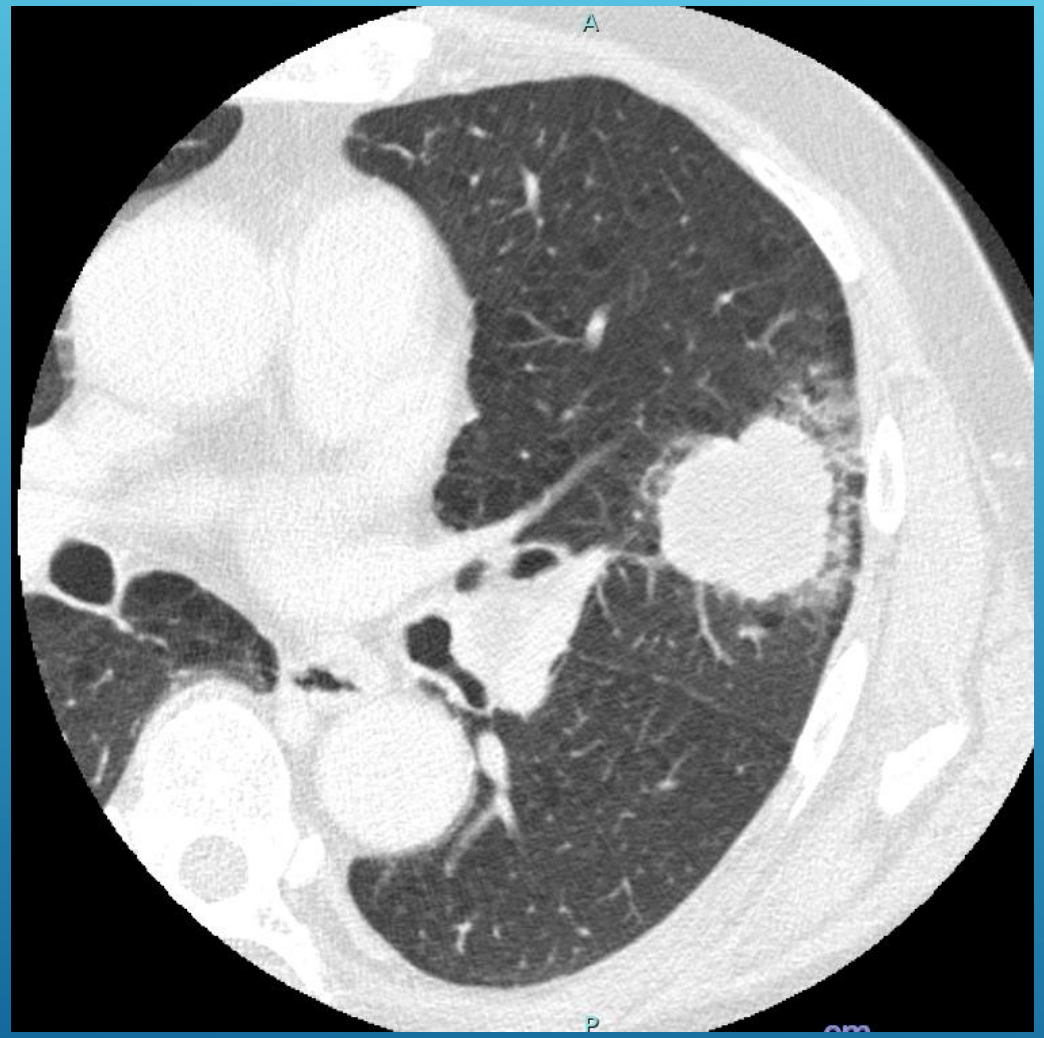


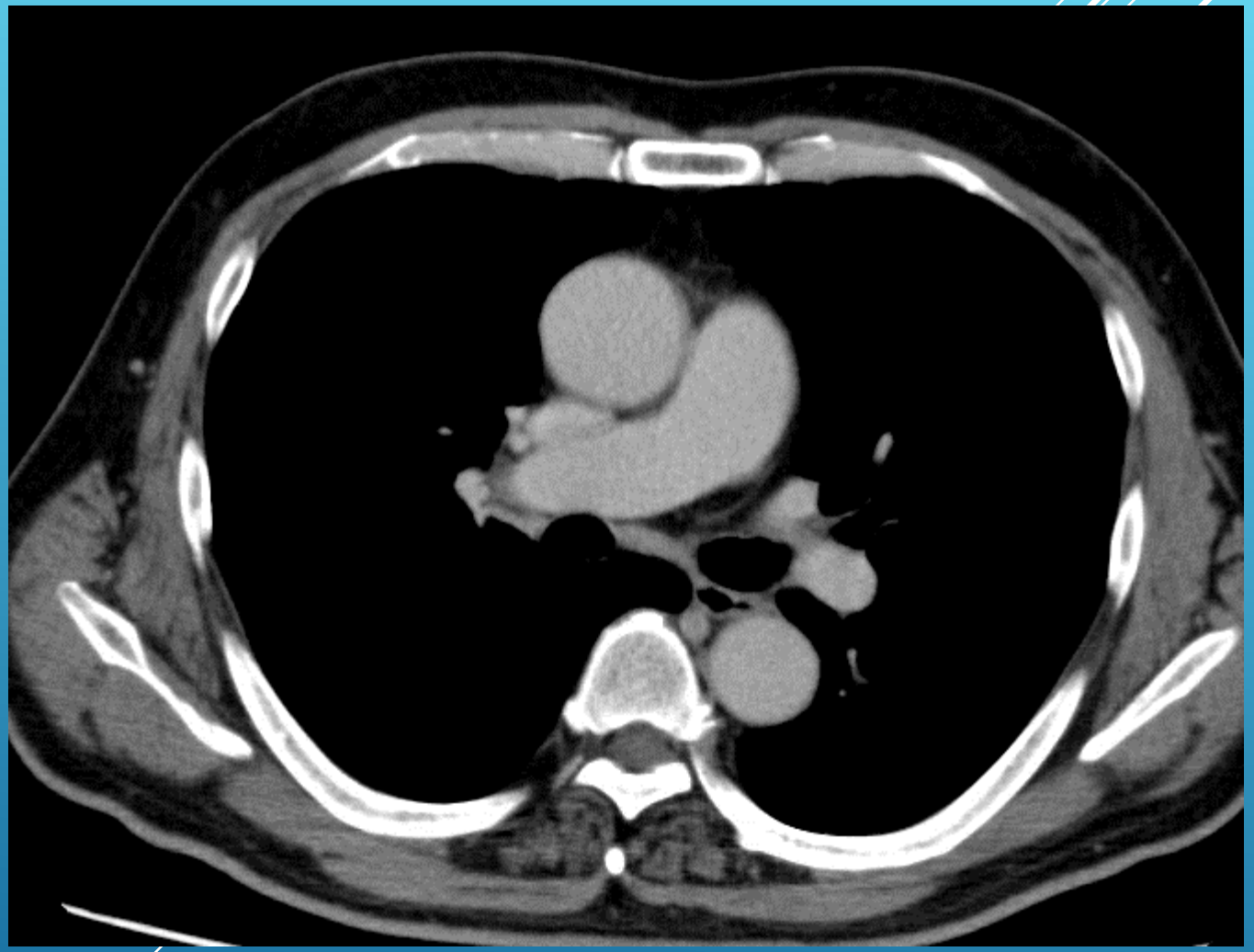

# Pneumonectomy? Bronchovascular reconstruction?

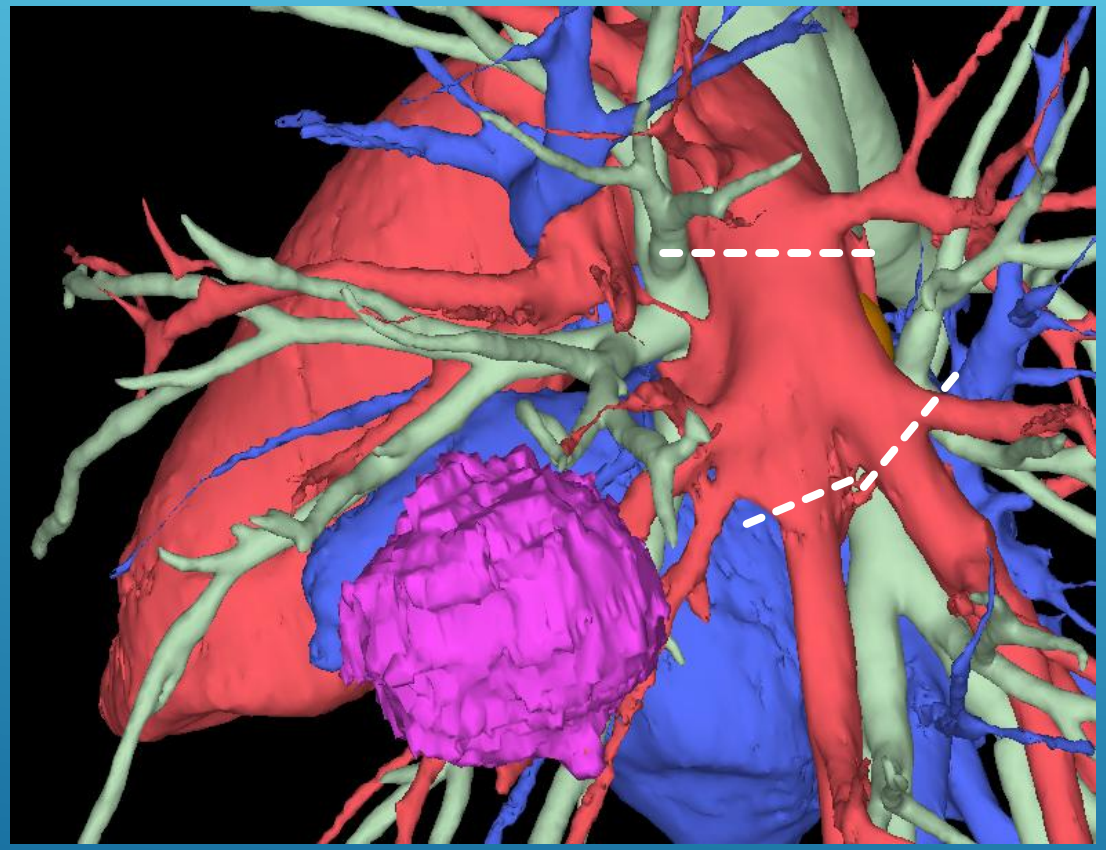

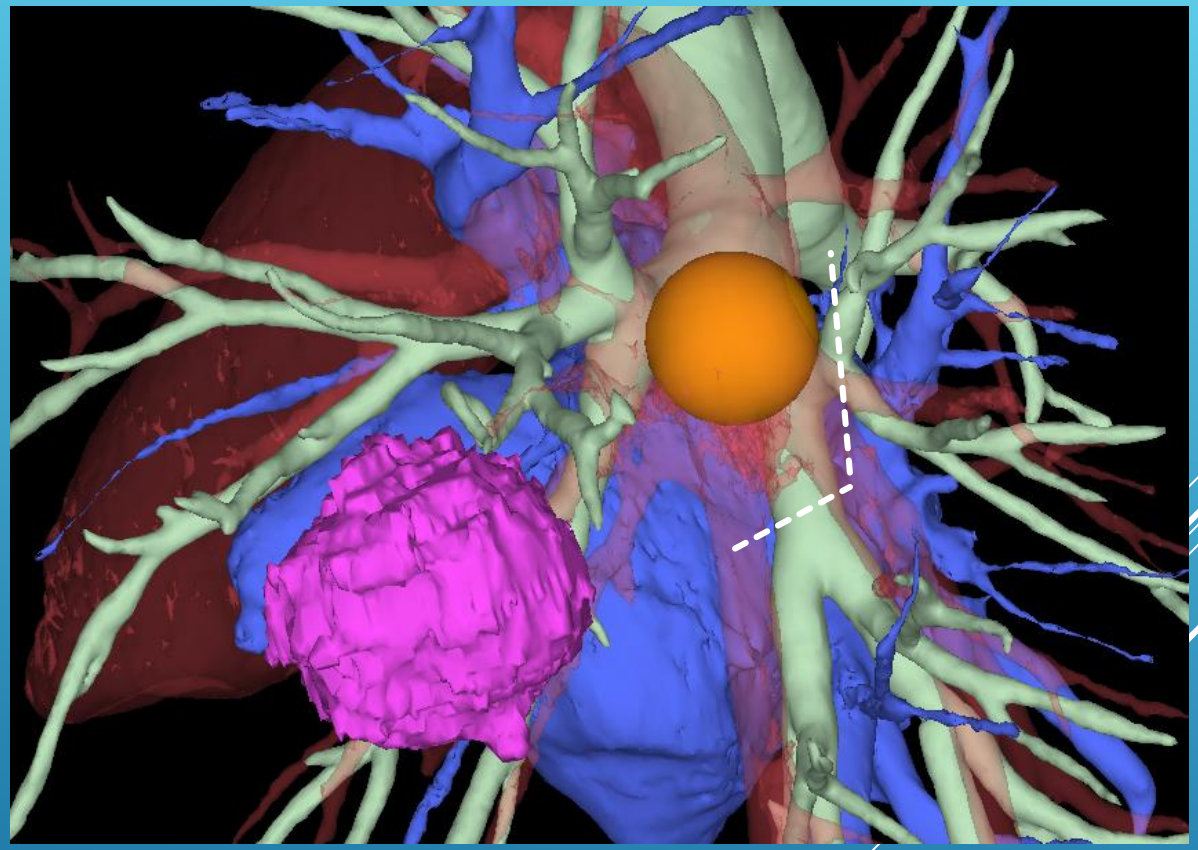

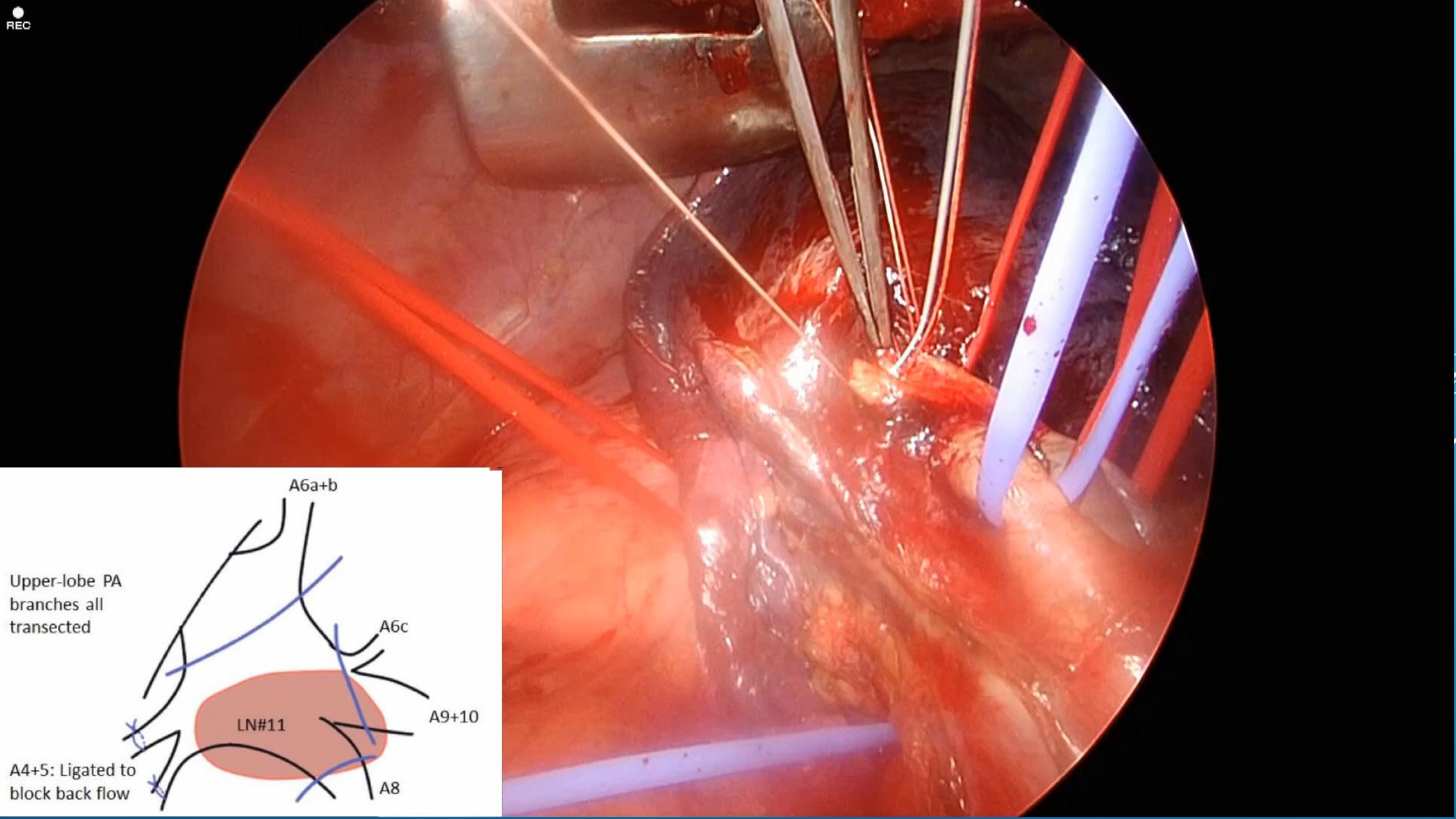
REC
A6a+b
Upper-lobe PA branches all transected
A6c
A9+10
LN#11
A4+5: Ligated to block back flow
A8

# 1 week after

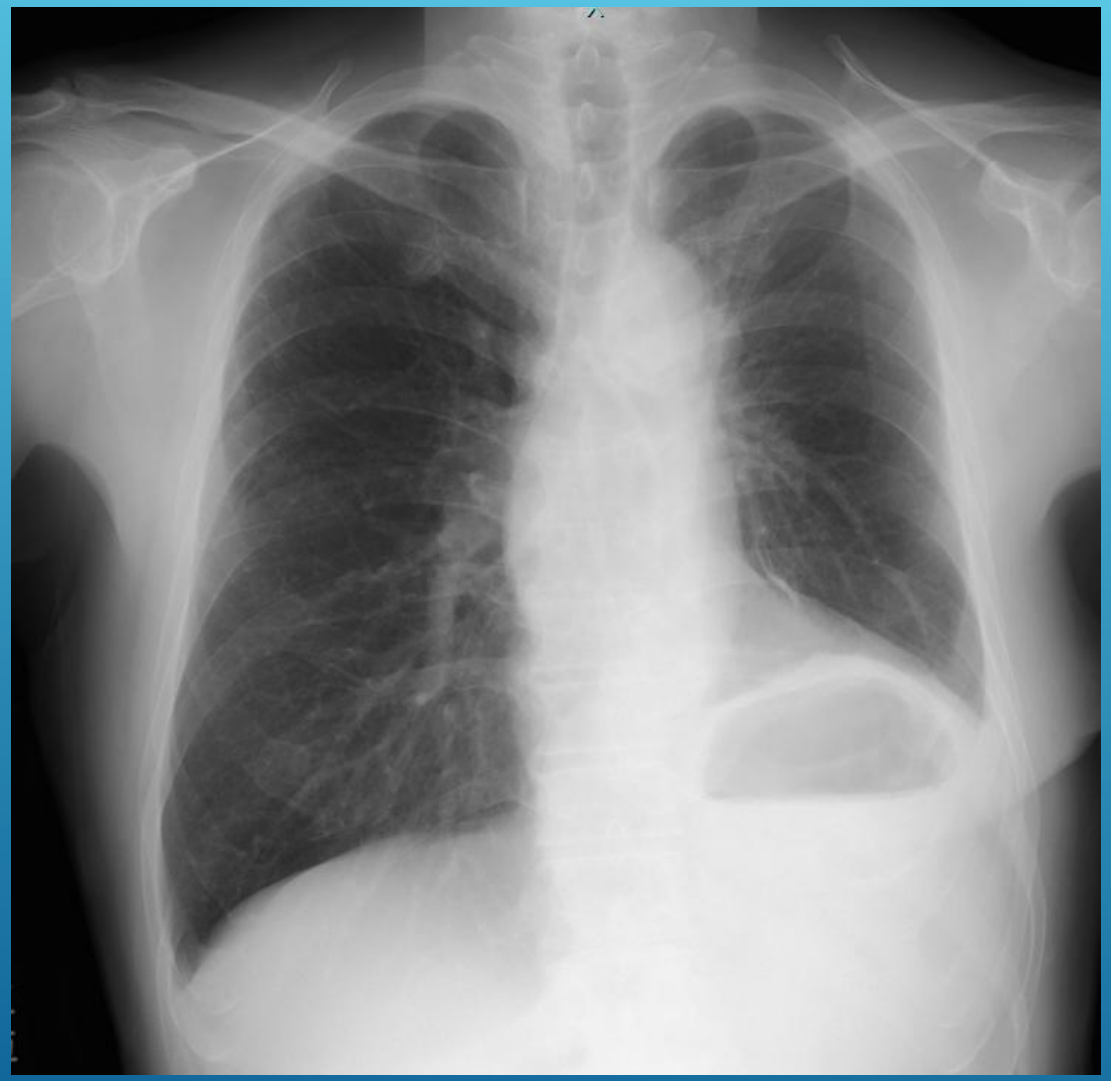

# 2 weeks after

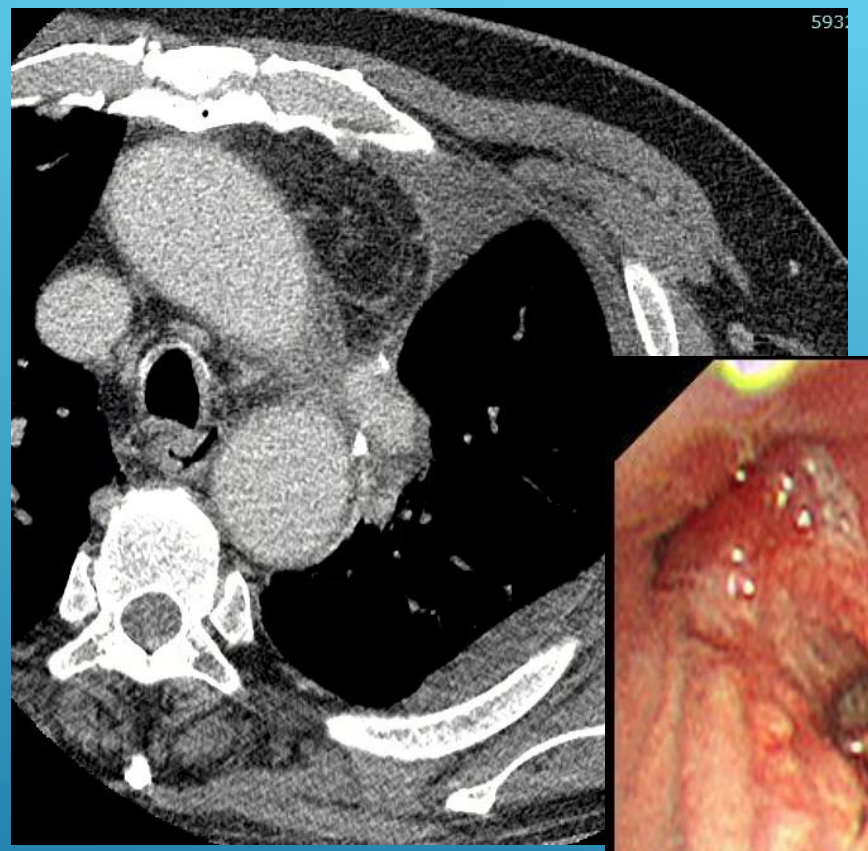

# 2 months after

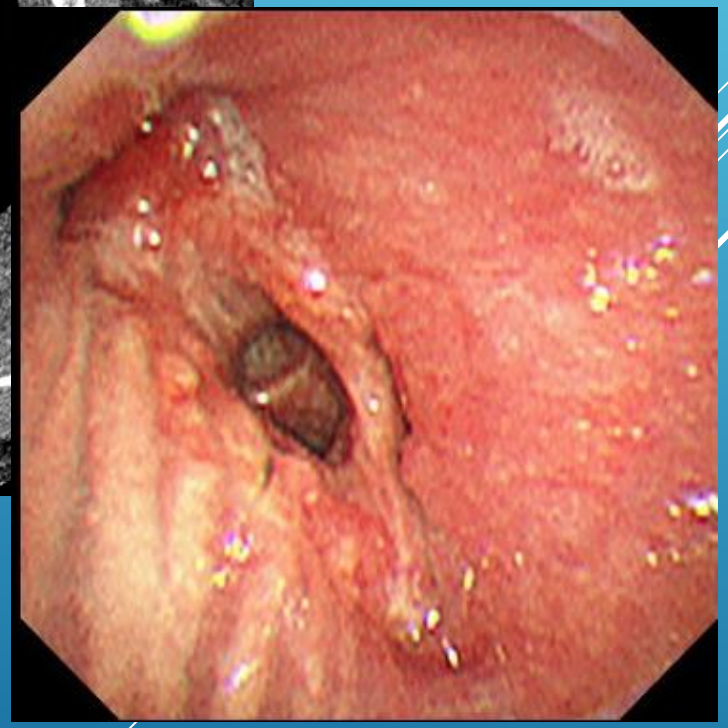

# Lobar Lung Transplantation for Advanced Lung Disease

- ✓ Living-donor lung transplantation has evolved in Japan with multiple unique technical aspects
- ✓ Lobar lung transplantation is useful in cadaveric lung transplantation, especially to adjust graft volume and/or salvage marginal grafts
- ✓ The techniques of (living) lobar lung transplantation is very useful in other general thoracic surgery (e.g., broncho-vascular reconstruction, auto-transplant)

# *Thank you for your attention!*

